

Imaging Pregnant Patients in Different Acute Medical Non-Traumatic Emergencies. A Literature Review.

¹Behar Tocilla

<https://doi.org/10.32391/ajtes.v4i1.85>

Abstract

Radiologists should suggest what kind of imaging is best suited for a pregnant patient presenting with an acute condition. The type of imaging study is planned in close consultation with the clinical team. Ultrasonography (US) should always be the initial modality for evaluation of a pregnant patient, especially in abdominal emergencies. In other conditions like suspected pulmonary embolism or neurological emergencies ultrasound doesn't help, so using other diagnostic modalities like CT and MRI will be necessary. A recurring debate in many radiology practices is the concern of radiologists about performing an examination that exposes a fetus to radiation. This literature review aims to identify an optimal imaging strategy for the accurate detection of different acute medical non-traumatic emergencies in pregnant patients.

Keywords: pregnancy, imaging, non-traumatic emergencies, US, MRI, CT

***Corresponding Author:** Behar Tocilla

✉ **E-mail:** behartocilla@yahoo.it

¹Radiology Department, American Hospital, Tirana, Albania

Full Text

Introduction

Radiologists should suggest what kind of imaging is best suited for a pregnant patient presenting with an acute condition. The type of imaging study is planned in close consultation with the clinical team. Ultrasonography (US) should always be the initial modality for evaluation of a pregnant patient, especially in abdominal emergencies. In other conditions like suspected pulmonary embolism or neurological emergencies ultrasound doesn't help, so using other diagnostic modalities like CT and MRI will be necessary.

A recurring debate in many radiology practices is the concern of radiologists about performing an examination that exposes a fetus to radiation. A recent literature review demonstrated that in general, there is a lower than expected awareness of radiation risks associated with imaging pregnant women both among radiologists and among clinicians.

Radiation Effects

The effects of radiation exposure have been studied extensively and the risks of radiation can be categorized as stochastic and nonstochastic effects.

Stochastic Effects

Stochastic effects are the result of cellular damage, likely at the DNA level, causing cancer or other germ cell mutation. Stochastic effects have no threshold value and are theorized to occur with exposure to any amount of ionizing radiation. The severity of radiation-induced stochastic effects is independent of the radiation dose. Historically, the radiation dose estimated for stochastic effects, as based on probability, was established at 50 mGy (5 rad) ¹⁻⁴

American College of Radiology (ACR) produced practice guidelines for imaging pregnant patients and provided an approximation of fetal risk at various gestational ages with differing radiation exposure (*Table 1*) ^{5,6}

Gestational Age (weeks)	Potential Effects by Radiation Exposure		
	<50 mGy	50-100 mGy	>100 mGy
0-2	None	None	None
3-4	None	Probably none	Possible spontaneous abortion
5-10	None	Uncertain	Possible malformations
1-17	None	Uncertain	Possible deficits in IQ or mental retardation
8-27	None	None	Q deficits not detectable at diagnostic doses
>27	None	None	None applicable to diagnostic medicine

Table 1: Potential Radiation Effects on the Fetus by Gestational Age and Radiation Exposure

As shown in Table 1, the ACR suggested that theoretical risks are not likely at doses less than 100 mGy (10 rad).⁷

Nonstochastic Effects

Nonstochastic effects (threshold effects) are caused by exposure to radiation at high doses. These effects are predictable and involve multicellular injury, which can include chromosome aberrations. Threshold effects follow a linear progression, with risk increasing with increasing dose^{2,4}).

Historically, the threshold dose has been estimated to be 150 mGy (15 rad) (8). At this dose, it is recommended for the pregnancy to be terminated.

Table 2 shows the average values for fetal radiation dose after a single acquisition for various CT examinations in pregnant patients. Given the low radiation exposure, fear of fetal radiation exposure should not delay imaging studies that may help identify underlying maternal pathologic conditions.^{2,4,5,9}

<i>Examination</i>	<i>Estimated Fetal Dose (mGy)</i>	<i>CT Estimated Fetal Dose</i>	
Radiography		Head	0
Cervical spine (AP, lateral)	<0.001	Chest (routine)	0.2
Extremities	<0.001	Chest (pulmonary embolism protocol)	0.2
Chest (PA, lateral)	0.002	Abdomen	4
Thoracic spine	0.003	Abdomen and pelvis	25
Abdomen (AP) (21-cm patient thickness)	1	CT angiography of The aorta	34
Abdomen (AP) (33-cm patient thickness)	3	CT angiography of the coronary arteries	0.1
Lumbar spine (AP, lateral)	1		

Table 2: Estimated Fetal Radiation Dose from Conventional Radiographic and CT Examinations

Imaging Pregnant Patients with Suspected Pulmonary Embolism

A diagnosis of pulmonary embolism in pregnancy has important implications, including the need for prolonged anticoagulation therapy, delivery planning, and possible prophylaxis during future pregnancies, as well as concern about future oral contraceptive use and estrogen therapy.^{10-13,16}

The clinical pathway for evaluating pregnant patients with suspected pulmonary embolism has been a topic

of debate.¹³⁻¹⁵ In the absence of standard guidelines, there is a need to familiarize radiologists with the relative advances and limitations of various tests used.

This category of patients is a real challenge for the clinician because classic clinical symptoms are often absent and physiologic changes during pregnancy can mimic pulmonary embolism eg, leg swelling, pain, dyspnea, tachypnea, tachycardia,

palpitations. Also, the pregnancy itself has increased risk for thrombosis and sometimes has elevated levels of D-dimer.

The clinical awareness in pregnant patients for pulmonary embolism is low. Frequency of diagnosis of venous thromboembolism in (A) nonpregnant and (B) pregnant patients in a meta-

analysis shown in table 3. The frequency of VTE+ diagnosis among 24,833 nonpregnant patients was 12.4% (95% CI = 9.0% to 16.3%, $I^2 = 0\%$), and the frequency of VTE+ diagnosis among the 506 pregnant patients was 4.1% (95% CI = 2.6% to 6.0%, $I^2 = 0\%$).¹⁷

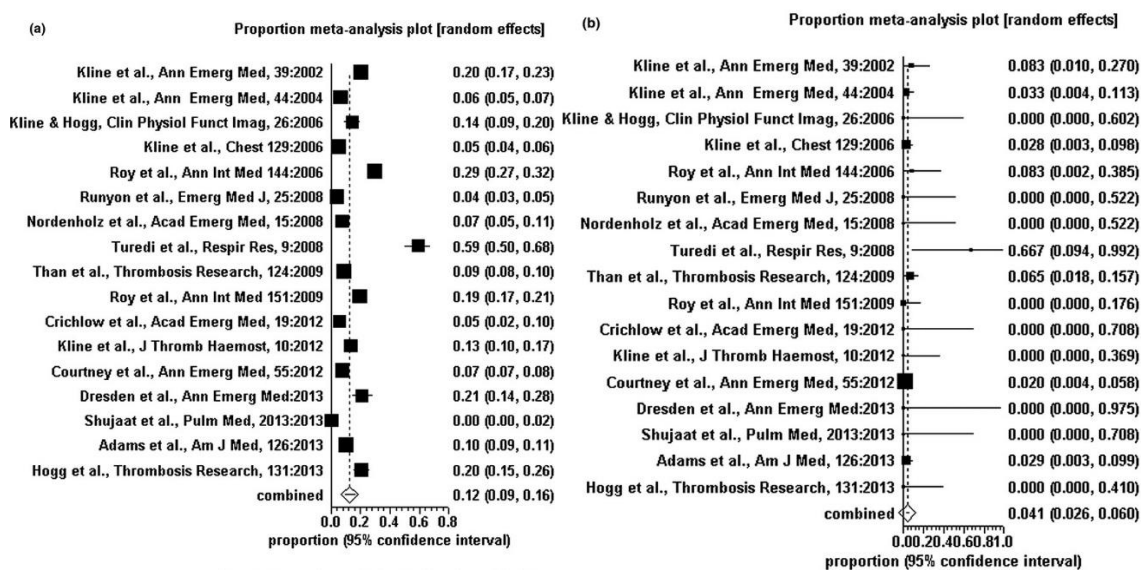


Table 3: Diagnosis of PE in pregnant and nonpregnant patients.

In the ED setting, physicians test for PE in pregnant patients at a low threshold, resulting in a low rate of VTE diagnosis and a RR of VTE that is lower than that for nonpregnant women of

childbearing age who are tested for PE in the ED setting.

A diagnostic algorithm for suspected PE in pregnancy guideline from Society of Thoracic Radiology Clinical Practice is shown in figure 1.¹⁷

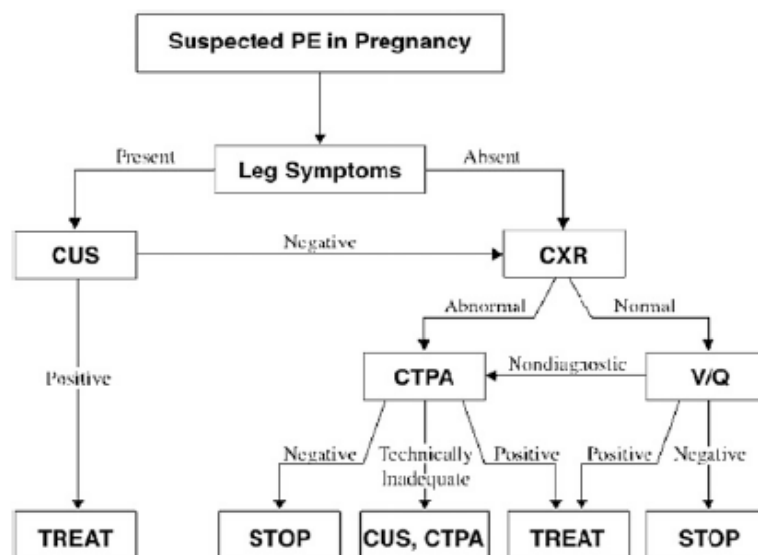


Figure 1: Algorithm for suspected PE.

Recommendations that comes on based on the algorithm:¹⁷

Recommendation 1.

In pregnant women with suspected PE, we suggest that D-dimer not be used to exclude PE (weak recommendation, very-low-quality evidence).

Recommendation 2.

In pregnant women with suspected PE and signs and symptoms of deep venous thrombosis (DVT), is suggested performing bilateral venous compression ultrasound (CUS) of lower extremities, followed by anticoagulation treatment if positive and by further testing if negative (weak recommendation, very-low-quality evidence).

Recommendation 3.

In pregnant women with suspected PE and no signs and symptoms of DVT, is suggested performing studies of the pulmonary vasculature rather than CUS of the lower extremities (weak

recommendation, very-low-quality evidence).

Recommendation 4.

In pregnant women with suspected PE, is recommended a CXR as the first radiation-associated procedure in the imaging work-up (strong recommendation, low-quality evidence).

Recommendation 5.

In pregnant women with suspected PE and a normal CXR, is recommended lung scintigraphy as the next imaging test rather than CTPA (strong recommendation, low-quality evidence).

Recommendation 6.

In pregnant women with suspected PE and a nondiagnostic V/ Q scan, is suggested further diagnostic testing rather than clinical management alone (weak recommendation, low-quality evidence). In patients with a nondiagnostic V/ Q scan in whom a decision is made to further investigate,

is recommended CTPA rather than DSA (strong recommendation, very-low-quality evidence).

Recommendation 7.

In pregnant women with suspected PE and an abnormal CXR, is suggested CTPA as the next imaging test rather than lung scintigraphy (weak recommendation, very-low-quality evidence)

Based on recommendations above, none of them was statistically superior

to others. In making recommendations and considering their strength, the panel placed a higher value on minimizing radiation dose and a lower value on test rapidity, test potential to provide alternate diagnosis, and cost.

What are the risks to mother and fetus when diagnostic studies requiring radiation are performed?

Table 4 shows measured radiation doses to fetus and mother associated with diagnostic tests for suspected PE in pregnancy.¹⁷

Diagnostic Test	Fetal Dose (mGy)	Maternal Dose (Whole Body Effective Dose in mSv)
CXR	0.002	0.1
V/Q	0.32 – 0.74	1–2.5
CTPA	0.03 – 0.66	4–18
DSA	—	7–28

Table 4: Fetal and maternal radiation doses associated with diagnostic tests for pulmonary embolism

Studying the table above we see that the radiation doses for fetus are greater in scintigraphy than in CT.

Based on the availability of scintigraphy which doesn't work 24 h/day, when none of diagnostic modalities was statistically superior to

others and with new CT following protocols radiation doses are maintained under 50 mGy (doses vary from 8-14 mSv and can be calculated automatically from CT in the end of exam) diagnostic algorithm can be simplified like in figure 2.

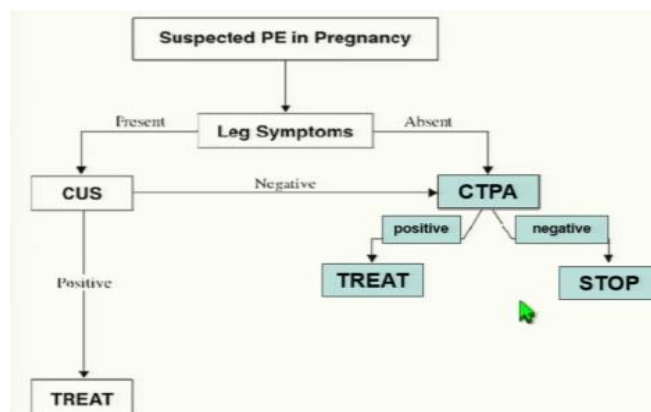


Figure 2: Algorithm for suspected PE in pregnant patients simplified.

It is important to note that there is an estimated 30–630-fold greater breast dose with CT pulmonary angiography (10-70 mGy) than with low-dose perfusion scintigraphy, with breast dose values well above the traditional 3 mGy used in screening mammography and equivalent to exposure from hundreds of chest radiographs (17-20). Which is the most appropriate protocol for CTPA?

During pregnancy there are some hemodynamically changes like increase in blood volume, cardiac output dhe cardiac frequency. All of them produce an increase at about six-fold the “thoracoabdominal pump” in supine position and in full inspiration. This can create a “transient interruption of contrast”, which suggest PE (false positive) (figure 3). It happens until 39 % of patients not following the right protocols.

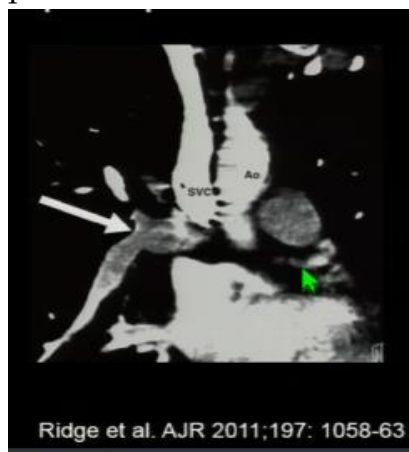


Figure 3: Transient interruption of contrast because of deep Valsalva.

Methods of Reducing the Radiation Dose to the Maternal Breast and Fetus at CT Pulmonary Angiography¹⁷

Thin-layer bismuth breast shield

Lead shielding

Reduction in tube current (70 -80 kVp)

Reduction in tube voltage

Increase in pitch

Increase in detector collimation thickness

Reduction of z-axis

Also because of high cardiac output we should perform high speed of contrast injection (5ml/s), high levels of contrast concentration (350-400 mg/ml).

No Valsalva

Elimination of lateral scout image

Fixed injection timing rather than test run

Elimination of any additional CT sequences

Early scanning but nor flash mode.

Acute abdomen and appendicitis

Clinical diagnosis of the cause of abdominal pain in a pregnant patient is particularly difficult because of multiple confounding factors related to normal pregnancy. Such confounding factors include nonspecific leukocytosis, displacement of abdominal and pelvic structures from their normal locations by the gravid uterus, a difficult abdominal examination, and nonspecific nausea and vomiting.^{21,22}

During the second and third trimesters of pregnancy, the gravid uterus increases in size and displaces the pelvic contents from their normal locations.

In the same way like in PE is difficult the definition of absolute indication for diagnostic imaging.

Ultrasonography (US) is considered the imaging study of choice for evaluation of abdominal pain in pregnant patients, MR imaging is a valuable adjunct to US in evaluation of pregnant patients with acute right lower quadrant (RLQ) pain who have inconclusive US results. CT should not be used because the radiation damages the embryogenesis and can cause carcinogenesis. CT can be performed in the second and third trimesters if MR imaging is unavailable or if there is lack of expertise (*figure 4*).

5

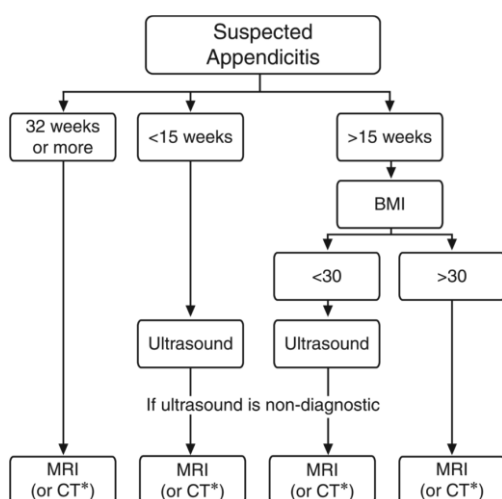


Figure 4: Algorithm for work-up of right lower quadrant abdominal pain in a pregnant patient when there is a strong suspicion of appendicitis. BMI = body mass index, * = use CT if MR imaging is unavailable.

MR examination is thought to be safe in pregnancy and can be used regardless of the trimester when the outcome of the examination has the potential to affect the care of the patient. Examinations are performed at a field strength of 1.5 T with the patient in the supine position and with a body phased-array coil. Intravenous contrast agents are not used.

The MR imaging protocol for pregnant patients is detailed in table 5. Single-shot fast SE images are acquired in the three orthogonal planes (axial, coronal, and sagittal). Single-shot imaging provides a motion-insensitive strategy even in the presence of severe fetal motion.

Axial single-shot fast SE images with frequency-selective fat saturation pulses improve the detection of inflammatory changes and edema.

Axial TOF GRE T2*-weighted images are used to differentiate the normal appendix from the

commonly seen dilated venous tributaries of the right gonadal

Axial T1-weighted inphase and opposed-phase GRE images are valuable to identify hemorrhagic and fat-containing lesions.

Parameters	Pulse Sequences*					
	Coronal Single-Shot Fast SE	Axial Single-Shot Fast SE	Sagittal Single-Shot Fast SE	Axial 2D FS Single-Shot Fast SE	IP and OP 2D T1W GRE	2D TOF
Sequence type	Single shot	Single shot	Single shot	Single shot	GRE	GRE
Repetition time (msec)	800-1100	800-1100	800-1100	800-1100	205	5500
Echo time (msec)	60	60	60	60	2.2/4.5	100
Flip angle (degrees)	130-155	130-155	130-155	130-155	80	45
No. of signals acquired	1	1	1	1	1	1
2D or 3D	2D	2D	2D	2D	2D	2D
Section thickness (mm)	4	4	4	4	5	3
Gap (mm)	1	1	1	1	2	1
Field of view (mm)	350	350	350	350	350	350
No. of partitions or sections	20	20	20	20	32	24
Orientation	Coronal	Axial	Sagittal	Axial	Axial	Axial
Phase × frequency steps	192 × 256	192 × 256	192 × 256	192 × 256	160 × 256	128 × 256
Rectangular field of view	No	0.75	0.75	0.75	0.75	0.75
Fat suppression	No	No	No	Yes	No	No
Zero fill section	No	No	No	No	No	No
Partial Fourier	Yes	Yes	Yes	Yes	No	No
No. of measurements or repeats	1	1	1	1	1	1
Single or multiple shots	Single	Single	Single	Single	Multiple	Multiple
Echo train length	---	---	---	---	---	---
Bandwidth (kHz)†	62.5	62.5	62.5	62.5	62.5	31.25
Parallel imaging	No	No	No	No	No	No
Breath hold	Yes	Yes	Yes	Yes	Yes	Yes

Table 5: MR Imaging Protocol for Pregnant Patients with Acute RLQ Pain

Urinary Tract Disorders

Nephro- and ureterolithiasis represent the most common causes of abdominal pain of urologic origin.

US is frequently used as a screening examination, as US is a sensitive and specific test for diagnosing hydronephrosis and does not expose the patient or fetus to ionizing radiation.²²⁻²⁴ However, the differential diagnosis of hydronephrosis in the pregnant patient is confounded by physiologic hydronephrosis of pregnancy, which is thought to be

caused by compression of the ureters between the gravid uterus and the linea terminalis.²⁵

Physiologic hydronephrosis of pregnancy occurs in >80% of pregnant women, more commonly occurs on the right than the left, and is generally seen beginning in the second trimester.²⁵ Low-dose NCCT has been shown to be a sensitive and specific test for diagnosing stones in pregnant patients

Visualization of stones in the urinary tract is challenging with MR imaging, particularly intrarenal stones and those at the ureterovesical junction.

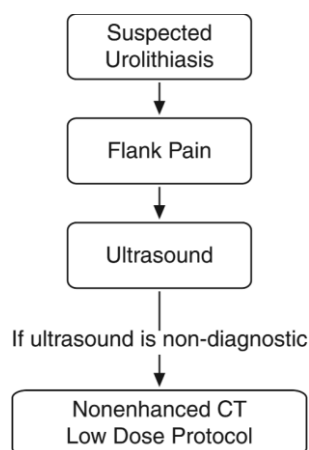


Figure 5: Diagnostic algorithm for suspected urolithiasis.

Clinical Condition: Acute Onset Flank Pain – Suspicion of Stone Disease (Urolithiasis) Variant 3: Pregnant patient.

Radiologic Procedure	Rating	Comments	RRL*
US color Doppler kidneys and bladder retroperitoneal	8		0
CT abdomen and pelvis without IV contrast	6		☻☻☻
MRI abdomen and pelvis without IV contrast	5		0
CT abdomen and pelvis without and with IV contrast	2		☻☻☻☻
CT abdomen and pelvis with IV contrast	2		☻☻☻
X-ray abdomen and pelvis (KUB)	2		☻☻
Radiography intravenous urography	1		☻☻☻
MRI abdomen and pelvis without and with IV contrast	1		0
Rating Scale: 1,2,3 Usually not appropriate; 4,5,6 May be appropriate; 7,8,9 Usually appropriate			*Relative Radiation Level

Table 6: ACR. Imaging appropriateness in suspected urolithiasis in pregnant patient.

Iodinated contrast media in pregnancy

In general, intravascular contrast media should be avoided in pregnancy, in order to avoid any possible hazard to the fetus. In vitro experiments have shown iodinated contrast to be mutagenic to human cells.²⁶ Reassuringly, animal studies have failed to show an in vivo teratogenic effect.^{27,28} The iodine content of contrast media has the potential to produce neonatal hypothyroidism, and this has been observed after the direct instillation of ionic contrast into the amniotic cavity during amniocentesis.²⁹ The intravascular

use of non-ionic contrast media has been reported to have no effect on neonatal thyroid function.³⁰ It is standard pediatric practice to screen all neonates for hypothyroidism, but it is particularly important to perform this test in the infants of mothers who received iodinated contrast during pregnancy.³¹

Gadolinium contrast in pregnant patients

The conclusion of a recent large cohort study from Ontario, Canada (Ray JG et al. JAMA. 2016;316(9):952-961) states, "Exposure to MRI during the first trimester of pregnancy compared with

nonexposure was not associated with increased risk of harm to the fetus or in early childhood. Gadolinium MRI at any time during pregnancy was associated with an increased risk of a broad set of rheumatological, inflammatory, or infiltrative skin conditions and for stillbirth or neonatal death.

Intravenous gadolinium is teratogenic in animal studies.³² While teratogenic effects have not been observed in a small number of human studies where gadolinium has been given in pregnancy,^{33,34} it is clear that gadolinium should not be administered in pregnancy unless there is an absolutely essential clinical indication, particularly during the period of organogenesis. Administration of gadolinium later in pregnancy may be reasonable, although such indication would likely be for a maternal or obstetric indication rather than for evaluation of a fetal abnormality. Examples might include gadolinium enhanced imaging for a maternal brain tumor or suspected placenta accreta. Gadolinium crosses the placenta where it is presumably excreted by the fetal kidneys into the amniotic fluid. In the era of gadolinium-induced nephrogenic systemic fibrosis, this raises theoretical concerns of toxicity related to disassociation and persistence of free gadolinium. Such concerns reinforce the regulatory advice on gadolinium use in pregnancy. The 2007 ACR guidance document for safe MRI practices recommends that intravenous gadolinium should be avoided during pregnancy and should only be used if absolutely essential; furthermore, the risks and benefits of gadolinium use

must be discussed with the pregnant patient and referring clinician.³⁵ Gadolinium is classified as a category C drug by the Food and Drug Administration and can be used if considered critical (only to be administered "if the potential benefit justifies the potential risk to the fetus").

The American College of Gynecology and Obstetrics recommends that pregnant patients should be reviewed on a case-to-case basis, and the risk-benefit ratio needs to be made by the physicians involved. There are no known biological effects of MRI on fetuses. Gadolinium should be avoided when examining a pregnant patient.

Conclusions

Modalities that do not use ionizing radiation, such as US and MR imaging, should be the preferred examinations for evaluating an acute condition in a pregnant patient. However, no examination should be withheld when an important clinical diagnosis is under consideration. Exposure to ionizing radiation may be unavoidable, but there is no evidence to suggest that the risk to the fetus after a single imaging study and an interventional procedure is significant. All efforts should be made to minimize the exposure, with consideration of the risk versus benefit for a given clinical scenario.

References

1. Coakley FV, Glenn OA, Qayyum A, Barkovich AJ, Goldstein R, Filly RA. Fetal MRI: a developing technique for the developing patient. *AJR Am J Roentgenol* 2004;182(1):243-252.
2. Wagner LK, Lester RG, Saldana LR. Exposure of the pregnant patient to diagnostic radiations: a guide to medical management. 2nd ed. Madison, Wis: Medical Physics, 1997.
3. Brent RL. Saving lives and changing family histories: appropriate counseling of pregnant women and men and women of reproductive age, concerning the risk of diagnostic radiation exposures during and before pregnancy. *Am J Obstet Gynecol* 2009;200(1): 4-24.
4. Bushberg JT. The essential physics of medical imaging. 2nd ed. Philadelphia, Pa: Lippincott Williams & Wilkins, 2002.
5. Wieseler KM¹, Bhargava P, Kanal KM, Vaidya S, Stewart BK, Dighe MK. Imaging in pregnant patients: examination appropriateness. *Radiographics*. 2010 Sep;30(5):1215-29; discussion 1230-3. doi: 10.1148/rg.305105034.
6. American College of Radiology. ACR practice guideline for imaging pregnant or potentially pregnant adolescents and women with ionizing radiation. Reston, Va: American College of Radiology, 2008
7. Patel SJ, Reede DL, Katz DS, Subramaniam R, Amorosa JK. Imaging the pregnant patient for nonobstetric conditions: algorithms and radiation dose considerations. *RadioGraphics* 2007;27(6): 1705-1722.
8. Martin JN Jr, Ridgway LE 3rd, Connors JJ, Sessums JK, Martin RW, Morrison JC. Angiographic arterial embolization and computed tomography-directed drainage for the management of hemorrhage and infection with abdominal pregnancy. *Obstet Gynecol* 1990;76(5 pt 2):941-945.
9. Bushberg JT. X-ray interactions. *RadioGraphics* 1998;18(2):457-468.
10. Togliola MR, Weg JG. Venous thromboembolism during pregnancy. *N Engl J Med* 1996; 335:108-114.
11. Knight M. Antenatal pulmonary embolism: risk factors, management and outcomes. *BJOG* 2008; 115:453-461.
12. Winer-Muram HT, Boone JM, Brown HL, Jennings SG, Mabie WC, Lombardo GT. Pulmonary embolism in pregnant patients: fetal radiation dose with helical CT. *Radiology* 2002;224:487-492.
13. British Thoracic Society Standards of Care Committee Pulmonary Embolism Guideline Development Group. British Thoracic Society guidelines for

- the management of suspected acute pulmonary embolism. *Thorax* 2003; 58:470-483.
14. Schuster ME, Fishman JE, Copeland JF, Hatabu H, Boiselle PM. Pulmonary embolism in pregnant patients: a survey of practices and policies for CT pulmonary angiography. *AJR Am J Roentgenol* 2003; 181:1495-1498.
 15. Stein PD, Woodard PK, Weg JG, et al. Diagnostic pathways in acute pulmonary embolism: recommendations of the PIOPED II investigators. *Radiology* 2007; 242:15-21.
 16. **Pahade JK¹, Litmanovich D, Pedrosa I, Romero J, Bankier AA, Boiselle PM.** *Radiographics.* Quality initiatives: imaging pregnant patients with suspected pulmonary embolism: what the radiologist needs to know. 2009 May-Jun;29(3):639-54. doi: 10.1148/rg.293085226. Epub 2009 Mar 30.
 17. Leung AN, Bull TM, Jaeschke R, Lockwood CJ, Boiselle PM, Hurwitz LM, James AH, McCullough LB, Menda Y, Paidas MJ, Royal HD, Tapson VF, Winer-Muram HT, Chervenak FA, Cody DD, McNitt-Gray MF, Stave CD, Tuttle BD; ATS/STR Committee on Pulmonary Embolism in Pregnancy. **An official American Thoracic Society/Society of Thoracic Radiology clinical practice guideline: evaluation of suspected pulmonary embolism in pregnancy.** *Am J Respir Crit Care Med.* 2011 Nov 15;184(10):1200-8. doi: 10.1164/rccm.201108-1575ST.
 18. Parker MS, Hui FK, Camacho MA, Chung JK, Broga DW, Sethi NN. Female breast radiation exposure during CT pulmonary angiography. *AJR Am J Roentgenol* 2005; 185:1228-1233.
 19. Rehani MM, Berry M. Radiation doses in computed tomography: the increasing doses of radiation need to be controlled. *BMJ* 2000; 320:593-594.
 20. Nickoloff EL, Alderson PO. Radiation exposures to patients from CT: reality, public perception, and policy. *AJR Am J Roentgenol* 2001; 177:285-287
 21. Andersen B, Nielsen TF. Appendicitis in pregnancy: diagnosis, management and complications. *Acta Obstet Gynecol Scand* 1999;78(9):758-762.
 22. Cappell MS, Friedel D. Abdominal pain during pregnancy. *Gastroenterol Clin North Am* 2003;32 (1):1-58.
 23. Wieseler KM, Bhargava P, Kanal KM, Vaidya S, Stewart BK, Dighe MK. Imaging in pregnant patients: examination appropriateness. *Radiographics.*

- 2010;30(5):1215-1229; discussion 1230-1213.
24. Masselli G, Derme M, Laghi F, et al. Imaging of stone disease in pregnancy. *Abdom Imaging*. 013;38(6):1409-1414.
25. McAleer SJ, Loughlin KR. Nephrolithiasis and pregnancy. *Curr Opin Urol*. 2004;14(2):123-127.
26. Rasmussen PE, Nielsen FR. Hydronephrosis during pregnancy: a literature survey. *Eur J Obstet Gynecol Reprod Biol*. 1988;27(3):249-259.
27. Nelson JA, Livingston JC, Moon RG. Mutagenic evaluation of radiographic contrast media. *Invest Radiol* 1982; 17: 183-185.
28. Morisetti A, Tirone P, Luzzani F, de Haen C. Toxicologic safety assessment of iomeprol, a new x-ray contrast agent. *Eur J Radiol* 1994; 18 (Suppl 1): 21-31.
29. Ralston WH, Robbins MS, James P. Reproductive, developmental, and genetic toxicity of ioversol. *Invest Radiol* 1989; 24 (Suppl 1): 16-22.
30. Desch F, Camus M, Ermans AM, et al. Adverse effects of amniotography on fetal thyroid function. *Am J Obstet Gynecol* 1976; 126: 723-726.
31. Na G, Zaffaroni M, Defilippi C, et al. Effects of iopamidol on neonatal thyroid function. *Eur J Radiol* 1992; 12: 22-25.
32. Webb JA, Thomsen HS, Morcos SK; Members of Contrast Media Safety Committee of European Society of Urogenital Radiology (ESUR). The use of iodinated and gadolinium contrast media during pregnancy and lactation. *Eur Radiol* 2005; 15: 1234-1240.
33. Okuda Y, Sagami F, Tirone P, Morisetti A, Bussi S, Masters RE. Reproductive and developmental toxicity study of gadobenate dimeglumine formulation (E7155) (3) --Study of embryo-fetal toxicity in rabbits by intravenous administration. *J Toxicol Sci* 1999;24 (Suppl 1): 79-87.
34. Marcos HB, Semelka RC, Worawattanakul S. Normal placenta: gadolinium-enhanced dynamic MR imaging. *Radiology*. 1997; 205: 493-6.
35. Spencer JA, Tomlinson AJ, Weston MJ, Lloyd SN. Early report: comparison of breath-hold MR excretory urography, Doppler ultrasound and isotope renography in evaluation of symptomatic hydronephrosis in pregnancy. *Clin Radiol*. 2000;55: 446-53.
36. Kanal E, Barkovich AJ, Bell C, Borgstede JP, Bradley WG, Jr., Froelich JW, et al. ACR guidance document for safe MR practices: 2007. *AJR Am J Roentgenol* 2007; 188: 1447-74.