



IJAPC

VOLUME 9 ISSUE 3 2018

**GREEENTREE GROUP
PUBLISHERS**

E ISSN 2350-0204

WWW.IJAPC.COM

"A peer-reviewed journal dedicated to allied Sciences"



A Diagnostic Approach on Pleural Effusion w.s.r to *Urasthoya* – A Review

Rijin Mohan^{1*}, Vishnu C P², Sharada Sphoorthi Y³, and Gopikrishna S⁴

¹⁻⁴Department of Roganidana Evum Vikruti Vigyana, Sri DharmasthalaManjunatheshwara College of Avurveda and Hospital. Hassan. India

ABSTRACT

Pleural effusion is one among the health issues that affects both gender globally. Excessive accumulation of pleural fluid occurs either due to increased hydrostatic pressure or decrease osmotic pressure¹. The diagnosis of pleural effusion is difficult, even though the patients often complain of typical symptoms indicating of pleural diseases. Explanation regarding a similar disease namely *Urasthoya* is found in *Ayurvedic* classic text book, *Madhavanidana* in *Parisistabagha*. The etiological factors and symptomatology shows similarity. Thus *Urasthoya* can be a possible correlation for pleural effusion. Diagnosis of pleural effusion depends on proper clinical examination as well as various diagnostic methods. The symptoms depend upon the underlying pathology, so it is very important to adopt appropriate diagnostic tool to attain proper diagnosis. The diagnostic approach in *Ayurveda* is based on *RogaRogiPariksha* (Examination of disease and patient). In *Urasthoya Trividha Pariksha* (Three fold examination) and *Astasthana Pariksha* (Eight fold examination) can be adopted for diagnosis. So it is important to have a proper diagnostic approach in both modern and *Ayurvedic* point of view. This particular paper discusses the possible diagnostic approach on pleural effusion and *Urasthoya*.

KEYWORDS

Pleural effusion, Urasthoya, Diagnosis



Greentree Group Publishers

Received 16/10/18 Accepted 05/11/18 Published 10/11/18



INTRODUCTION

Pleural effusion is one among common health issues. Globally 0.3% prevalence was observed equally in both genders². Term pleural effusion consists of two words that is pleura and effusion. Pleura which means that membrane surrounding the lungs and effusion means escape of fluid from anatomical vessel by rupture or exudation. It is defined as an excessive accumulation of serous fluid in pleural space. Normally 0.1- 0.2 ml / kg of fluid is present in pleural leaves to facilitate pleural movement. When the balance between the production and reabsorption of this fluid deteriorates, it becomes pleural effusion. The accumulation is usually associated with many medical conditions that predispose to fluid accumulation via many different mechanisms. In *Ayurvedic* classics *Madhavakara* in 7th century AD explained a similar condition namely *Urasthoya* in *Parisistabagha* of his treaty *Madhavanidana*. The term *Uras* refers to the thoracic region³ and the *Thoya* refers to fluid⁴, collectively we can understand it as fluid accumulation or fluid in the thoracic region. On analysing the etiological factors and symptomatology of *Urasthoya* as well as pleural effusion, similarities can be observed. The signs and symptoms of pleural effusion vary according to the underlying pathology. It's always a difficult task to a physician to diagnose the pleural effusion. Properly diagnostic approach is essential for a better diagnosis, prognosis and management. *Ayurveda* have its own ideal method of diagnosing a disease, that is *Roga* and *Rogipariksha*. So in this article an attempt is made to understand the pleural effusion and *Urasthoyaby* analysing various etiological factors and symptoms,

thereby a better *Ayurvedic* understanding can be framed for formulating a good diagnostic approach there by helping for diagnosis and management of pleural effusion.

MATERIALS AND METHODS

Etiopathogenesis and diagnostic approach of pleural effusion in relation to *Urasthoya* is discussed in this article with both *Ayurvedic* and contemporary references.

OBSERVATION AND RESULTS:

Nidana (causes) of Pleural effusion and *Urasthoya*⁵


Table 1 Comparative analysis of causative factors of pleural effusion and *Urasthoya*

S No	URASTHOYA	PLEURAL EFFUSION
1.	<i>Jwaradianubandha</i> (associated with fever)	Rheumatic heart disease, tuberculosis
2.	<i>Gupta</i> (hidden)	Neoplastic condition
3.	<i>Abhighata</i> (trauma)	Any type of insult to thoracicregion
4.	<i>Anyanidana</i> (other causes)	SLE, MI, Drug induced, Sub phrenic abscess, Radiation therapy etc

Jwaranubandha, *Gupta*, *Abhigata* and *Anyanidana* are explained as the causative factor of *Urasthoya*. On a comparative analysis it shows a close relationship with etiological factors of pleural effusion. Pleural effusion is again classified into transudative and exudative pleural effusion where the aetiology varies.



Diagram 1: showing causes of transudative and exudative pleural effusion⁵



SIGNS AND SYMPTOMS OF PLEURAL EFFUSION AND URASTHOYA

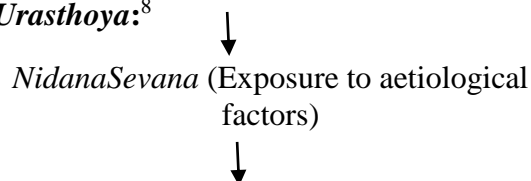
Pleural effusion may be unilateral or bilateral depending on the underlying pathology. Bilateral pleural effusion occurs due to cardiac failure, connective tissue disorder, hypoproteinemia etc. *SwasaKruchrata* (Difficulty in breathing), *Kasa* (cough), *Angagada Shotha* (oedema), *Neelatwa* of *Asya* and *Adhara* (bluish discolouration of face and lips), *Mutra Alpata* (reduced urine output), *Drutha Gati Nadi* (increased pulse rate), *Shayanasya Na Soukhyam* (Difficulty to breathing in supine position), *AsinevamSukhi* (Feeling comfort in sitting posture) are the *Lakshans* of *Urasthoya*⁶. Dyspnoea and non-productive cough are the common symptoms of pleural effusion. Other symptoms depend upon underlying pathologies.

Table 2 Comparative analysis of signs and symptoms of pleural effusion⁷ and *Urasthoya*

SL No	<i>Urasthoya</i>	Pleural effusion
1.	<i>Swasakruchratha</i>	Dyspnoea
2.	<i>Jwara</i>	High grade Fever
3.	<i>NeelaAsayaandAdhara</i>	Central cyanosis
4.	<i>Kasa</i>	Non-productive cough
5.	<i>AngagataSotha</i>	Oedema
6.	<i>MutraAlpata</i>	Oliguria
7.	<i>Shayanasya Na Soukhyam</i>	Difficulty to breathing in supine position
8.	<i>AseenevaSukhi</i>	Feeling comfort in sitting posture
9.	<i>DruthaGatiNadi</i>	Increased pulse rate
10.	<i>Pipasa</i>	Polydipsia

Diagram 2: showing Etiopathogenesis of urasthoya

Samprapthi (Etiopathogenesis) of *Urasthoya*:⁸





Kapha and Vata Prakopa (Vitiation of *Vata* and *Kapha* humor)



Sthanasamsraya in Urapradesa (Localization of *Kapha* humor in chest region)



Urasthoya

Diagnostic approach

- 1) Clinical presentation that is presenting history of the patient and physical examination.
- 2) Radiology- conventional radiography, USG, CT.
- 3) Plural fluid analysis.
- 4) Bronchoscopy
- 5) Pleural fine needle biopsy

Clinical presentation

Dyspnoea and non-productive cough indicating restrictive type of respiratory failure, reduced lung volume and capacity is generally observed. Symptoms of underlying pathology are also observed. Findings of physical examination vary according to the amount of effusion. Normally up to 300 ml is found to be asymptomatic. On examination reduced vocal fremitus on affected side, reduced or absence of breath sounds, pleural rub, media sternal shift (opposite deviation of trachea) can be well appreciated. Due to underlying pathology peripheral oedema,

visible jugular venous pulse, cutaneous changes and lymphadenopathy can be observed.

Radiology- conventional radiography, USG, CT

PA view of chest X ray in pleural effusion will show blend costophrenic angle if amount of fluid is more than 200 ml. Lateral view of chest X ray in pleural effusion will show blend costophrenic angle if amount of fluid is more than 50 ml. AP view of chest X ray in pleural effusion will show blend costophrenic angle if amount of fluid is more than 300 ml.

Thoracic USG will detect presence of 5 – 50 ml of pleural fluid and is 100 % sensitive for fluid effusion. It helps to find the presence of pleural effusion, identify the correct location of thoracosynthesis and to differentiate between pleural effusion and pneumothorax.

CT helps in demonstration of abnormalities of lung parenchyma. Differentiating between pneumothorax and pleural effusion. Identification of pleural thickening⁹

Bronchoscopy

Bronchoscopy is normally done in patient having pleural effusion associated with haemostasis, pulmonary infiltration in chest massive pulmonary effusion more than three fourth of hemithorax, mediastinal shift towards the side of effusion.



Pleural fine needle biopsy

Biopsy is done to establish diagnosis of underlying pathology such as tuberculosis malignancy etc.

Pleural fluid analysis

Table 3 Pleural fluid changes in various condition¹⁰

S no	Colour	Appearance	Condition
1.	Light yellow	Clear	Transudative effusion
2.	Straw yellow	Fiber net	Tuberculosis
3.	Chocolate	Turbid	Amoebic abscess
4	Black	Turbid	Aspergillosis

DISCUSSION

Madhavakara explains the etiological factors of *Urasthoya* as *Jwaranubandha*, *Gupta*, *Abhigata* and *Anya Nidana*. The etiological factors of pleural effusion are broadly classified under two main headings according to the effusion that is transudative and exudative. Proper understanding aetiology of pleural effusion will be provided by detail history taking. For example fever indicate an infective aetiology, a history of cardiac, renal or liver impairment can suggest transudative effusion. A history of weight loss, old age along with smoking point towards a diagnosis of malignant pleural effusion. Pedal oedema or deep vein thrombosis may result in an effusion related to pulmonary embolism. A history of trauma may result in haemothorax or chylothorax¹¹.

Analysis of both aetiological factors reveals similarities. *ShwasaKruchrata*, *Shayanasya Na Sowkhyam* and *Aseeneva Sukhi* are the symptoms that can be observed in *Urasthoya*. Similar symptoms can be observed in pleural effusion also. In both disease other symptoms depends upon the underlying pathology. For example *Neelasyatwam* (central cyanosis) present in *Urasthoya* indicates underlying congestive cardiac failure, pneumonia etc¹². *Angagata Sotha* indicate underlying pathology such as congestive cardiac disease, Hypoproteinemia etc. Pleural effusion associated with pyrexia is commonly seen in lung pathology such as Tuberculosis, lung infections etc. pleural effusion may be unilateral or bilateral depending on the aetiology. Bilateral often occur in cardiac failure, hypoproteinemia etc.

Ayurvedic diagnosis of Urasthoya

Prathyaksha Pariksha:¹³

1. *Angagatasho* (Oedema)
2. *Kaphasrava* (increased expectoration)
3. *Shayanasya Na Sowkhyam* (Difficulty to breathing in supine position)
4. *Aseeneva Sukhi* (Feeling comfort in sitting posture)
5. *Neelatwa of Asya and Adhara* (bluish discoloration of face and lips)
6. *Swasakruchrata* (Difficulty in breathing)

Anumana Pariksha:



Presence of underlying cardiac pathology can be inferred by *Neelatwa* of *asyaandadhara* (bluish discoloration of face and lips) and *Angagatashotha* (Oedema).

Astasthana Pariksha:¹⁴

Nadi: *Sukshma*, *Dhrutagati* and *Vishamarupinadi*

Mutra: *Bahu Mandavegi Mutrapravruithi*, sometimes *Alpa*

Jihwa: *Neela*

Sparsha: *Ushna* (if underlying pathology is associated with fever)

Prashna Pariksha:

1. *Pipasa* (Polydipsia)
2. *Mutra:* *Bahu Mandavegi Mutrapravruithi*.
3. *Aseeneva Sukhi* (feeling comfort in sitting posture)
4. *Shayanasyanasoukhyam* (Difficulty to breathing in supine position)

The common symptom of *Urasthoya* includes *Swasakruchrata* (Difficulty in breathing), which is the common *Lakshana* (Symptoms) of *Pranavaha Srotovikara* (Disorders related to respiratory system). So it's important to differentiate from other types of various *Pranavahasrotovikaras*. For example the same symptoms (*Swasakruchrata*, *Shayanasyanasoukhyam*, *Aseeneva Sukhi*) can be seen in case of *Tamaka Swasa* (Bronchial asthma). So proper *Prashna Pariksha* (History taking) is very important

to know the other associated symptoms and underlying pathologies. Various examination mentioned in *Ayurvedic* classical text books, such as *Prathyaksha Pariksha*, *Prasna Pariksha* along with *Astasthana Pariksha* adopted for the diagnosis of *Urasthoya*.

CONCLUSION

Pleural effusion and *Urasthoya* shows close relation to each other in *Nidana* and *Lakshana* so *Urasthoya* can be a possible correlation for pleural effusion. Symptoms such as *Shwasa Kruchrata*, *Shayanasya Na Soukhyam* and *Aseeneva Sukhi* are common in *Urasthoya* and all other symptoms depends on underlying pathology. In case of pleural effusion clinical presentation, that is presenting history of the patient and physical examination, radiology-conventional radiography, USG, CT, Pleural fluid analysis, Bronchoscopy and Pleural fine needle biopsy can be used for better diagnosis. In *Ayurveda* various *Roga Rogi Parakeeshas* such as *Prathyaksha Pariksha*, *Prasna Pariksha* along with *Astasthana Pariksha* can be utilized for diagnosis.



REFERENCES

1. Davidson's principles and practice of medicine 19th ed. Edited by Christopher Haslett edwin R. Chilvers Nicholas A. Boon. Nicki. R. college, international editor John. A. A. Hunter. chapter 13. P.501.
2. Yataco J C, Dweilk R A (2005), pleural effusion; Evaluation and management. Cleve clin J Med 72, p.854.
3. Sir Monir Williams; sanskrit- english dictionary, 2nd edition. Bharatiya Granth Niketan, Delhi; 2007. p.217.
4. Sir Monir Williams; sanskrit- english dictionary, 2nd edition. Bharatiya Granth Niketan, Delhi; 2007. p.456.
5. Madhavakara, Vijayarakshita, Srikantadatta, Tripathy B. MadhavaNidana with Madhukoshavyakhya and VimalaMadhudhara Hindi Vyakhya. 2nd edition. Parisistabhaga, verse 1. Varanasi: ChaukhambaSurabharatiPrakashana; 2003. p.450.
6. Madhavakara, Vijayarakshita, Srikantadatta, Tripathy B. MadhavaNidana with Madhukoshavyakhya and Vimala Madhudhara Hindi Vyakhya. 2nd edition. Parisistabhaga, verse 3-5. Varanasi: Chaukhamba Surabharati Prakashana; 2003. p.451.
7. Harrison, Harrison's principles of internal medicine. 15th edition. New Delhi: McGraw Hill companies; 2008. p.1415.
8. Madhavakara, Vijayarakshita, Srikantadatta, Tripathy B. MadhavaNidana with Madhukoshavyakhya and VimalaMadhudhara Hindi Vyakhya. 2nd edition. Parisistabhaga, verse 2. Varanasi: ChaukhambaSurabharatiPrakashana; 2003. p.451.
9. Na, M. J (2014) Diagnostic tool of pleural effusion. Tuberculous and respiratory disease, 76 (5), p.199- 210
<http://doi.org/10.4046/trd.2014.76.5.199>
10. Incekara FO, Tikici DK, Nomenoglu H (2018) Pleural Effusions. Insights Chest Dis Vol.3 No.1:1
11. Karkhanis, V. S., & Joshi, J. M. (2012). Pleural effusion: diagnosis, treatment, and management. Open Access Emergency Medicine : OAEM, 4, 31–52.
<http://doi.org/10.2147/OAEM.S29942>
12. Harrison, Harrison's principles of internal medicine. 15th edition. New Delhi: McGraw Hill companies; 2008. p.215.
13. Agnivesh, Caraka, Dridabala, Acharya YT. CarakaSamhita with Ayurveda Deepika commentary of Chakrapanidatta on Carakasamhita by Agnivesha .vimanasthana; Trividharogavisheshavijnyananiyam; chapter 4: verse 18. Varanasi, ChaukhambaVishwaBharati Academy; 2008. P.248.



14. TripatyIndradev. Yogaratnakara with
vidhyaprabhahindi commentary. Varanasi:
Choukambha press; 1998. p.5.