



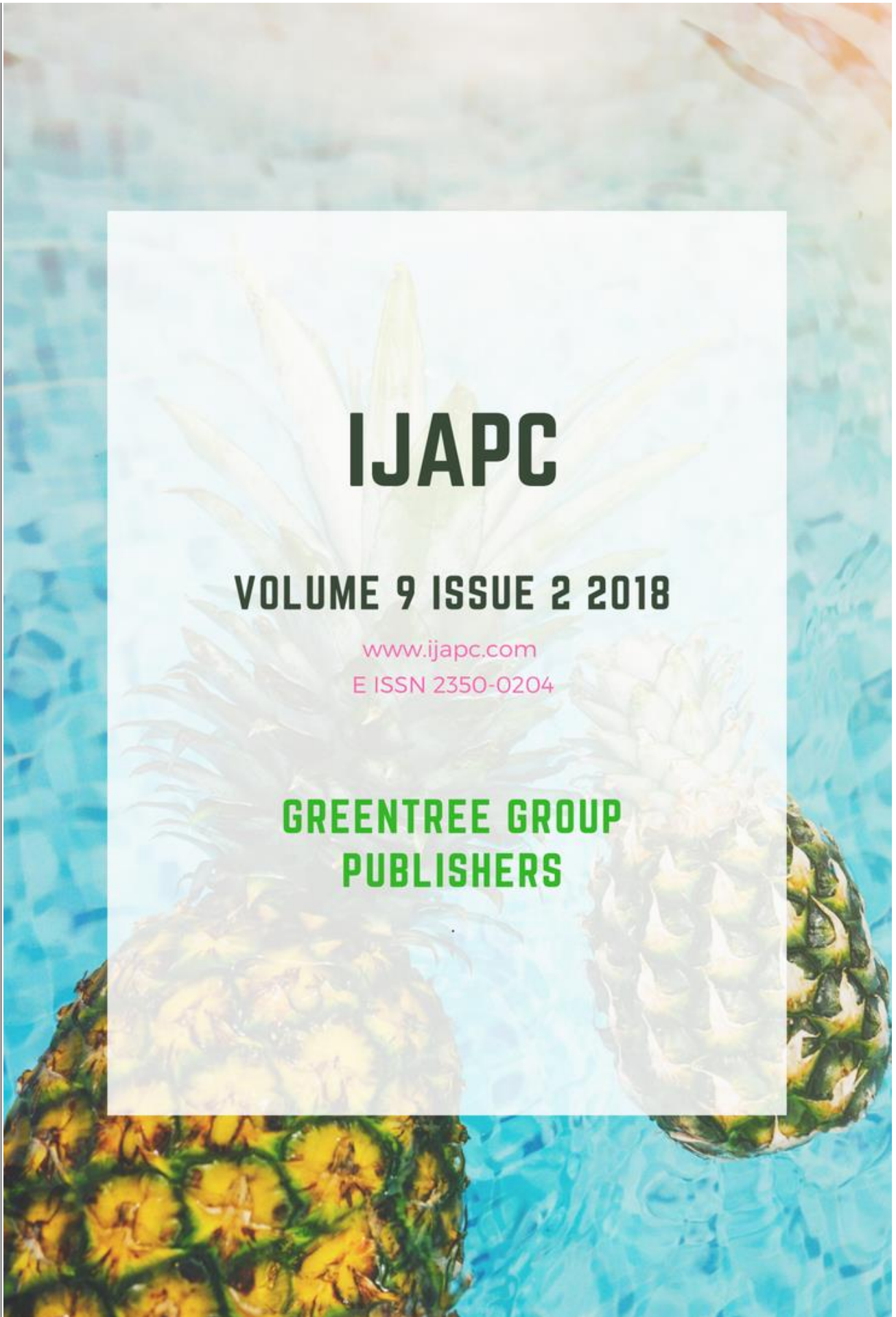
# IJAPC

**VOLUME 9 ISSUE 2 2018**

[www.ijapc.com](http://www.ijapc.com)

E ISSN 2350-0204

**GREENTREE GROUP  
PUBLISHERS**





## Bilateral Epididymal Cyst in 65 Years – Old Man – A Case Report

Thorat Nilesh Suresh<sup>1\*</sup>, Raut Subhash Y<sup>2</sup> and Kedar Nita M<sup>3</sup>

<sup>1-3</sup>Shalyatantra Department Govt. Ayurved College and Hospital, Nagpur, Maharashtra, India

### ABSTRACT

Smooth, extratesticular, spherical cysts in the head of the epididymis are common in adult men. Men are most likely to develop these cysts around the age of 40. Children rarely get them before they become teenagers. It's hard to give an exact percentage of men who have Epididymal cysts because, most people who have them don't even know it, but some studies have shown that about 1 in 6 men have them<sup>1</sup>. Here in, we report bilateral epididymal cyst in a 65 year –old man. He was admitted to Shalya department with symptoms of Hydrocele and acute B/ L scrotum. There was no history of trauma or infection. B/L Epididymal cyst was diagnosed on ultrasonographic evaluation. Medical treatment did not stop his scrotal pain. During exploration there was B/L epididymal cyst with B/L hydrocele. An excision of cyst was performed.

### KEYWORDS

*Epididymal cyst, Hydrocele, Testicular torsion*



**Greentree Group Publishers**

Received 10/08/18 Accepted 02/09/18 Published 10/09/18



## INTRODUCTION

Scrotal masses can be diagnosed by Transillumination or a scrotal ultrasonography examination. On Trans illumination, these masses may show primarily fluid, such as a tense hydrocele. If much firm extra-testicular masses palpated, then evaluation for Lymphoma, Leukemia or Metastatic disease should be performed with examination of the lymph nodes. Epididymal cysts may present as extra-testicular masses but they are usually smooth, round and characteristically located within the epididymis. They cause acute scrotum which is referred as the onset of pain, swelling, and or tenderness of intra-scrotal contents. Herein, we report a 65-year-old man with acute scrotum having Bilateral Epididymal cysts, diagnosed at Shalya department.

## CASE REPORT

A 65 year-old-man was admitted shalya outpatient clinic with painful B/L scrotal enlargement. There was no history of scrotal trauma or infection. On physical examination in B/L epididymal zone, a nodular mass was palpated without enlargement and tenderness of the testis. Additionally, there was a round small cyst palpated in the B/L epididymis. In scrotal ultrasonography, there was no findings of

left testicular torsion, and epididymal cyst was found bilaterally. In laboratory tests, blood parameters, urine analysis were within reference ranges. Non-steroid analgesics were prescribed for scrotal pain. The same day later the patient was admitted again at shalya department with the same symptoms. The day after surgery was carried out through a scrotal incision to remove the mass. The supra testicular mass was found to be a simple epididymal cyst that was excised.

## DISCUSSION

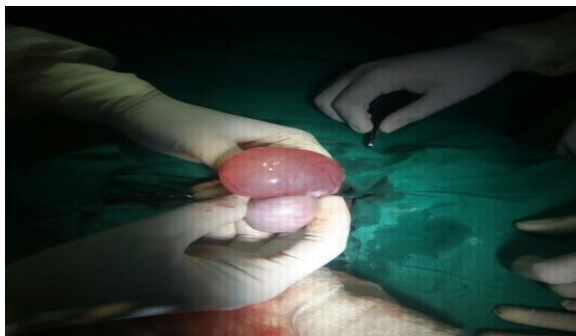
Unilateral epididymal cysts are common and occur at all ages. They are fluid filled cysts arising from the out flow duct of the testis (the epididymis). They are most often felt as a pea-sized swelling at the top part of the testis but they can become larger. Sometimes they cause acute scrotum in men. Here in, we reported a case of bilateral epididymal cysts. The pathophysiology of epididymal cyst is still unknown, but there are some reports that these cysts were related to an altered hormonal environment. Medical treatment options are the first line of therapy, as in our case we did. Still, the conservative treatment may sometimes be ineffective and surgery has to be performed to relieve an acute scrotum symptoms. Epididymal cysts are diagnosed on physical



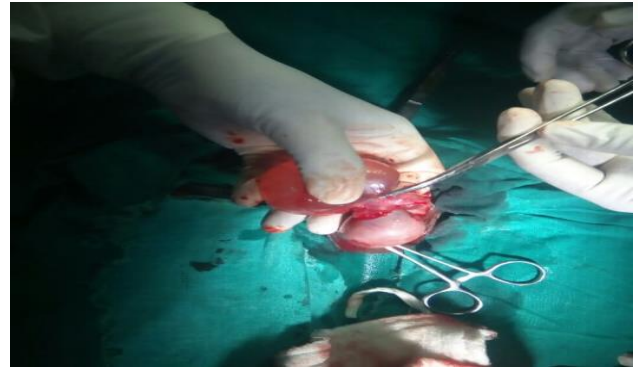


examination. They are palpated as extra testicular masses but also they are characteristically smooth, round and located within the epididymis<sup>2</sup>.

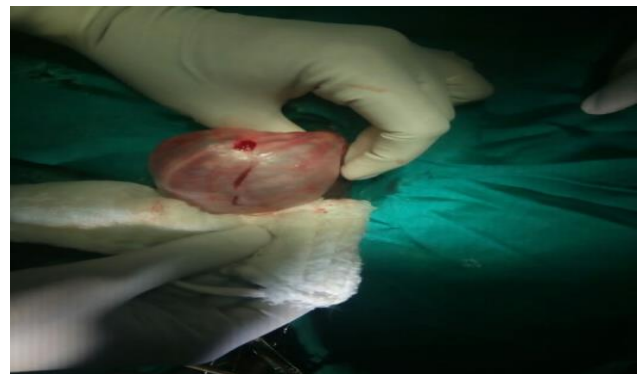For differential diagnosis, laboratory tests and scrotal ultrasonography was performed. These tests help us to make the distinction between epididymal cyst and testicular cancer. As radiological, in ultrasonography examination, epididymal cysts appear simple or minimally complex cysts and they can be diagnosed easily<sup>3</sup>. The treatment options depend on patient's findings. Most epididymal cysts involute with time. Conservative treatment options are usually used for palliation. Epididymal cysts are treated when they cause symptoms like acute scrotum, scrotal and/or inguinal pain. Primary excision is performed to remove the cyst<sup>4</sup>. The incision was taken lateral and parallel to median raphe to deliver the testis. (Figure no.1 and 2) Great care have to be taken as young men of reproductive age may cause scar tissue to form and block the outflow duct of the testis during the excision of cyst<sup>5</sup>.



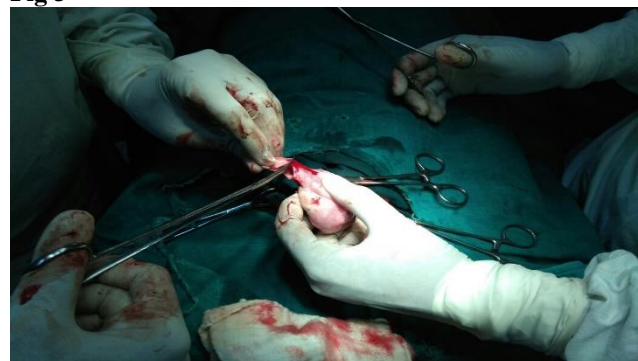**Fig 1**



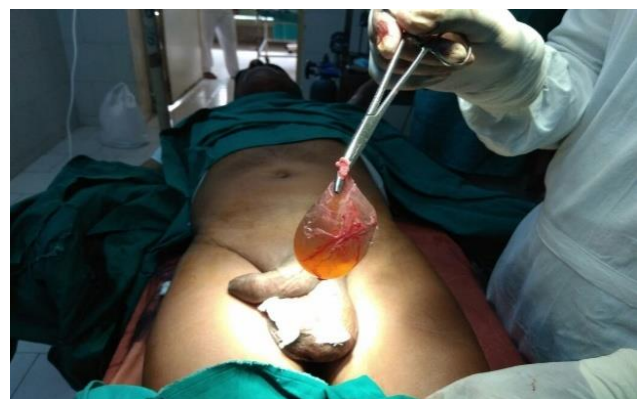**Fig 2**  
**Fig 1 and Fig 2** Operational and pathological view of B/L epididymal cyst



**Fig 3**



**Fig 4**  
**Fig 3 and Fig 4** After excision of epididymal cyst testicular view



**Fig 5** Excised epididymal cyst



## CONCLUSION

Medical treatment options are the first line of therapy in Epididymal cyst when they cause symptoms like acute scrotum, scrotal and/or inguinal pain. But conservative treatment may sometimes be ineffective and surgery has to be performed to relieve an acute scrotum symptoms. The treatment options depend on patient's findings after physical examination, radiological examination and lab tests.



## REFERENCES

1. Rioja J, Sanchez –margallo FM, RIOJA LA. Adult hydrocele and spermatocele .BJU int.2011; 107:1852-64.
2. Agrawal PK Palmar J S. Testicularand paratesticular neoplasms in prepubertal males .J Urol 2006; 176; 875-81.
3. Kauffman ec, kim HH Goldstein M.Microsurgical spermatocelectomy: technique and outcomes of a novel surgical approach .J Urol.2011; 185-42.
4. Wagner JP, Lubensky IA, Thakore K, Epididymal cyst adenomas in von Hippel – Lindau disease. Urology .1997; 49 :926-31.
5. Mehmet Sarac ,Isil Basara , Selcuk Yucel ,Ahmet Kazez ,Bilateral epididymal cyst in 14 year- old boy : a case report Jhsci 2014; 4(1):68-71.