

## Case Report

# Asian Pacific Journal of Tropical Medicine


journal homepage: [www.apjtm.org](http://www.apjtm.org)



doi: 10.4103/1995-7645.262078

Impact factor: 1.77

## Disseminated cysticercosis presenting with bilateral proptosis: A case report

Ravindra Kumar Garg , Neeraj Kumar, Imran Rizvi, Hardeep Singh Malhotra

Department of Neurology, King George's Medical University Uttar Pradesh, Lucknow, India

### ARTICLE INFO

#### Article history:

Received 20 November 2018

Revised 28 May 2019

Accepted 20 June 2019

Available online 9 July 2019

#### Keywords:

Neurocysticercosis  
Cysticercosis encephalitis  
Proptosis

### ABSTRACT

**Rationale:** Disseminated cysticercosis is characterized by presence of cysts in multiple body organs, like brain, skin, eyes, muscles and rarely heart and lungs.

**Patient concerns:** A 22-year-old man presented with bilateral proptosis of 1-year duration. He also had two episodes of cysticercosis encephalitis. In the second episode of encephalopathy, the patient died.

**Diagnosis:** Disseminated cysticercosis.

**Interventions:** Corticosteroids (Initially intravenous dexamethasone 0.4 mg/kg/day for 2 weeks, followed by oral prednisolone 1.0 mg/kg/day).

**Outcomes:** The patient died of cysticercosis encephalitis approximately 2 months later.

**Lessons:** Disseminated cysticercosis in our case presented only with proptosis as he had very heavy infestation of the brain and eyes. Heavy larval infestation in a patient with disseminated cysticercosis can be life-threatening.

## 1. Introduction

Bilateral proptosis is frequently caused by Graves' disease. Unilateral proptosis suggests a possibility of orbital cellulitis, vascular diseases like carotid-cavernous fistula and cavernous sinus thrombosis. Unilateral proptosis is also noted in many retrobulbar tumors. Infiltrative diseases, like collagen vascular disorders, sarcoidosis, leukemia and lymphoma, can produce both unilateral and bilateral proptosis. We are reporting a case of bilateral proptosis having an unusual cause.

## 2. Case report

A 22-year-old man came with bilateral proptosis of 1-year duration (King George Medical University in Lucknow India on 22 December, 2017). The consent to publish the images was from the father of the patient.

Two years ago, he had one generalized seizure, followed by altered sensorium, then he was treated for cysticercosis encephalitis. He remained in coma for 7 days, and received antiepileptic drugs and corticosteroids. He had improved remarkably. Then he continued medications for 1 month then stopped them. In the follow up, he had many seizures, last seizure occurred almost 1 year before. He still was not taking antiepileptic treatment and did not complain of diplopia. On examination, his vision was normal. Fundus examination did not

reveal any abnormality. Neurological examination, including detailed mental status examination was normal. Neuroimaging of brain revealed massive parenchymal cerebral neurocysticercosis. Many brain lesions demonstrated eccentric scolex (Figure 1). In addition, there was a heavy infestation of orbital tissues, leading to bilateral proptosis (Figure 2). We treated the patient only with corticosteroids. Albendazole was not given. Except proptosis, he remained asymptomatic for 2 months and discharged from hospital. Two-months later, the patient again developed encephalopathy and died in the intensive care unit.

## 3. Discussion

Ocular cysticercosis is commonly encountered in endemic countries, which is frequently a component of disseminated cysticercosis. Ocular cysticercosis either affect extraocular tissues like subconjunctival and periorbital structures or affect intraocular compartment where larva is present in vitreous fluid, subretinal space or found floating in anterior chamber. The patients with intraocular cysticercosis have vision loss[1-3]. Involvement of extraocular muscles is the commonest

This is an open access journal, and articles are distributed under the terms of the Creative Commons Attribution-NonCommercial-ShareAlike 4.0 License, which allows others to remix, tweak, and build upon the work non-commercially, as long as appropriate credit is given and the new creations are licensed under the identical terms.

**For reprints contact:** [reprints@medknow.com](mailto:reprints@medknow.com)

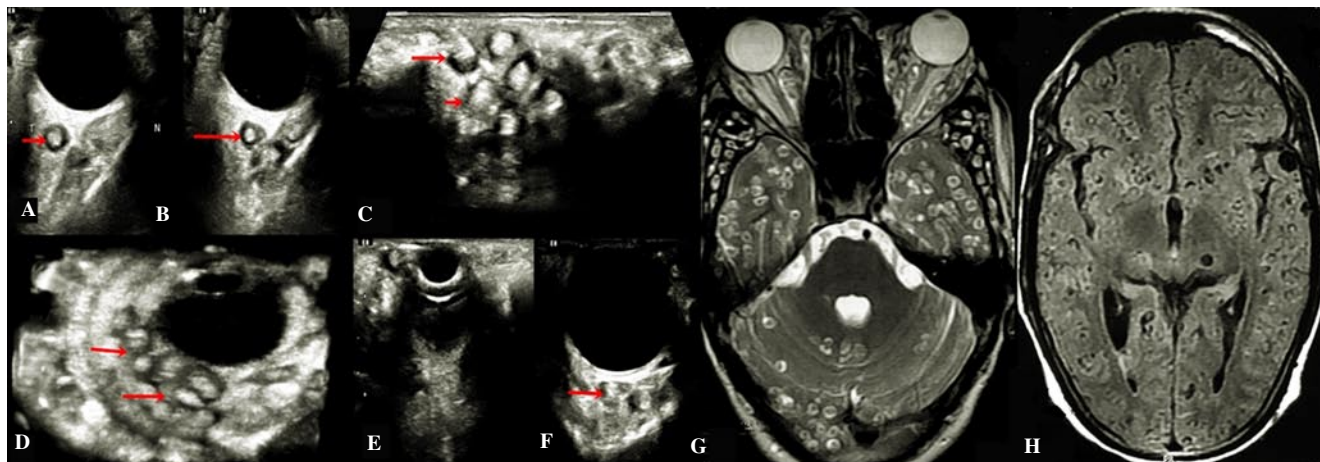
©2019 Asian Pacific Journal of Tropical Medicine Produced by Wolters Kluwer- Medknow. All rights reserved.

**How to cite this article:** Garg RK, Kumar N, Rizvi I, Malhotra HS. Disseminated cysticercosis presenting with bilateral proptosis: A case report. Asian Pac J Trop Med 2019; 12(7): 337-338.

 Corresponding author: Ravindra Kumar Garg, Department of Neurology, King George's Medical University, Uttar Pradesh, Lucknow 226003, India.

Tel.: +91-9335901790

E-mail: [garg50@yahoo.com](mailto:garg50@yahoo.com)

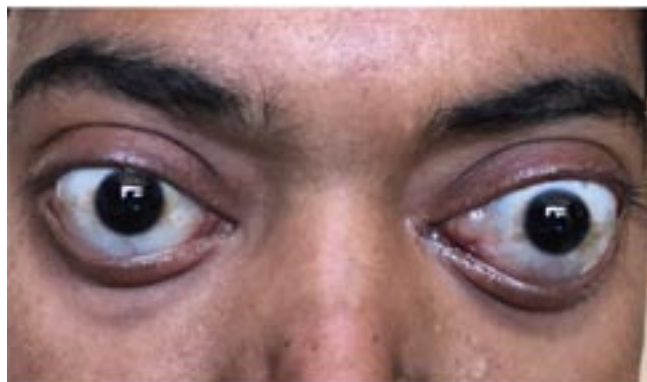

**Figure 1.** High-resolution sonography of the orbits showing multiple cysts (red arrows) involving the orbits (A-F). MRI brain T2W image shows multiple cystic lesions with scolex suggestive of neurocysticercosis involving the brain and the orbits (G). MRI brain FLAIR sequence shows massive cysticercosis (H).

form of ocular cysticercosis. Extraocular muscle cysticercosis clinically manifests with diplopia and ophthalmoplegia. If cyst is inflamed, eye pain and conjunctival redness are present. In some rare cases, larva affect optic nerve or subretinal space. B-scan ocular sonography is a reliable method for the demonstration of subretinal cysticercosis. On B-scan, subretinal neurocysticercosis appears as a well-defined cyst with a hyperechoic scolex[4,5].

Cysticercosis encephalitis is often associated with diffuse cerebral oedema and raised intracranial pressure. Cerebral oedema is caused by the intense host inflammatory response against antigens released by dying cysts. Antiparasitic treatment in cysticercosis encephalitis can be detrimental and sometimes life-threatening. Antiparasitic treatment in cysticercosis encephalitis is associated with further worsening of cerebral oedema[6,7]. We had deferred albendazole in our patient because he had evidence of cysticercosis encephalitis in the past.

The treatment of ocular cysticercosis depends upon location of the cyst. If the cyst is subretinal, it needs to be removed surgically. Antiparasitic treatment can be safely used for extraocular or retro-orbital cysticercosis. In intraocular cysticercosis, antiparasitic treatment can be detrimental. A dying cysticercosis cyst in eye can also evoke inflammatory reaction. Intraocular inflammatory reaction can result in vitritis, retinal hemorrhages, retinal detachment, proliferative vitreoretinopathy and disc edema. Patients with intraocular cysticercosis might manifest conjunctival redness, reduced visual acuity, vision loss or blurred vision. It is recommended that subretinal cysticercosis should be surgically removed before starting antiparasitic treatment[8-11].



**Figure 2.** The 22-year-old patient shows bilateral protrusion of the globes with respect to the orbit.

In conclusion, the present case is unusual in many respects. There was a heavy parasitic load in brain and surrounding soft tissues. Ocular tissues, including extraocular muscles are heavily infested with the cysticercus larvae. He did not have any eye symptom, except proptosis till he had another episode of acute encephalopathy. At this time, the patient succumbed to his illness.

### Conflict of interest statement

The authors declare that they have no conflict of interest.

### References

- [1] Wender JD, Rathinam SR, Shaw RE, Cunningham ET Jr. Intraocular cysticercosis: Case series and comprehensive review of the literature. *Ocul Immunol Inflamm* 2011; **19**: 240-245.
- [2] Lim WK, Chee SP. Nonsurgical management of subretinal cysticercosis. *Retina* 2004; **24**(3): 469-471.
- [3] Rath S, Honavar SG, Naik M, Anand R, Agarwal B, Krishnaiah S, et al. Orbital cysticercosis: Clinical manifestations, diagnosis, management, and outcome. *Ophthalmology* 2010; **117**: 600-605.
- [4] Ganesh SK, Priyanka. Analysis of clinical profile, investigation, and management of ocular cysticercosis seen at a tertiary referral centre. *Ocul Immunol Inflamm* 2018; **26**: 550-557.
- [5] Babalola O, Adu A, Akano A. Ocular cysticercosis in a 32-year-old man in Abuja: Ultrasonic features as an aid in diagnosis. *Clin Ophthalmol* 2013; **7**: 2275-2279.
- [6] Qavi A, Garg RK, Malhotra HS, et al. Disseminated cysticercosis: Clinical spectrum, toll-like receptor-4 gene polymorphisms and role of albendazole: A prospective follow-up of 60 cases with a review of 56 published cases. *Medicine (Baltimore)* 2016; **95**: e4882.
- [7] Del Brutto OH, Campos X. Massive neurocysticercosis: Encephalitic versus non-encephalitic. *Am J Trop Med Hyg* 2012; **87**: 381.
- [8] Jain RS, Kumar S, Bhana I, Agarwal R. Ocular cysticercosis with vitreous hemorrhage: A rare complication of a common disease. *Springerplus* 2015; **4**: 217.
- [9] Kasundra GM, Bhargava AN, Bhushan B, Khichar S, Sood I. Disseminated neurocysticercosis presenting as isolated acute monocular painless vision loss. *J Neurosci Rural Pract* 2014; **5**(Suppl 1): S89- S92.
- [10] Sundar U, Chawla V, Lakkas Y, Shrivastava M, Asole D, Vaidy M. Monocular blindness during therapy for cerebral neurocysticercosis. *J Assoc Physicians India* 2010; **58**: 570-572.
- [11] Malhotra R, Garg P, Mishra R, Khanduri S. Orbital cysticercosis: Masquerading as orbital inflammatory disorder. *Trop Doct* 2011; **41**: 119-120.