

*Case Report***Composite Lymphoma-A Rare Tumour with Uncommon Components**Dr. S. Brindha¹, Dr. S. Sowmya²¹Final year postgraduate, ²Professor,

Department of Pathology, Sri Manakula Vinayagar Medical College and Hospital, Puducherry -605 107

Corresponding Author: Dr. S. Brindha

ABSTRACT

Composite lymphoma is the presence of different morphological types of lymphoma in a single lymph node at the time of clinical presentation. It is a rare lymphoid neoplasm, presenting in lymphoid tissue. This paper is presenting a rare case of follicular dendritic cell sarcoma with diffuse large B cell lymphoma in a cervical lymph node.

Key words:**INTRODUCTION**

Composite lymphoma is the occurrence of two different and well delineated varieties of lymphoma in a single anatomic site or mass. [1] It has to be distinguished with discordant lymphoma where there is occurrence of two different types of lymphoma at separate anatomic sites. Some of the combinations may represent the occurrence of two unrelated neoplasms, either spontaneously or as a result of therapy given for one of them. The majority are probably the result of different biologic and morphologic manifestations of the same lesion, the more malignant one representing the morphologic expression of tumour progression. [2] The most important manifestations of this phenomenon: Low-grade B cell lymphoma (small lymphocytic, follicular or T- cell rich B cell lymphoma) that transforms into a diffuse large B-cell lymphoma. Transformation of mantle cell lymphoma into a higher- grade tumour. Low- grade T- cell lymphoma (mycosis fungoides) that transforms into a large T-cell lymphoma. Combination of “classic”

Hodgkin lymphoma and large B- cell lymphoma. [1,2] We present a case of follicular dendritic cell sarcoma with diffuse large B cell lymphoma in a cervical lymph node.

CASE REPORT

A 55 year old male came with swelling in the right side of the neck for 2 months. On examination there was no organomegaly and no other group of lymph node was involved. Peripheral smear and bone marrow studies were normal. Macroscopy reveals three soft tissue masses largest measuring 3*2*1.5 cm and two small masses measuring 0.5 c. External surface was congested. Cut surface showed grey white homogenous areas. On microscopy, sections showed lymph node with complete effacement of architecture by tumour with thickened capsule. Tumour composed of oval to spindle cells in fascicles and whorls with indistinct cell borders, moderate eosinophilic cytoplasm, vesicular nuclei and prominent nucleoli (Figure 1). Numerous mononuclear and

multinucleated RS like giant cells were seen. Numerous mature small lymphocytes were seen scattered around the tumour cells. The mitotic activity was 1-2/ 10 HPF within the spindle cells (Figure 2). Many of the vessels had concentric perivascular fibrosis. In some sections tumour was composed of large atypical cells and histiocytes in sinuses with capsular infiltration (Figure 3). Immunohistochemistry was done. CD 45 was positive in the reactive lymphocytes and the large atypical cells and negative in the spindle cells. CD 20 was positive in some of the reactive lymphocytes and diffusely in the large atypical cells. CD 15 and CD 30 were negative in the giant cells. S 100 was positive in the spindle cells. Cytokeratin, EMA and vimentin were negative. The diagnosis was Composite lymphoma (Follicular dendritic cell sarcoma in the background of castleman's disease with Diffuse Large B- cell Lymphoma).

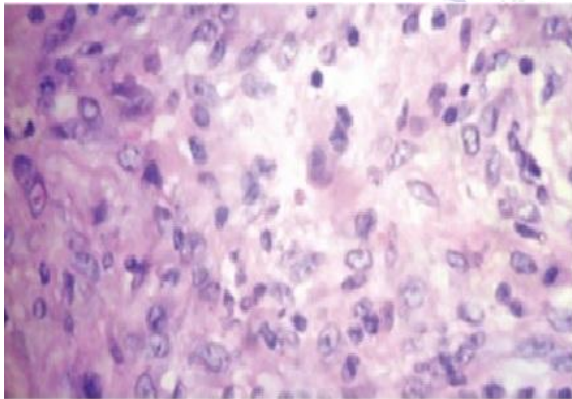


Figure 1: Oval to spindle cells with RS like Giant cells (H E , 40x).

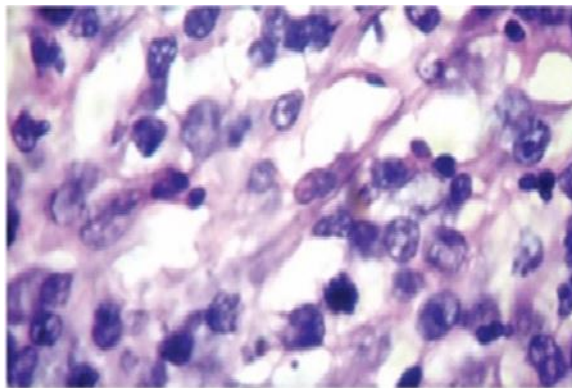


Figure 2: Atypical cells with mitotic activity seen in Diffuse large B cell lymphoma area. (H &E, 40x).

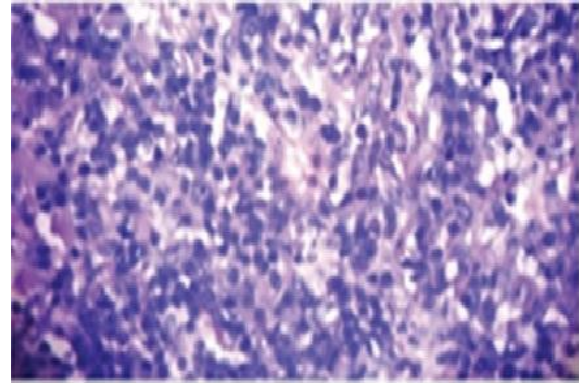


Figure 3: Lymphoid cells in arranged in diffuse sheets having coarse chromatin and basophilic nucleolus.(H &E, 40x).

DISCUSSION

Composite lymphoma was first defined by Cutler and later modified definition was given by Hicks et al., and Kim et al., as the presence of two distinct architectural and cytological subtypes of lymphoma occurring in the same anatomic site or tissue i.e. biphasic expression of the same neoplastic clone. [1,2] It is different from discordant lymphoma, where two different types of lymphoma occurred at separate anatomic sites at the time of presentation and also from sequential lymphoma in which two different histological types of lymphoma occur in the same group of lymph nodes following one another. [3]

The majority of composite lymphoma represents two forms of Non-Hodgkin's lymphoma (NHL). The rare association is the presence of Hodgkin's and NHL in the same lymph node. From the literature, it seems that the histological progression in B- lineage lymphoma is most commonly seen in patients whose initial biopsies show features of low grade lymphoma. [3,4] The incidence of progression in pattern or cell type in follicular lymphoma is different. The management of this lymphoma depends on histology of the high grade component. [4]

In this case, follicular dendritic cell sarcoma with DLBCL, the latter represents histologic transformation with both components carrying the same clone. Follicular dendritic cell sarcoma also known as dendritic reticulum cell sarcoma often

presents as a solitary mass in a cervical lymph node. It can involve other lymph node groups and extranodal sites including stomach, small bowel, large bowel, omentum, mesentery, liver, oral cavity, nasopharynx, tonsil, soft tissues of head and neck, mediastinum, spleen, lung. [3-5]

Some cases have occurred as a complication of the hyaline vascular type of castleman disease and others in connection with inflammatory pseudotumour of the liver, two conditions characterized by proliferation of follicular dendritic cells. [4,5] Follicular dendritic cell sarcoma can be distinguished from other spindle cell lesions like metastatic sarcoma / spindle cell carcinoma by immunohistochemistry. [5]

Diffuse large B- cell lymphoma is the most complex and heterogenous of all the Non- Hodgkin lymphoma. It occurs both in children and adults, but mostly in the latter. [5,6] In comparison with other types of lymphoma, it has greater tendency for extranodal presentation. It constitutes a high percentage of aggressive lymphoma. [6] The progression is rapid and prognosis is poor if untreated. [4,6]

The occurrence of Follicular dendritic cell sarcoma and Diffuse large B- cell lymphoma is one of the forms of composite lymphoma. [6]

CONCLUSION

Composite lymphoma is not common and it needs meticulous examination of the lymph node or lymphoid tissue to avoid missing the diagnosis. With the use of immunophenotypic, cytogenetics and molecular analysis, it is possible to diagnosis two types of lymphoma that are intermingled. The immunophenotypic findings in composite lymphoma are those

of the lymphoma types involved. These immunophenotypic variation emphasize that molecular analysis of each component is required to assess their clonal relationship. The therapy of composite lymphoma is towards the high grade component in its histology.

REFERENCES

1. Kim H, Hendrickson R, Dorfman RF. Composite lymphoma. *Cancer* 1977; 40(3): 959- 976
2. Fend F, Quintanilla-Martinez L, Kumar S, Beaty MW, Blum L, Sorbara L, Jaffe ES, Raffeld M. Composite low grade B- cell lymphomas with two immunophenotypically distinct cell populations are true biclonal lymphomas. A molecular analysis using laser capture microdissection. *Am J Pathol* 1999; 154(6): 1857-1866.
3. Warnke RA, Lawrence M, Weiss MD, Shon, KC, Chan, Micheal L, Dorfman C, Dorfman RF. Atlas of Tumor Pathology, Tumors of Lymph Nodes and Spleen. 3rd series. AFIP, 1995. 329.
4. Huang Q, Wilczynski SP, Chang KL, Weiss LM. Composite recurrent Hodgkin's lymphoma and diffuse large B-cell lymphoma: one clone, two faces. *Am J Clin Pathol* 2006; 126(2): 222-229.
5. Gonzalez CL, Medeiros LJ, Jaffe ES. Composite lymphoma. A clinicopathologic analysis of nine patients with Hodgkin's disease and B- cell non-Hodgkin's lymphoma. *Am J Clin Pathol* 1991; 96(1): 81-89.
6. CUSTER RP. Pitfalls in the diagnosis of lymphoma and leukemia from the pathologist's point of view. Proceedings of the Second National Cancer Conference. New York: American Cancer Society, 1954. 554-557.

How to cite this article: Brindha S, Sowmya S. Composite lymphoma-a rare tumour with uncommon components. *International Journal of Research and Review*. 2017; 4(2):26-28.
