

Functional rehabilitation of hemisected mandibular molar: A case report

Abhijeet Buragohain^{1*}, Abhishek Nagpal², Vishwas Bhatia³, Harchintan Kaur⁴

¹Post Graduate Student, ²Ex-Professor, ³Professor, ⁴Post Graduate Student, Dept. of Prosthodontics, ITS Dental College, Hospital & Research Centre, Greater Noida, Uttar Pradesh, India

***Corresponding Author: Abhijeet Buragohain**

Email: drabhijeet10@gmail.com

Abstract

The progressing inflammatory periodontal disease, if left untreated, results in attachment loss. This can also affect the bifurcation or trifurcation of a multirooted teeth. Thus, the treatment and long-term retention of mandibular molar teeth exhibiting furcation involvement has always been a key challenge, especially when there is furcation involvement progressed to a class II furcation. Hemisection denotes the removal of compromised root and its associated crown portion with the loss of periodontal attachment and to maintain the original tooth structure to attain the fixed prosthesis. This case report demonstrates the successful management of hemisection of 36 with occlusal rehabilitation and it was aimed to follow a conservative treatment approach to retain as much as original tooth structure possible against the conventional option of extracting the natural tooth.

Keywords: Endodontic-periodontal lesion, Furcation invasion, Class II furcation, Fixed partial denture, Prosthetic rehabilitation.

Introduction

Recent advancements in dentistry provides opportunity for the patients to maintain its functional dentition for lifetime period. Hemisection denotes the surgical separation of multi-rooted tooth, especially mandibular molar, through the furcation is in such a way that the root and its associated portion of the crown might be removed off or the roots being restored as individual crown. Once the tooth structure has been clinically judged, it must therefore undergo endodontic therapy first and then for its complete crown coverage. Selected root removal allows the access for the proper plaque control along with its resultant bone formation and the reduced pocket depth. The treatment thus includes endodontic therapy, periodontal therapy, tooth reconstruction and as well as prosthetic therapy such that the teeth are retained in whole or in its part for longer time period.¹ Continued periodontal breakdown leads to total tooth loss until and unless these defects are being repaired or eliminated and thus health of the tissues being restored. By post treatment approaches, these teeth can be used as an individual unit or as an abutment to fix a prosthesis which can restore its masticatory efficiency as well.² Thus, a conservative approach preserves the tooth structure as much as possible and therefore retains at least a part of the tooth rather being getting extracted as a whole.

Case Report

A 40-year-old male patient came to the department of Prosthodontics and Oral Implantology with a chief complaint of loose tooth and pain in his left lower back tooth region from last 2 months. Pain was dull and irregular in nature, which aggravated during mastication. Patient did not give any previous medical and dental history. While on extra oral examination, no abnormality was detected. During intraoral examination, it was found that the patient had a fair oral hygiene and on probing the lower left mandibular first molar, periodontal pocket of 6-8mm was found on its buccal and distal surfaces along with grade II furcation (Fig. 1).

The tooth was tender on percussion and was grade I mobile. IOPA revealed grade II furcation defect with loss of periodontal bone along with the distal root as compared to mesial root and periapical reduction within both the roots. The periodontal support of mesial root of 36 was good and the interproximal bone loss was observed between 36 and 37 (Fig. 2). It was finally diagnosed as chronic generalized gingivitis along with localized periodontitis in left lower mandibular first molar. The treatment included extraction of 36 following by placement of removable partial denture, fixed partial denture or implant but as the patient was unwilling to get the tooth extracted, a conservative approach was carried out which included the hemisection of distal root of 36 followed by its prosthetic coverage.

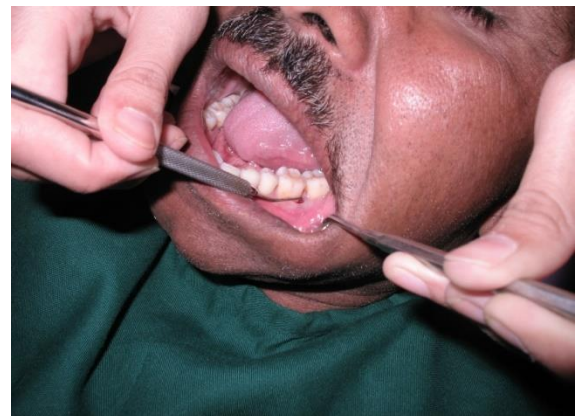

Fig. 1: Pre-operative view

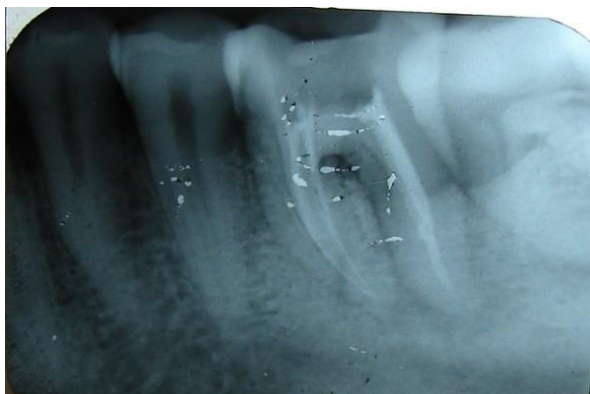


Fig. 2: Pre-operative radiograph

Treatment Procedures

Endodontic Phase

Intentional root canal treatment of 36 was done (Fig. 2). After 14 days of obturation, hemisection procedure was carried out.

Periodontic Phase

After application of local anesthesia, crevicular incision was made from second premolar region to second molar region. Full thickness mucoperiosteal flap was raised to provide access for proper visualization, instrumentation and minimal surgery (Fig. 3). After opening of the flap, both curettage and debridement was done. Long shank tapered fissure carbide bur was used to make a vertical cut facio-lingually towards bifurcation area and the mesial root was extracted (Fig. 4). Intensive care was taken not to modify the bone and its adjacent tooth while removing the mesial portion of the root. Irrigation of the socket was done. Odontoplasty was done to remove the developmental ridges while mesial aspect of the distal root was contoured for facilitating oral hygiene measures (Fig. 5). Socket preservation was done by grafting at the site of extraction with "Bio-Oss." The sutures were placed and COE pack dressing was done. The surgical site was allowed to heal with no occlusal stress on the distal root aspect for at least 4 weeks. Patient was then recalled after 3 months and IOPA revealed good bone translation (Fig. 6). After that restoration of the hemisected tooth was planned for fixed partial denture with respect to 35, mesial root of 36 and 37.

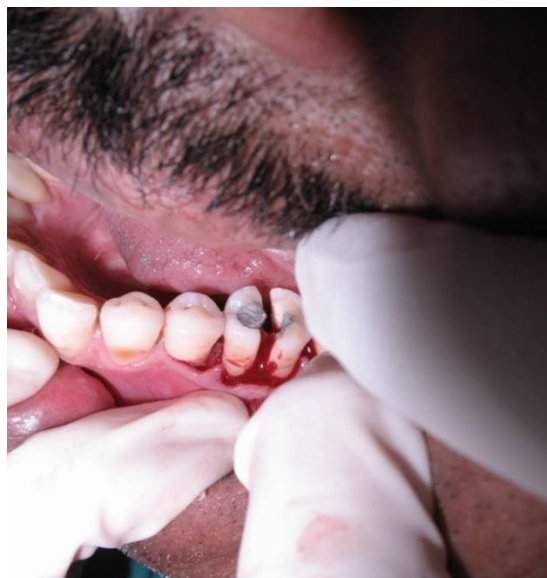

Fig. 4: Sectioned mandibular molar

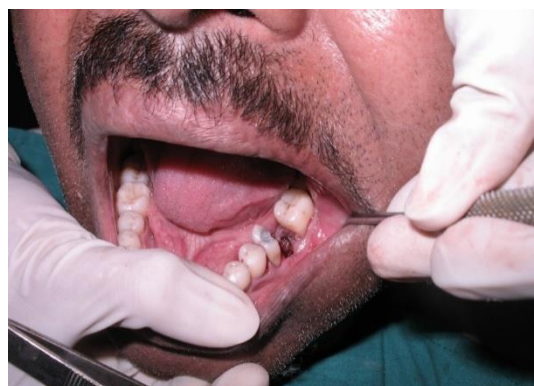

Fig. 5: Post-operative view

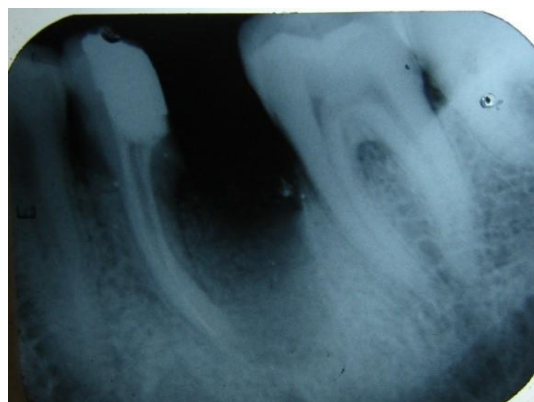


Fig. 6: Post-surgical radiograph

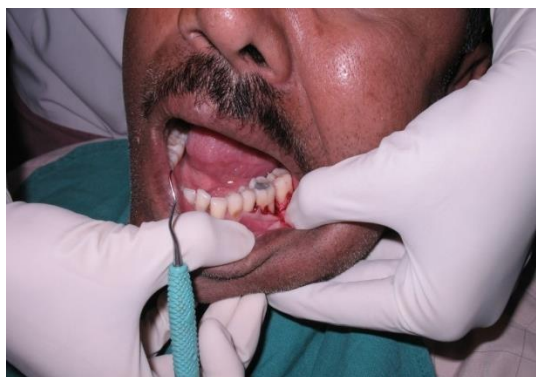

Fig. 3: Mucoperiosteal flap raised

Prosthetic Phase (Fig. 7)

Primary impression was made with irreversible hydrocolloid impression material and the casts were obtained. Face bow record was done and transferred to semi-adjustable articulator and the maxillary cast was mounted on it. The mandibular diagnostic cast was mounted using interocclusal record to check any kind of occlusal immaturities and necessary occlusal corrections were carried out. The tooth

preparation was done in respect to 35, distal part root of 36 and 37 (Fig. 8). Margin on the distal aspect of 37 was placed approximately 3-4mm above gingival margin as the tooth structure was mesially tilted. The final impression was made by using putty-reline technique and the master cast was obtained (Fig. 9). Provisional restoration was fabricated and then placed (Fig. 10). The mandibular master cast was then mounted using interocclusal record. The wax patterns were fabricated, sprued and invested (Fig. 11). Casting procedures were carried out and metal framework was tried out in the patient's mouth followed by the ceramic build up and bisque try in (Fig. 12). The final prosthesis was cemented by using luting glass ionomer cement (Fig. 13). Post cementation instructions regarding its maintenance was told and periodically recall was done to persuade the healing and success of the restoration as well (Fig. 14).

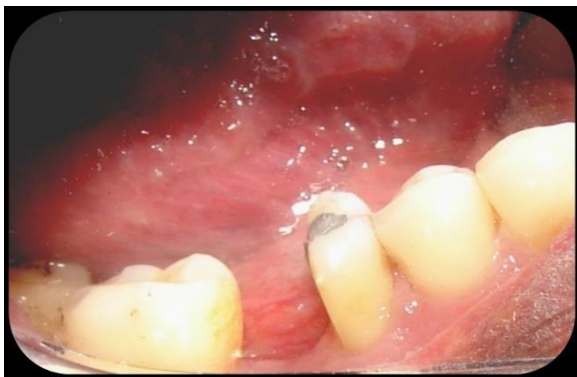

Fig. 7: Prosthodontic restoration of hemisected mandibular molar

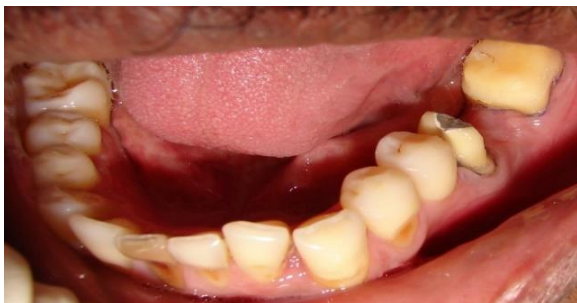

Fig. 8: Tooth Preparation

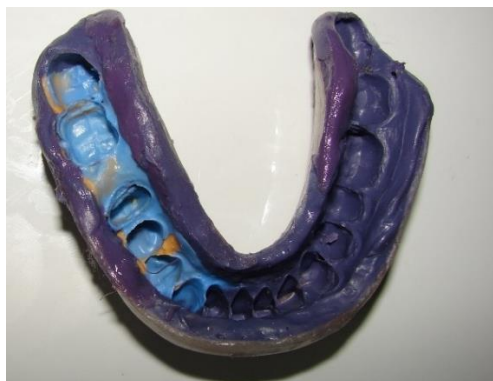

Fig. 9: Final Impression

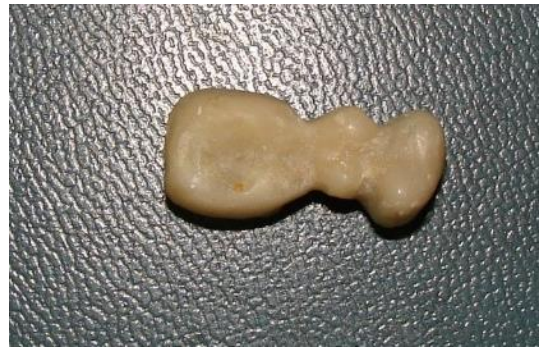

Fig. 10: Provisional Restoration

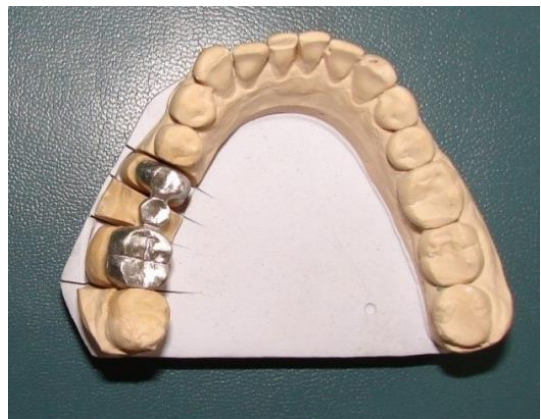


Fig. 11: Casting procedures

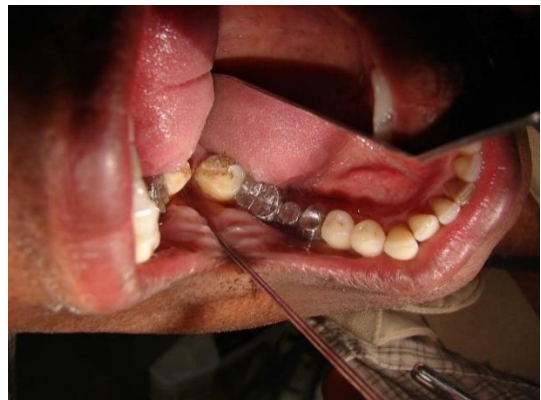

Fig. 12: Metal Coping Try-In

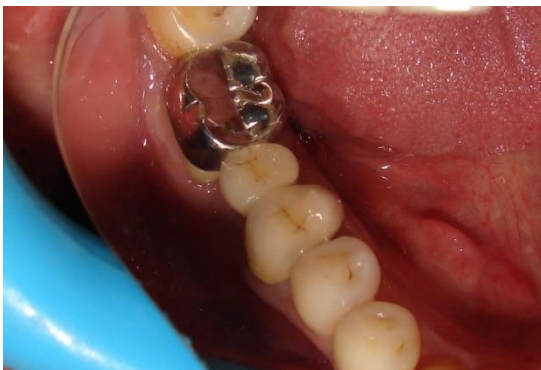

Fig. 13: Cementation of Prosthesis

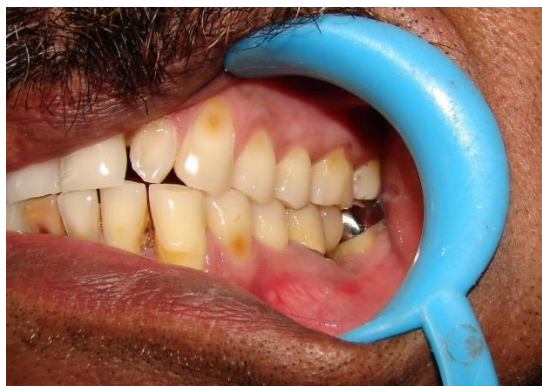

Fig. 14: Post-operative view

Discussion

Proper assessment for appropriate selection of cases is important. Buhler stated that the hemisection procedure should be treated before every molar extraction,³ as it provides a good biological alternative with long term period. Various treatment options for replacing severely damaged and unrestorable teeth includes of removable partial denture, fixed partial denture and dental implant. Thus, the use of hemisection offers a better prognosis equivalent to any other tooth.

Endodontic Phase

Endodontic procedure was first carried out because if in case, the tooth cannot be treated endodontically or if there is an endodontic breakdown, the case will be contraindicated for hemisection.

Periodontic Phase

Three critical factors for selecting molar as hemisection⁴–

1. Root Divergence. Ideally the resected root should have good root divergence, otherwise the root proximity would make it difficult for surgery.
2. Root Form. Roots of mandibular molars display concavity, mostly on the distal root portion. Therefore, odontoplasty should be performed for proper contour.
3. Location of Furcation. Closer the furcation opening towards cemento-enamel junction, better is the prognosis for the retained root.

Prosthodontic Phase

When tooth loses part of its root support, it requires a restoration to permit for functioning independently or to serve as an abutment for fixed partial denture. Thus, restoration is required for proper functioning and stabilization of occlusion. The points to consider while fabricating the prosthesis: Hemisected abutment should be given a taper of greater than 6–10 degree in order to gain path of insertion compatible with anterior abutment and for compensating the buccal and lingual grooves placed in the abutment.⁵ The cuspal inclines are made less steeper in order to reduce forces directed laterally and thereby eliminating the nonworking contacts. Stein stated that “while permitting esthetic, sanitary pontic is the best design for posterior most region”.⁶ Implant therapy is an expected option with good functionality.⁷ In this case, the patient chose an alternative treatment option because of his desire and financial deliberation. Thus, hemisection allows for

physiologic tooth mobility of the remaining root which is more of a suitable abutment for the fixed partial denture rather than an Osseo integrated counterpart.⁸

Conclusion

This case report displays the treatment of a periodontally compromised tooth structure by its multidisciplinary treatment approach. Selection of proper prosthesis type for root amputated molar depends on various factors such as condition of the adjacent teeth and its biomechanical considerations.⁹ Success of the tooth with hemisection depends on its supporting bone, restorative treatment plan and oral hygiene care of the patient. Proper periodontal maintenance and satisfactory coronal restoration of root resected teeth are important aspects for long term survival rate.¹⁰ Thus, hemisection is an important treatment option in the field of dentistry to help in increase the desire to retain natural teeth.

Conflict of Interest: None.

References

1. Parmar G, Vashi P. Hemisection: a case-report and review. *Endodontol* 2003;15:26-9.
2. Kost WJ, Stakiw JE. Root amputation and hemisection. *J Can Dent Assoc* 1991;57:42-5.
3. Rosenstiel SF, Land MF, Fujimoto J. Contemporary fixed prosthodontics. 2nd ed. St. Louis: Mosby Year Book, Inc.; 1995.
4. Bashutski JD, Wang HL. Common implant esthetic complications. *Implant Dent* 2007;6:340-8.
5. DeSanctis M, Murphy KG. The role of respective periodontal surgery in the treatment of furcation defects. *Periodontol* 2000;22:154-68.
6. Schmitt MS, Brown HF. The hemisected mandibular molar. A strategic abutment. *J Prosthetic Dent* 1987;58:140-4.
7. Saad MN, Moreno J, Crawford C. Hemisection as an alternative treatment for decayed multirooted terminal abutment: A Case Report. *J Can Dent Assoc* 2009;75:387-90.
8. Radke U, Kubde R, Paldiwal A. Hemisection: A window of hope for freezing tooth. *Case Rep Dent* 2012;2012:390874.
9. Shah S, Modi B, Desai K, Duseja S. Hemisection – A conservative approach for a periodontally compromised tooth – A case report. *J Adv Oral Res* 2012;3:31-5.
10. Akki S, Mahoorkar S. Tooth hemisection and restoration an alternative to extraction-A case report. *Int J Dent Clin* 2011;3:67-8.

How to cite the article: Buragohain A, Nagpal A, Bhatia V, Kaur H. Functional rehabilitation of hemisected mandibular molar: A case report. *J Dent Specialities* 2019;7(1):38-41.