

## Comparative evaluation of the efficacy of diode laser and cryosurgery (Using 1,1,1,2 tetrafluoroethane) for the treatment of gingival pigmentation

Lakita Gulati<sup>1,\*</sup>, Prerna Mohan<sup>2</sup>, Rahul Chopra<sup>3</sup>, Nikhil Sharma<sup>4</sup>, Trishu Chowdhery<sup>5</sup>, Vinita Dahiya<sup>6</sup>

<sup>1,2,5,6</sup>Post Graduate Student, <sup>3</sup>Associate Professor, <sup>4</sup>HOD, Dept. of Periodontology and Oral Implantology, I.T.S Centre for Dental Studies and Research, Muradnagar, Ghaziabad, Uttar Pradesh, India

**\*Corresponding Author:**

Email: lakitagulati\_mds18\_21@its.edu.in

### Abstract

**Introduction:** Cosmetic expectations have increased with time and pigmentation of gingiva is a negative factor in an otherwise acceptable “smile window”. Amongst the various treatment modalities for depigmentation like scalpel technique, cryosurgery, laser, abrasion etc, there seems to be a need to compare efficacy of cryosurgery with TFE and Diode laser.

**Objective:** The objective was to compare the efficacy of cryosurgery with 1,1,1,2 tetrafluoroethane and Diode Laser for the treatment of gingival pigmentation.

**Materials and Methods:** A randomized controlled split mouth study was conducted for 10 patients with gingival pigmentation, wherein one quadrant was treated with the TFE cooled swab( Group A) and the other quadrant was treated using diode laser (980nm at 1W) (Group B). Pre and post treatment photographs, VAS pain scores, were evaluated by the clinician at 4 days, 1 week, 1month and also number of analgesics required to be taken by the patient following treatment with both the techniques.

**Results:** Clinically significant results were seen in both the groups. Mild erythema was seen immediately after the application of cryogen following which a whitish slough could be separated from the underlying connective tissue at fourth day. In group B, a white fibrin slough was seen 24hrs after the procedure. The healing was uneventful and complete epithelialization takes place in 3-4 weeks in both the groups. Though, the patient acceptance was good for both the procedures, mild pain and discomfort was experienced by the patient in group B.

**Conclusion:** Depigmentation of gingival melanin hyperpigmentation by cryosurgery using TFE and diode laser were found to be an effective procedures, however the patient compliance and acceptance was greater in Tetrafluoroethane cryosurgery when compared to the Diode laser.

**Keywords:** Cryosurgery, Laser, Depigmentation, Tetrafluoroethane.

### Introduction

‘Beauty is a power and smile is its sword’. A good smile is like an instant facelift and an instant mood enhancer. The need of an hour is to get an attractive smile as “A smile is a curve that sets everything straight”. Gingival health and color has an important role in the maintenance of the harmony of a smile and can also act as a negative factor in an otherwise acceptable smile window.

Gingival hyperpigmentation is seen as an inherited peculiarity in some populations, and can be referred more aptly as a racial or physiologic pigmentation. Racial predilection of oral melanin pigmentation is normally observed in individuals of African, East-Asian or Hispanic ethnicity.<sup>1</sup>

Several exogenous and endogenous factors are associated with gingival pigmentation. Various etiological factors responsible for oral pigmentation include heavy metals, genetics, drugs, inflammation, endocrine disturbances.

Melanin pigmentation is caused by a melanin pigment which is a non-haemoglobin derived pigment. It is caused by melanin granules in gingival tissue, which are produced in melanosomes of melanocytes. Melanocytes are located primarily in the basal and suprabasal cell layers of the epithelium. Also, smoking may stimulate melanin production and cause melanin pigmentation. The frequency and duration of smoking

affects the intensity of pigmentation (Hedin et al. 1991).<sup>2,3</sup>

Ginwalla et al. (1966)<sup>4</sup> described the black zone of pigmentation on the gingiva as “unsightly” and suggested its removal for improved esthetics. Dummett (1969)<sup>5</sup> conducted a survey to explore person’s attitude towards gingival pigmentation and concluded that “pink gum” is the ideal one.

Various treatment modalities aimed at removing and masking the pigmented layer include bur abrasion, scalpel surgical technique, cryosurgery, electrosurgery, lasers, and chemical methods of de-pigmentation and free gingival grafts, acellular dermal matrix allograft respectively.<sup>6</sup>

Laser surgery has been widely used as a preferred treatment of choice over conventional scalpel technique as it causes less discomfort to the patient, does not require suture or periodontal dressing and also improves hemostasis.<sup>7</sup>

Cryosurgery, though is an efficient method, yet it is not used commonly because of its high equipment cost and the safety regarding storage of liquid gases.

Hence, a new material 1,1,1,2 tetrafluoroethane (TFE) has been used in this study. It is colourless, non-inflammable gas, used as a coolant in electronic circuits and refrigerating systems and is biocompatible. Several human and animal toxicology studies have proven this material to be biocompatible showing no oncogenic or

genotoxic effect on animals.<sup>8,9</sup> It is commercially available as a pressurized spray can with a melting point of  $-101^{\circ}\text{C}$  and a boiling point of  $-26^{\circ}\text{C}$  and evaporate immediately without leaving residue following spraying.<sup>10</sup>

Thus the present study is conducted with an objective to compare the efficacy of diode laser and cryosurgery with TFE for the treatment of gingival pigmentation.

### Materials and Methods

A randomized controlled split mouth study was conducted on ten patients presenting with gingival hyper pigmentation with age ranging between 18 to 60 years. Patients were selected from the Outpatient clinic of the Department of Periodontology and Oral Implantology, I.T.S Centre for Dental Studies and Research, Muradnagar, Ghaziabad, U.P. Patients presenting with moderate to severe melanin hyperpigmentation of the gingiva as given by

Dummett<sup>5</sup> and a good oral hygiene and aesthetic concerns were included in this study. Pregnant and lactating women, chronic smokers and subjects with systemic disease were excluded from the study.

After taking the written informed consent from the patients fulfilling the inclusion criteria, depigmentation procedure was performed using diode laser in one quadrant and cryosurgery with TFE in other quadrant which was selected with a toss of coin. Both the surgical procedures were performed by single operator.

The visual analogue score (VAS)<sup>11</sup> for pain was recorded immediately and at 4<sup>th</sup> day postoperatively by asking the patient to mark on a line having scores 0-10. Also, wound healing following for both the procedures was recorded using the wound healing index by Landry et al<sup>12</sup> by another examiner who was blinded for the treatment done at 4<sup>th</sup> day, 7<sup>th</sup> day and one month after the procedure. (Table 1)

**Table 1: Healing index (Landry et al)**

Healing Index	Tissue color	Bleeding on palpation	Granulation tissue	Incision margin	Suppuration
1- Very poor : 2 or more signs are present	$\geq 50\%$ of red gingiva	Yes	Yes	Not epithelialized, with loss of epithelium beyond incision margin	Yes
2- Poor	$\geq 50\%$ of red gingiva	Yes	Yes	Not epithelialized, with exposed connective tissue	No
3- Good	25-50% of red gingiva	No	No	No exposed connective tissue	No
4- Very good	$< 25\%$ of red gingiva	No	No	No exposed connective tissue	No
5- Excellent	All pink tissues	No	No	No exposed connective tissue	No

### Group A (Laser)

The pigmented area to be treated was anaesthetised by the topical application of 2% lignocaine hydrochloride. The diode laser of wavelength 980nm was operated at 1W for the procedure. The fibre optic tip was kept in a continuous contact mode with the pigmented area and was moved in a light brushing stroke starting from the mucogingival junction working towards the free gingival margin, including the papillae. The ablated tissue remnants were removed by the gauze soaked in saline. The procedure was repeated till the desired result had been achieved. Neither the periodontal dressing was placed, nor the antibiotics were prescribed. The patient was prescribed Paracetamol tablet SOS and Evion for the topical application 3-4 times a day for 5 days. The patients were then examined at 3 subsequent visits, i.e, after 4 days, 7 days and 1 month. (Fig. 1)

### Group B (Cryosurgery (using 1,1,1,2 tetrafluoroethane))

Topical anaesthesia with 2% lignocaine spray was applied following which the pigmented area to be treated was isolated and air dried. The cotton swab of appropriate size was sprayed with 1,1,1,2-Tetrafluoroethane and was immediately rolled gently over the pigmented area maintaining a freezing zone continuously in each area for about 30-40s. The patients were examined at 4<sup>th</sup> day, 7<sup>th</sup> day and 1 month postoperatively for healing and recurrence of pigmentation.

### Statistical Analysis

The results were statistically evaluated using SPSS Inc., (Released 2009 PASW Statistics for Windows, Version 18.0. Chicago). The power of the study was 90%, and a  $P < 0.05$  was considered statistically significant.

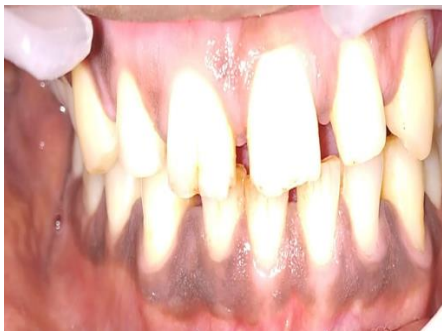## Results

Clinically significant results were seen in both the groups. Both TFE and 980nm diode laser effectively ablated the epithelial tissue exhibiting melanin pigmentation. Immediately after the procedure slight bleeding points were observed in Group A (Fig. 2) and mild erythema was seen in Group B. (Fig. 3) The mean VAS score for pain in both the groups A and B showed statistically significant findings (Graph 1). Patient experienced mild pain and discomfort in group A.

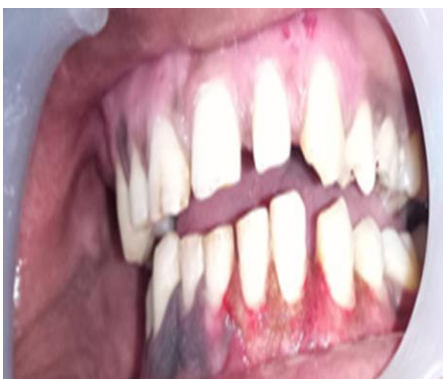There was no sign of recurrence on recall intervals. On 4th day, the area treated with diode laser appeared to be inflamed (Fig. 4) with some patients complaining of mild pain. In Group B, a whitish slough following superficial necrosis (Fig. 5) was apparent. The mean VAS score for pain in group A and in the group B at 4th day postoperatively (Graph 2) showed statistically significant result ( $P= 0.025$ ) with patient experiencing more pain following treatment with laser. However none of the patients complained of major discomfort during the procedure in both the groups.

At 1 week the gingiva irradiated with laser appeared reddish in color (Fig. 6) whereas the gingiva appeared normal within 1 week in Group B (Fig. 7).

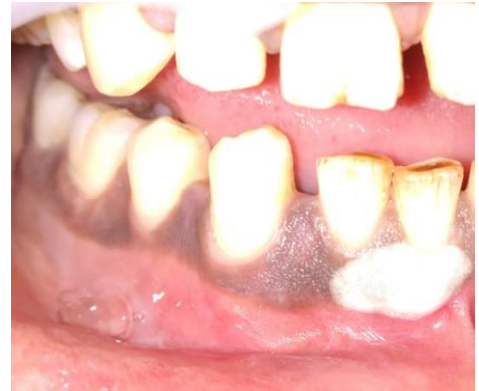At 1 month, complete healing was observed in both the cases with gingiva exhibiting normal appearance (Fig. 8 & 9). The wound healing was statistically significant (Graph 3) in both the groups with gingiva showing normal pink color. There were no signs of scar formation, haemorrhage or infection in both the cases. Patient acceptance was good for both the procedures.



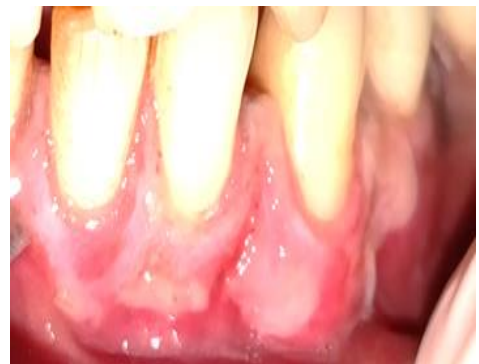**Fig. 1: Pre operative hyperpigmented gingiva**



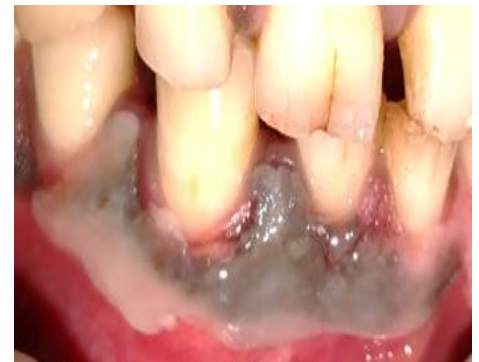**Fig. 2: Immediately post operative (Group A)**



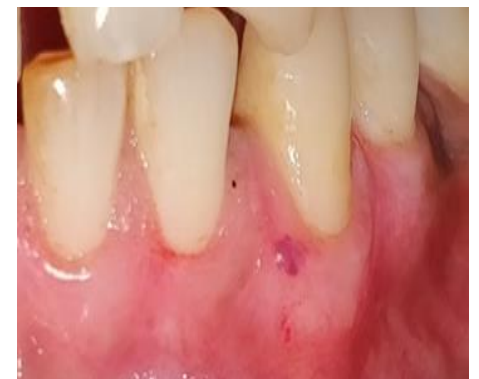**Fig. 3: Freezing zone being maintained for 30-4- sec in Group B**



**Fig. 4: 4 Days postoperative (Group A)**



**Fig. 5: 4 Days postoperative (Group B)**



**Fig. 6: 7 Days postoperative (Group A)**

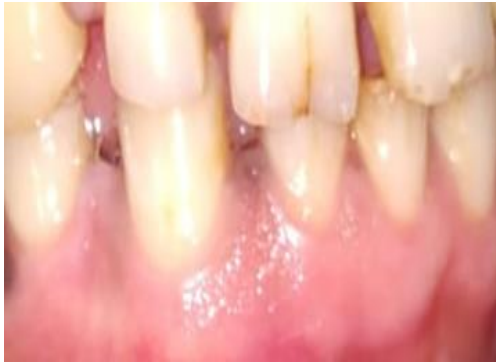

Fig. 7: 7 Days postoperative (Group B)

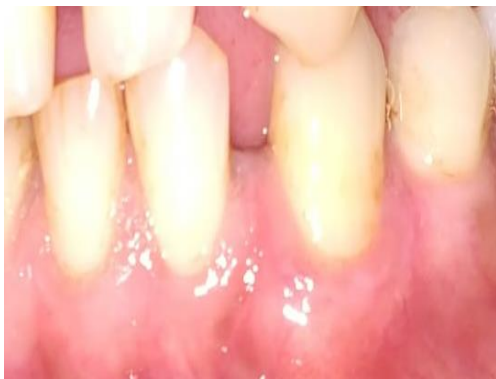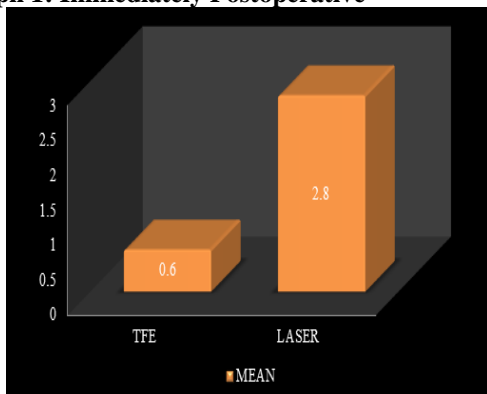


Fig. 8: 1 Month postoperative (Group A)

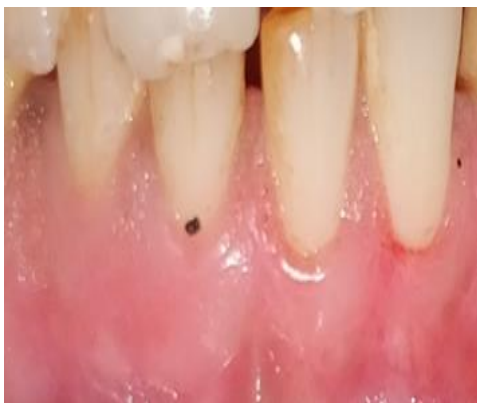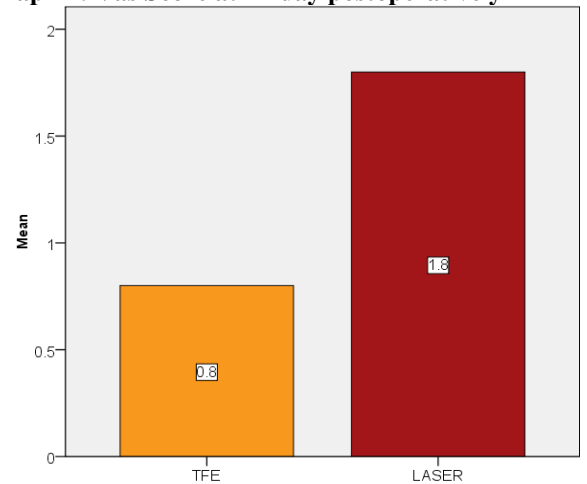


Fig. 9: 1 Month postoperative (Group B)

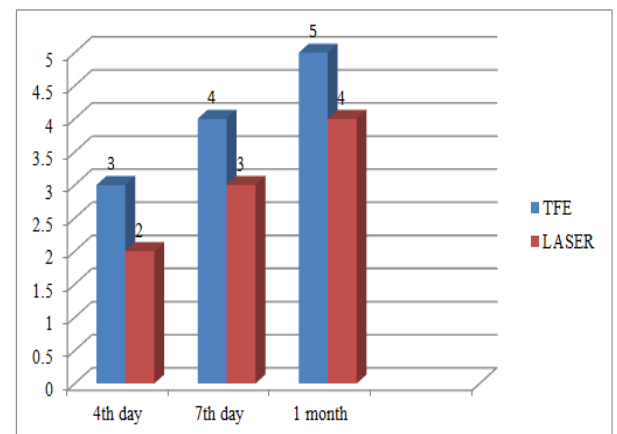
Graph 1: Immediately Postoperative



Graph 2: Vas Score at 4<sup>th</sup> day postoperatively



Graph 3: Wound healing index at 4<sup>th</sup> day, 7<sup>th</sup> day and 1 month



**Discussion**

Creating a beautiful smile is an intimate process. The harmonious integration of dental and gingival components in the facial composition is essential to get an esthetically pleasing smile curve. The increase in demand of optimal esthetics in dentistry has led to the use of various periodontal plastic and cosmetic procedures in daily practice. Melanin pigmentation poses the esthetic challenge to an otherwise acceptable personalized smile line.

The factors determining the color of gingiva include the depth of epithelization, intensity of melanogenesis, degree of epithelial cornification and the gingival vasculature.<sup>13</sup> Various depigmentation techniques have been documented like cryosurgery, bur abrasion, scalpel, laser therapy, electrosurgery and free gingival autografts. The technique should be selected carefully based on clinical experience and individual preferences.

Laser Therapy (Trelles et al.,<sup>14</sup>) and Cryosurgery (Tal Haim et al.,<sup>15</sup> Chin – Jyh Yeh<sup>16</sup>) are the recent advances being used for the various periodontal plastic procedures.

Though Laser ablation of the gingival pigmentation has been recognized as an effective, pleasant and reliable procedure, certain drawbacks of laser therapy includes thermal damage, delayed wound healing, deep penetration and the comparably high costs of the procedure.<sup>7</sup>

Studies by authors in which diode lasers were employed with a wavelength of 980nm, power of 2-4W, pulse intervals varying from 20 and 50 milliseconds no repigmentation was observed after 15 months and 1 year follow-ups.<sup>17</sup>

A wide range of oral and maxillofacial lesions has been treated with use of cryosurgery. The use of extremely cold solutions was first reported by Dr. James Arnott (1851) who has been considered as the pioneer of cryosurgery. He had used a mixture of sodium chloride and ice to treat tumors. He had noticed that cold temperatures have beneficial anti-inflammatory and analgesic effects<sup>18</sup>.

Cryosurgery with Tetrafluoroethane has an edge over conventional scalpel technique and laser<sup>19</sup> in terms of depth control (making use of time factor<sup>20</sup> of maintaining the cryogen for 30-40 sec at the site).

In the healing phase, immediately after the cryosurgery procedure slight erythema develops. A whitish slough following the superficial necrosis could be separated from underlying connective tissue after 3-4 days leaving behind a pink clean ulcer bed. Within 1 week, the gingiva appears normal. The healing was uneventful with epithelialization being completed within 3-4 weeks.

Immediately after removal of gingival pigmentation by laser, slight bleeding points were observed on the exposed gingival connective tissue. Twenty four hours after the procedure, a white fibrin slough was seen. The epithelialization of epithelium starts at about 1 week showing immature healing. Complete healing with tissue maturation was observed at 1 month, wherein the gingiva appears normal.

In the present study, comparable clinical results were found between both the groups. Patients experienced minimal pain following cryosurgery with TFE as compared to the laser. Hence, patient compliance was better following cryosurgery.

In the study conducted by Singh et al. (2013) comparing the efficacy of TFE and diode laser, it was found that cryosurgical approach by TFE was less painful, caused less discomfort and hence was more acceptable as compared to laser.<sup>21</sup>

In a case series done by Kumar S et al in 2013 with ten patients, comparing the efficacy of TFE and gingival abrasion technique for the treatment of gingival pigmentation, they found that there were no signs of repigmentation with TFE.<sup>22</sup>

Kumar et al in 2013 carried out a study (case series) with 5 patients. They study the effectiveness of the TFE for gingival depigmentation. It was concluded that TFE can be used safely and efficiently for

depigmentation procedures. It was found that TFE can destroy gingival epithelium effectively without causing any damage to the underlying connective tissue. Clinically, the results in respect to color, healing and longevity were more satisfactory.<sup>23</sup>

In the study conducted by Narayankar SD et al (2017) comparing the efficacy of TFE and surgical scalpel technique, it was found that cryosurgical approach by TFE was less painful, caused less discomfort and hence was more acceptable as compared to surgical scalpel technique.<sup>21</sup>

## Conclusion

Depigmentation of gingival melanin hyperpigmentation by cryosurgery using TFE and diode laser were found to be an effective procedures, however the patient compliance and acceptance was greater in Tetrafluoroethane cryosurgery when compared to the Diode laser.

**Conflict of Interest:** None.

## References

1. Tamizi M, Taheri M. Treatment of severe physiologic gingival pigmentation with free gingival autograft. *Quintessence Int* 1996;27:555-58.
2. Meleti M, Vescovi P, Mooi WJ, van der Waal I. Pigmented lesions of the oral mucosa and perioral tissues: a flow-chart for the diagnosis and some recommendations for the management. *Oral Surg Oral Med Oral Pathol Oral Radiol Endod* 2008;105:606-16.
3. Eisen D. Disorders of pigmentation in the oral cavity. *Clin Dermatol* 2000;18:579-87.
4. Ginwalla TM, Gomes BC, Varma BR. Surgical removal of gingival pigmentation. *J Indian Dent Assoc* 1966;38:147-50.
5. Dummett CO. A mental attitude towards oral pigmentation. *Oral Res Abstracts* 1969;4:932.
6. Roshna T, Nanda kumar K. Anterior esthetic gingival depigmentation and crown lengthening: Report of a case. *J Contemp Dent Pract* 2005;6:139-47
7. Charles M Cobb. Lasers in Periodontics: A review of the literature. *J Periodontol* 2006;77:545-64
8. Alexander DJ, Libretto SE, Chevalier HJ, Imamura T, Pappritz G, Wilson J. et al. HFA 134a(1,1,1,2-tetrafluoroethane); lack of oncogenicity in rodents after inhalation. *Hum Exptoxicol* 1995;14:706-14.
9. Alexander DJ, Libretto SE, Adams MJ, Hughes EW, Bannerman M. HFA-134a (1,1,1,2-tetrafluoroethane); effects of inhalation exposure upon reproductive performance, development and maturation of rats. *Hum Exp Toxicol* 1996;15:508-17.
10. Arian F, Gurkan A. Cryosurgical treatment of gingival melanin pigmentation with tetrafluoroethane. *Oral Surg Oral Med Oral Pathol Oral Radiol Endod* 2007;103:452-57.
11. Matthews DC, McCulloch CA. Evaluating patient perception as short term outcomes of periodontal treatment: A Comparison of surgical and non surgical therapy. *J Periodontol* 1993;64:990-97.
12. Landry RG, Turnbull RS, Howley T. Effectiveness of benzydamine HCL in the treatment of periodontal post-surgical patients. *Res clinic Forums* 1988;10:105-118

13. Bandish LK. Pertinent considerations in oral pigmentation. *Brit Dent J* 1985;5:158.
14. Trelles MA, W Verkruyesse, JM Segui, A Udeata. Treatment of melanotic spots in the gingiva by argon laser. *J Oral Maxillofac Surg* 1993;51(7):759-61.
15. Tal Haim, Landsberg Jacob, Kozlovsky Avital. Cryosurgical depigmentation of the gingiva - A case report. *J Clin Periodontol* 1987;14:614-17.
16. Chin-Jyh. Yeh. Cryosurgical treatment of melanin-pigmented gingiva. *Oral Surg Oral Med Oral Pathol Oral Radiol Endod* 1998;86(6):660-63
17. Gupta G. Management of Gingival Hyperpigmentation by Semiconductor. *J Cutan Aesthet Surg* 2011;4:208-210.
18. Leopard PJ, Poswillo DE. Practical cryosurgery for oral lesions. *Br Dent J* 1974;136:185-96.
19. Narayankar SD, Deshpande NC, Dave DH, Thakkar DJ. Comparative Evaluation of Gingival Depigmentation by Tetrafluoroethane Cryosurgery and Surgical Scalpel Technique. A Randomized Clinical Study. *Contemp Clin Dent* 2017.
20. Meyers PD, Gerald Tussing, Frank M Wentz. The histological reaction of clinically normal gingiva to freezing. *J Periodontol* 1971; 42(6): 346-52.
21. Vishal Singh, Subraya Bhat, Santhosh Kumar, Mahalinga Bhat. Comparative Evaluation of Gingival Depigmentation by Diode Laser and Cryosurgery Using Tetrafluoroethane: 18-Month Follow-Up. *Clinical Advances in Periodontics* 2012;2(3): 129-34.
22. Kumar S, Bhat GS, Bhat KM. Effectiveness of cryogen tetrafluoroethane on elimination of gingival epithelium and its clinical application in gingival depigmentation-histological findings and case series. *J Clin Diagn Res* 2013;7:3070-72.
23. Kumar M, Bandyopadhyay P, Kundu D, Mishra L. Cryosurgery by tetrafluoroethane: An answer to black gums. *J Indian Soc Periodontol* 2013 Mar;17(2):257-60.

**How to cite the article:** Gulati L, Mohan P, Chopra R, Sharma N, Chowdhery T, Dahiya V. Comparative evaluation of the efficacy of diode laser and cryosurgery (Using 1,1,1,2 tetrafluoroethane) for the treatment of gingival pigmentation. *J Dent Specialities* 2018;6(2):145-150.