

Original Article

Screening of hepatoprotective effect of methanolic extract of *Solanum nigrum* against paracetamol

Asma Mumtaz¹, Muhammad Zabta Ch^{2*} and Syed Nisar Hussain Shah^{1*}

¹Faculty of Pharmacy, Bahauddin Zakariya University, Multan Pakistan.

² Department of Biochemistry, Multan Medical and Dental College, Multan, Pakistan

Abstract

Received: Feb 2, 2015

Revised: May 27, 2015

Accepted: May 29, 2015

Online: June 01, 2015

Solanum nigrum (SN) commonly known as “Makoo” frequently available in most of the areas of Pakistan, is well reputed in the indigenous system of medicine for its medicinal use in liver disorders. The present study was aimed to evaluate its traditional use in liver diseases using in-vivo model of rabbits. The crude methanolic extract of the aerial parts of the *Solanumnigrum* (SN.CEA) was investigated for its hepatocurative and hepatoprotective activities in Paracetamol intoxicated (2g/Kg) rabbits. Rabbits were divided into three groups, normal control (saline treated) hepatotoxic control (Paracetamol treated) and remaining one was hepatotoxic treated with the SN.CEA (400 mg/kg) for 6-12 days. Similarly, for hepatoprotective effect rabbits were divided in 3 groups; one serving as control another as hepatotoxic and last one as treated with SN.CAE. Group 2nd and 3rd were intoxicated with Paracetamol at 6th day of the treatment with SN.CEA. Increased serum transaminases (sGOT and sGPT) and alkaline phosphatase (ALP) levels along with raised sleeping span and blood clotting time were observed in hepatotoxic rabbits. In both cases (hepatocuration and hepatoprotection) SN.CEA caused significantly reduction in all the above serum markers for liver functioning and caused significant reduction in the sleeping time of treated rabbits vs hepatotoxic untreated group. These data suggests that the presence of hepatocurative and hepatoprotective constituents in *Solanumnigrum* rationalizes its medicinal use in liver dysfunction.

Keywords: *Solanumnigrum* (SN), hepatocurative, hepatoprotective, hepatotoxic

Introduction:

From the time immemorial plants remained as main sources to counter the disease burden on mankind. Relatively these are the cheapest sources for the treatment of different diseases. Recent years emphasized an interest in plants as pharmaceuticals in the world. This interest is channeled into the discovery of new biologically-

active molecules by the pharmaceutical industry and into the adoption of crude extracts of plants for self-medication by the general public. Plants have an important role not only to maintain the health standards but also improve the life styles by reducing budget on disease cure and prevention (Houghton, 1955). The WHO estimated that 80% of the people in developing countries rely on traditional medicine for their primary health care needs, and about 85% of traditional medicine involves the use of plant extracts.

*Corresponding Author:

Muhammad Zabta Ch & Syed Nisar Hussain Shah
Faculty of Pharmacy, Bahauddin Zakariya University,
Multan Pakistan

e-ma: :drzabta@gmail.com, nisarhussain@bzu.edu.pk.

Ph: +92 61 9239322; 03226151040

Steps involved in selection, collection and drying of the plant materials: The medicinal value of botanical drugs depends to a large extent on the time of their collection. Roots from annual plants should generally be dug just before the

flowering period; those of biennial and perennial plants should be gathered late in the fall or early in the spring. Barks also should preferably be collected during the dormant season when the sap is not flowing. Leaves and herbs are of most value when collected during the flowering period or just before they have finished growing. Flowers should always be gathered when they first open. The material must be carefully dried. All plant material, in whatever form, is easily spoiled in both appearance and value if improper methods are used to remove the large quantity of moisture that is usually present. Fleshy roots dry very slowly and frequently become moldy unless they are sliced across or lengthwise to permit more rapid evaporation of the moisture. Leaves readily lose their green color while drying and sometimes become brown or even black. They should, therefore, be spread out in a well-ventilated room, especially in cloudy weather, and dried as rapidly as possible. Fruits, particularly those that are juicy, are especially difficult to handle on account of their tendency to become sour or moldy. They should preferably be spread out in thin layers on wire or cloth screens that will permit a thorough circulation of air and on which they can be frequently stirred. Seeds must be thoroughly cured; even ripe seeds that appear to be dry will frequently heat and spoil if stored without having been spread out and allowed to dry for at least several days. By following these steps for the collection and drying of the different parts of the plant result in productive yield and isolation of the proper components in plant when we soak the material in relevant solvent for the extraction (Williamson et al., 1998).

Role of natural remedies in hepatic disorder:

Recently, considerable attention has been paid to utilizing readily available and safe plant-based products for the prevention and cure of different human diseases (Dubey et al., 2004). Since 600 BC, the use of herbal medicine in the treatment of liver disorder has been in tradition. Expansions of herbal drugs are stimulated by the growing interest in understanding the causes of frequently

encountered hepatitis. Viral hepatitis is the inflammation of the liver, usually due to the attack of some virus (Flora et al., 1996). Hepatitis can be caused by alcohol, chemicals and by many different viruses; most of the infection is caused by one of the five viruses, viz. A, B, C, D and E. It is well known that hepatitis can be spread through hypodermic needles, blood infusions, and through cuts and scratches, but almost half of the infected patients usually do not know the source of infection (Pengelly, 1995). Hepatitis A and C often produce very mild symptoms and may go unnoticed, whereas B and E are most likely to produce more severe symptoms. Occasionally, especially with hepatitis B infection, an affected person develops joint pain and itchy red hives on the skin. After a few days, urine become dark yellow and jaundice (a yellowish discoloration of the skin and the whites of the eyes) may develop. Both these symptoms occur because bilirubin levels rise in the blood. The long duration between infection and illness represents an opportunity for the individual to seek alternative or complementary treatments. By making change in diet chart and life style, there will be enhancement in liver performance and overall health status of the patient. Diseases can be diagnosed on the basis of the patient's symptoms, and results of a liver function test may indicate that liver is inflamed either by alcohol abuse or due to virus. Till date no vaccines are available against hepatitis C, D and E (Biswas et al., 1990).

Liver performs a variety of functions in the body, some of those have been discussed here, like it involves in the metabolism of fats, carbohydrates, and protein. Large amount of transaminases (like GOT- Glutamyl oxaloacetic transaminase; GPT- Glutamyl pyruvic transaminase; AST- Aspartate aminotransferase; ALT-Alanine aminotransferase) is released into blood when cell damages. Thus, detection of serum level showed existence of liver cell damage These have been used as the marker of liver damage since then until now. GOT exist mainly in liver and myocardium, and in less amount in kidney and pancreas. The concentration

of GOT and GPT are 1,000 ~ 10,000 times of serum. GPT is more sensitive and specific than GOT in the detection of liver disease.

Information was collected about the *solanaceae* family, there are so many species of *solanaceae* but I was planned to study on *solanum nigrum* the most important plant of this family. The aim of this study was to determine hepatoprotective and hepatocurative effects of *solanum nigrum*.



Figure 1. The photo showing *Solanum nigrum*

Phytochemical principles: 2(s)-2-aminoadipic-acid, 26-o-(beta-d-glucopyranosyl)-22-methoxy-25d-5-alpha, calcium, alkaloids, ascorbic-acid, beta-carotene, beta-sitosterol, beta-solamargine, carbohydrates, carotene, d-galactosed-xylose, solasonine, tannin and solaninigrin (Duke, 1992).

Pharmacological studies: From the literature survey it has been stated that *Solanum nigrum* has been used to treat different cancers. It is used as a hepatoprotective and anti-inflammatory agent (Lin et al., 2007). It has been stated that its extract has hepatoprotective activity against CCl₄ (4)-induced oxidative damage in rats (Lin et al., 2008). Study conducted on lunasin isolated from extract of *Solanum nigrum* reported to have cytotoxic activity (Jeong et al., 2007; Lee and Lim, 2008). Expression in *Escherichia coli*, purification, refolding and antifungal activity of an osmotin from *Solanum nigrum* (Campos et al. 2000). It has diuretic and antipyretic effects (Li et al., 2007; Lee and Lim, 2007).

The aim of the present study was to determine the hepatocurative and hepatoprotective effects of *solanum nigrum* extract on Paracetamol induced hepatotoxicity in rabbits. Hepatoprotection was observed giving the *solanum nigrum* extract prophylactically to the rabbits before intoxication (paracetamol-induced). This study was designed to investigate the effect of methanolic extract of *solanum nigrum* on various biochemical parameters; serum glutamic oxalo-acetic acid transaminase (SGOT), serum glutamic pyruvic transaminase (SGPT) and alkaline phosphatase (ALP) in rabbits respectively for the evaluation of re-evaluation of the established traditional use of *solanum nigrum* in liver disorder by using different species *in-vivo* model of rabbits.

Materials and methods:

Chemicals; Following chemicals with specified sources were used for experimental procedures; Methanol (Merck Dranset, Germany), Paracetamol was gifted by Askari pharmaceuticals (Lahore, Pakistan). Methanol was of sigma chemical Co. Thiopental Sodium was obtained from Abbot Laboratories (Karachi, Pakistan). Deionized water was used for the dilution of various samples

Serum parameters: Serum glutamic oxalo-acetic acid transaminase (SGOT), serum glutamic pyruvic transaminase (SGPT) and alkaline phosphatase (ALP) levels were evaluated by enzymatic kits (Sigma Co) using Spectrophotometer (Perkin Elmer UV 256).

Animals: Male rabbits of local breed (*Oryctolagus cuniculus*) and either sex weighing 1-1.5±0.25 Kg were used. All animals were housed at the Animal House of Department of Pharmacy Bahauddin Zakariya University, Multan. Animals were in stainless steel cages under standard laboratory conditions by following, green fodder and water were available at laboratory.

Instruments and apparatus: Vacuum Pump (Vacuum brand, Germany), Rota-vapor (Buchii, Japan), Analytical Electric Balance, accuracy ± 0.1 mg (Diamond MCT 500), Sonicator (NeyUltra Sonik, Korea), Deionizer Water plant (Waterman, Karachi, Pakistan). Following laboratory apparatus were utilized during the research work; Pestle and Mortar (Glass Made), desiccators, Beakers of different volumes 50ml and 100 ml, graduated cylinder 50ml and 100ml, Petri dishes made of Pyrex and Sieve Mesh of size 8, 15 and 20 made of non-rustable material. This experiment was performed at 25 ± 2 °C.

Collection and Extraction of plant material:

Whole plant of *Solanum nigrum* (Figure 1) was purchased from Herbal store of the local market of Multan. The plant was identified with the help of expert taxonomist from the Institute of Pure and Applied Biology, Bahauddin Zakariya University, Multan. The plant material was rendered free from soil and adulterated materials, shade dried at 40°C and then ground in electric grinder into coarse powder by electrically driven device. The powdered material was soaked into methanol for 72 hrs with occasional shaking. The soaked material was rendered free of plant debris by passing through a muslin cloth and fluid portion was filtered through a fine filter paper. The filtrate was preserved in a labeled glass bottle with tight cap. The residue was again soaked in methanol for 72 hrs. The soaked material was rendered free of plant debris by passing through muslin cloth and the fluid portion was filtered through a fine filter paper. All portions of filtrate were combined and subjected to evaporation under reduced pressure on a rotary evaporator to thick paste like mass of dark brown color, i.e. the crude methanolic extract (SN). The extract was poured into Petri dish and placed in desiccators for 6-8 hrs so that the remaining solvent must be evaporated. Dried extract of plant were transferred in already weighed bottle. Final extract was dissolved in distilled water for all *in-vitro* experiments. The

remaining extract was preserved in refrigerator for further processing (figure 2).

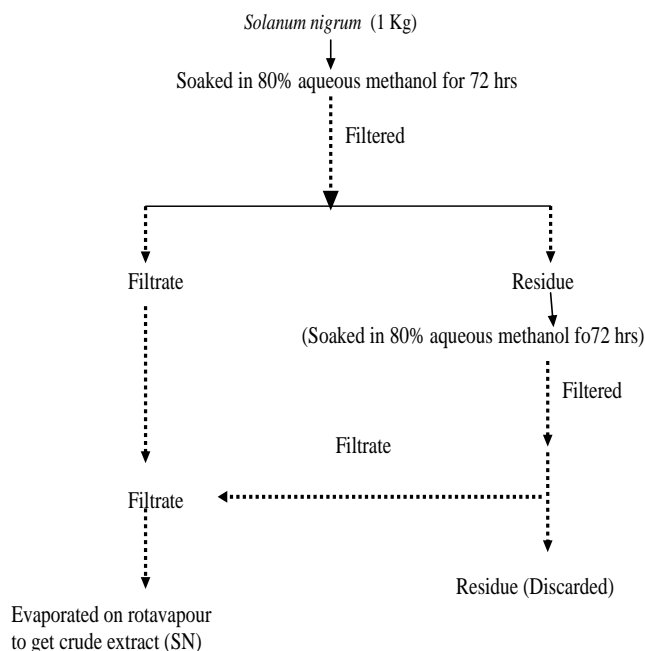
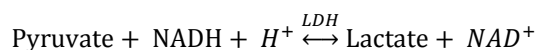
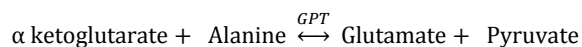


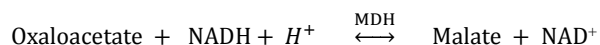
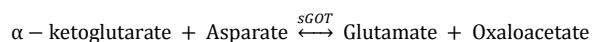
Figure 2. Schematic diagram for the preparation of aqueous-methanolic extract of the aerial parts of *Solanum nigrum*.

Kit method for determination of SGOT, SGPT and ALP: The parameter were used in hepatocurative and hepatoprotective effects of *solanum nigrum*. SGOT: Serum glutamic oxaloacetic acid transaminase; SGPT: Serum glutamic pyruvic transaminase; Alkaline phosphatase (ALP).

1. Procedure used for sGPT: Reaction Principal is as follows:



2. Procedure for SGOT: Reaction principal is as follows:

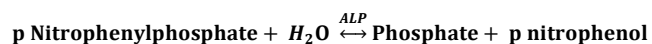


METHOD; Warm the reagents and the cuvettes to the desired temperature and must be kept constant for the duration of the test;

Table1: Procedure and calculations IU/l= $\Delta A/\text{min} \times \text{factor}$ (2143 at the 37 C⁰)

Pipette into cuvettes	25°C, 30°C	37°C
Sample	200 μ l	100 μ l
Buffer + LDH	1000 μ l	1000 μ l
Mix, incubate for 5 minutes at the 37 C ⁰ .		
Substrate (NADH)	250 μ l	250 μ l
Mix, Take the absorbance at 340nm after a one minute.		

3. Procedure used for ALP: Reaction Principal is as follows:



Method and Calculation: Same as mentioned above for SGPT and SGOT (Table-1)

Experiment Protocols:

1. Hepatocurative activity; For the assessment of the hepatocurative activity of the SN.CEA, rabbits of local breed have been used as experimental animals. Rabbits were divided into three experimental groups each comprising on five rabbits, one serving as normal control (saline treated), the other as hepatotoxic control (Paracetamol (2g/kg) treated) and the last one receiving 400 mg/kg body weight of SN.CEA respectively. Blood samples were taken at 6th and 12th day to determine the serum levels of tranaminases (SGOT, SGPT) and alkaline phasphatase (ALP) being the biochemical markers of hepatic status. Blood samples were taken at 6th and 12th day to determine the plasma levels of SGOT, SGPT and ALP.

Table 2. Hepatocurative effect of the crude extract of the aerial parts of *Solanum nigrum* (SN.CEA) on SGOT, SGPT and Alkaline phosphatase levels. Values represents Mean \pm S.E.M of 5 determinations.

Animal Group	sGPT (IU/L)	sGOT (IU/L)	ALP (IU/L)
Saline control	57 \pm 7.5	45 \pm 9.5	60 \pm 10.44
Hepatotoxic Control (Paracetamol)			
After 3 rd Day	312 \pm 34	254 \pm 40	159 \pm 20
After 6 th day	305 \pm 20.14	249 \pm 25	151 \pm 24.5
After 12 th day	325 \pm 28	260 \pm 15	170 \pm 20
Hepatotoxic Control (Paracetamol + SN.CEA)			
After 6 th day	195 \pm 18	170 \pm 38	90 \pm 20
After 12 th day	125 \pm 13.8	100 \pm 25.4	70 \pm 14.6

2. Hepatoprotective activity; Hepatoprotective activity of the plant material (SN.CEA) was evaluated on rabbits. Rabbits were divided in to three groups (n=5/group). 1st and 2nd group serving as controls (saline treated), third group was treated with plant extract up till 12 days, after this 2nd and 3rd groups were intoxicated with Paracetamol (2g/kg) by making 2nd group as hepatotoxic control to see the comparative effect on the serum levels of transaminases (SGOT,

SGPT) and alkaline phosphatase (ALP) of the pre-treated plant material group 3rd.

3. Assessment of sleeping and clotting times;

Sleeping and clotting times were observe in control (saline treated), hepatotoxic (paracetamol induced) and in plant treated hepatotoxic groups. Thiopental sodium (4 mg/kg) has been used as sleep inducer and clotting time was measured with help of capillary tube along with stop watch.

4. Safety Assessment; The crude extract of *Solanum nigrum* (SN.CEA) was tested for its safety profile in rabbits at different doses. Rabbits were divided into two groups five in each and were administered SN.CEA at 600 and 800 mg/kg of the body weight with free access to water and food and kept under observation for 24 hrs.

Table 3. Hepatoprotective effect of the crude extract of the aerial parts of *Solanum nigrum* (SN.CEA) on SGOT, SGPT and Alkaline phosphatase levels.

Animal Group	sGPT (IU/l)	sGOT (IU/l)	ALP(IU/l)
Saline Control 1	55 ± 7	42 ± 6	58 ± 18
Hepatoprotective Control 2 (Paracetamol 2g/kg)			
At 6 th day after Saline	296 ± 34	240 ± 38	145 ± 20
Hepatoprotective treated 3 (SN (400mg/kg) + Paracetamol (2g/kg))			
At 6 th day after Saline	172 ± 21.32	150 ± 27	70 ± 5.21

Results and Discussion:

1.Hepatocurative effect of *Solanum nigrum* on SGOT , SGPT and ALP in hepatotoxic rabbits:

Paracetamol significantly (p<0.001) raised the respective levels of serum transaminases (SGOT, SGPT) and alkaline phosphatase (ALP) when compared with these were compared with saline treated groups (Table-1). Moreover, when Paracetamol induced hepatotoxicity was challenged with SN.CEA, it not only significantly (p<0.001) reduced the toxic effects of Paracetamol in rabbits but also exhibited that its chronic treatment of SN.CEA has more capacity and is beneficial for hepatocuration as described in Table-2.

2. Prophylactic effect of *Solanum nigrum* on SGOT , SGPT and ALP in rabbits with

Paracetamol intoxication: Interestingly, when three groups were selected for this study and two of these were saline treated and last one was administer SN.CEA for 6 days after this treatment when at 6th day group 2nd and 3rd were intoxicated Paracetamol there was a clear difference in the respective levels of serum transaminases (SGOT, SGPT) and alkaline phosphatase (ALP) SN.CEA treated group when compared with group 2 as shown in Table-2.

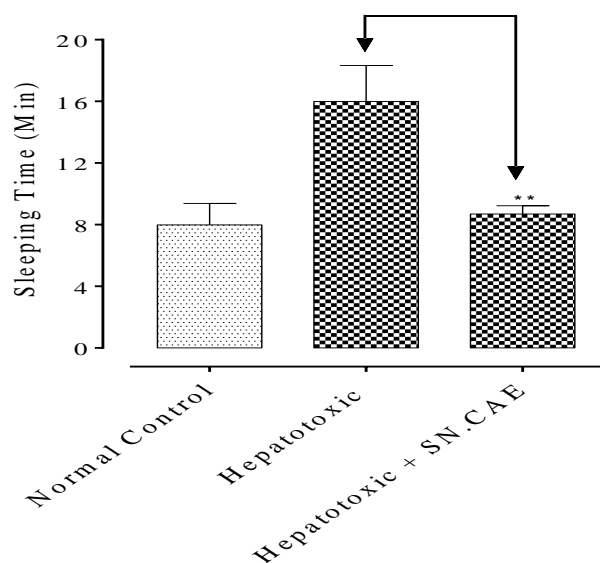


Figure 3. Effect of the crude extract of the aerial parts of *Solanum nigrum* (SN.CEA) on sleeping time in Paracetamol induced hepatotoxic group. Bars represents the respective sleeping time of different groups.

No clear difference was observed in the sleeping time in the rabbits of normal control and SN.CEA treated hepatotoxic group

3. Effect of *Solanum nigrum* (SN.CEA) on thiopental sodium induced sleeping time in rabbits: Hepatocurative and hepatoprotective effects of SN.CEA are further confirmed by observing the its effect on sleeping times in rabbits, further divided into normal control group, Hepatotoxic group and hepatotoxic group treated with SN.CEA. Data exhibited significant difference in the sleeping time of SN.CEA treated group checked at 7th day of the treatment when compared with the sleeping time of hepatotoxic.

4. Effect of *Solanum nigrum* (SN.CEA) on clotting time in hepatotoxic rabbits: The traditional use of SN.CEA in liver disorders, was further confirmed by observing its effect on clotting time in rabbits, further divided into

normal control group, hepatotoxic group and hepatotoxic group treated with SN.CEA. Data exhibited significant difference in the clotting time of SN.CEA treated group checked at 7th day of the treatment when compared with the clotting time of hepatotoxic group but no clear difference was observed in the clotting time in the rabbits of normal control and SN.CEA treated hepatotoxic group as described in figure-4.

Discussion: In this study, hepatoprotective and hepatocurative activities of SN.CEA have been assessed, Paracetamol was used for intoxication of the liver, as Paracetamol causes the liver injury at higher doses by raising levels of the relevant serum markers of liver functioning (Vagena et al., 2007). The elevation of SGPT, SGOT and alkaline phosphatase are an indicative for the release of enzymes from disrupted cells as shown in table 2. Treatment with methanolic extract of the aerial parts of the *solanum nigrum* (SN.CEA) significantly reduced the raised levels of SGPT, SGOT and alkaline phosphatase in Paracetamol induced-hepatotoxic rabbits as shown in table 3. This shows the presence of constituents in SN responsible for the liver regeneration which in turns reduced the raised enzyme level of the liver due to Paracetamol intoxication. This data shows the successful use of SN in liver dysfunction and these results of SN.CEA are in quick for its traditional use in liver disorders It is proven that barbiturates are metabolized in liver and the biotransformation of sedative –hypnotics carried out by liver can be affected due to liver damage (Anthony et al., 2000). The agents used in liver disorder are expected to improve the net effects of the barbiturates. When SN.CEA was tested on rabbits pretreated with thiopental sodium, it significantly reduced the sleeping time in Paracetamol intoxicated rabbits (Figure 3).

Similarly, liver is the origin of complete clotting factors. When the liver will be damage automatically resulting in abnormal production of

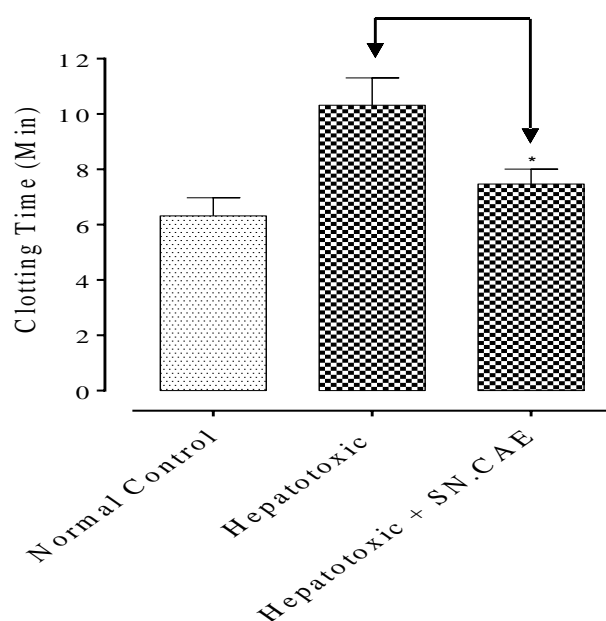


Figure 4. Effect of the crude extract of the aerial parts of *Solanum nigrum* (SN.CEA) on blood clotting time in Paracetamol induced hepatotoxic group. Bars represents the respective clotting times of different groups..

blood clotting factors which lead to delayed clotting time (Biswas, 1990).

The improvement in clotting time of the SN administered pre-intoxicated (Paracetamol) rabbits strengthens its liver healing activity (Figure 4). Moreover, when prophylactically, SN.CEA was administered to rabbits along with saline treated group were intoxicated with Paracetamol and the observed hepatoprotection in SN treated rabbits vs control indicate the presence of hepatoprotective constituents in the crude extract of *Solanum nigrum*. Safety assessment results also added a beauty for the safe use of *Solanum nigrum* in liver complications.

Conclusion: These experimental findings showed the existence of mixture of hepatocurative and hepatoprotective components in the crude extract of *Solanum nigrum* (SN.CEA). According to results it requires further research for the components of *Solanum nigrum* (SN.CEA) for its traditional uses in liver disorders.

REFERENCES

- Anthony, J., Trevor, & Walter, L.W. "Sedative - Hypnotics Drugs". In Basic and Clinical Pharmacology, McGraw-Hill. 2000, pp 369.
- Biswas, J.K., Das, A.K., Shaw, G.C., Mukherjee, N., Chakraborty, M. Studies on Outbreak of Viral Hepatitis at Calcutta with special reference to *serological investigation*, *J Ind Med Ass*, 88(9), 1990, 257-259
- Campos,mode.A.,Silva,M.S.,Magalhaes,C.P.,Ribeiro,S.G.,Sarto,R.P.,Vieira,E.A.,Grossi de Sa,M.F. Expression in *Escherichia coli*,purification,refolding and antifungal activity of an osmotin from *Solanum Nigrum*. *Microb cell fact* 200811;7:7
- Dubey, N.K., Kumar, R., Tripathi, P. Global promotion of herbal medicine, India's opportunity, *Cur. Sci*, 86(1), 2004, 37-41.
- Duke, J.A., Handbook of Phytochemical Constituents of GRAS Herbs and Other Grieve. *A Modern Herbal*. Penguin 1984 Economic Plants. CRC Press: 1992 Tokyo, pp 472-473.
- Flora, K.D., Rosen, H.R., Brenner, K.G. The use of neuropathic remedies for chronic liver diseases, *American Journal of gastroenterology*, 91, 1996, 2654-2658.
- Houghton, P.J. The Journal of Alternative and Complementary Medicine. 1955. (2) ;131-143.
- Jeonq,J.B.,Jeonq,H.J.,Park,J.H.,Lee,S.H.,Lee,J.R.,Lee,H.K.,Chunq,G.Y.,Choi,J.D.,de Lumen,B.O. . Cancer-preventive peptide lunasin from *Solanum nigrum* L. inhibits acetylation of core histones H3 and H4 and phosphorylation of retinoblastoma protein(Rb).*J Agric Food Chem*. 2007 26;55(26):10707-13.
- Lee,S.J.,Lim,K.T.Cell death signal by glycine and praline rich plant glycoprotein is transferred from cytochrome c and nuclear factor kappa B to caspase 3 in Hep 3B cells. *J Nutr Biochem*. 2008.;166-74.
- Pengelly, A. Assessment of hepatoprotective remedies, *Aust J Medl Herbal* , 7, 1995, 17-20.
- Vagena, M., Dimitroulopoulos, D., Papalois, A., Archontaki, E., Demonakou, M., Giannioti, K., Vertzoni, M & Galanopoulou, P.. Paracetamol induced hepatotoxicity in rabbits and the role of prior acute ethanol consumption. Review of Clinical Pharmacology and Pharmacokinetics. 2007,21;5-12. Weiner, M.,A. *Earth Medicine, Earth Food*. Ballantine Books 1980
- Williamson, E., Okpako, M. D. T., Evans, F.J. Selection, preparation and pharmacological Evaluation of Plant Material. *John Wiley & Sons. Chichester, England*, 1998. pp.15-23.