

# Kidney Based Disease Identification Using Automatic 3D Segmentation

Ms.Anu.V<sup>1</sup> Mrs. Vaaneeswari.V<sup>2</sup>

1,2(Department of CS & IT, Dhanalakshmi Srinivasan College of Arts & Science for Women, Perambalur-621212.)

## Abstract:

Different kidney diseases affect different part of kidney. For example, kidney tumor usually occurs in renal cortex, renal column hypertrophy may exist in renal column, medullary cystic kidney disease usually exists in renal medulla, and transitional cell cancer, renal pelvis and ureter cancer may attack renal pelvis To propose automatically segment kidney and detect disease occurs in kidney. Random forest and modified active appearance model can performed in this project

*Keywords — Kidney Diseases, Renal Cortex, Renal Column Hypertrophy, Medullary Cystic, Renal Pelvis, Random forest and modified active.*

## I. INTRODUCTION

Medical imaging is the technique and process of creating visual representations of the interior of a body for clinical analysis and medical intervention, as well as visual representation of the function of some organs or tissues (physiology).

## II. EXISTING SYSTEM

The most existed methods only analyzed volume and morphology of whole kidney or renal cortex.

kidney components segmentation four major structures: renal cortex, renal column, renal medulla and renal pelvis, as shown , the renal cortex and renal column are connected and have similar intensity; the renal pelvis consists of several different structures with different intensities.

The boundaries between kidneys and adjacent organs such as spleen and liver are usually blurred.

## III. DISADVANTAGE

The existing method cannot provide segmentation accuracy in kidney segmentation.

Wrong identification in bifurcation and crossover points.

Existing system only follow the preprocessing steps but difficult to identify the kidney with noises in image.

## IV. PROPOSED SYSTEM

To propose a fast fully automatic kidney segmentation method, the kidney into four components: renal cortex, renal column, renal pelvis and renal medulla.

Two parts: localization of renal cortex and segmentation of kidney components. In localization of renal cortex, the Active Appearance Model (AAM) method is used.

In segmentation of kidney components, the random forests method is used.

### **ADVANTAGE**

Efficient post processing step for tracking cross over points.

Simultaneously identifying the kidney components.

Advanced approach for kidney structure segmentation.

Easily identify the diseases with improved accuracy rate.

## **II. MODULES**

- Image acquisition
- Preprocessing
- Image localization
- Evaluation criteria

### **➤ IMAGE ACQUISITION**

The kidney image or upload the datasets.

The uploaded datasets contains 3D kidney images.

Then web camera images known as 2D images, then these face images are converted into 3D images.

And also input the videos, then converted into frames after every 0.5 second.

### **➤ PREPROCESSING**

The RGB image into gray scale images.

Then remove the noises from images by using filter techniques.

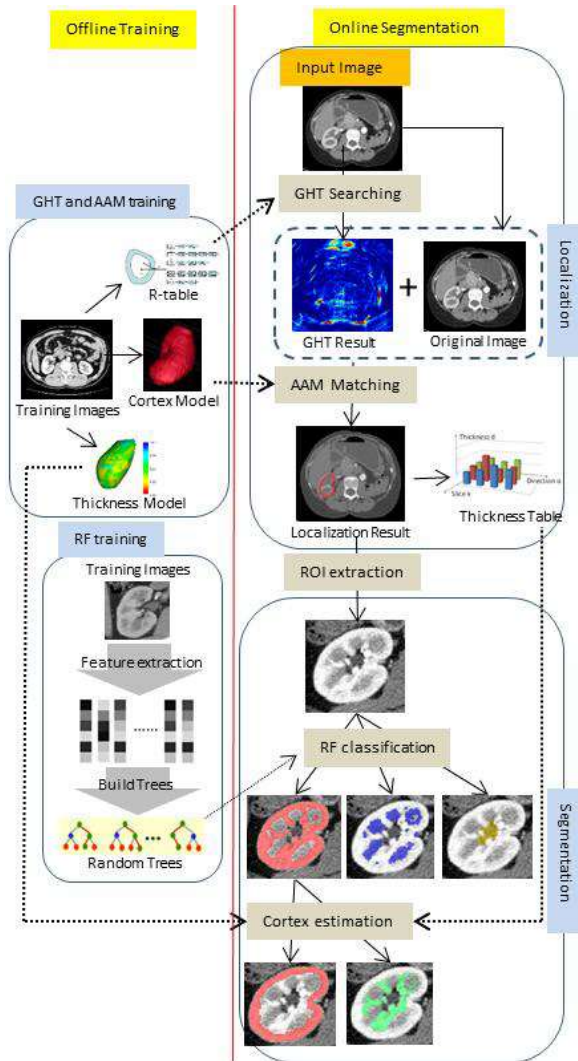
The goal of the filter is to filter out noise that has corrupted image. It is based on a statistical approach.

Filtering is a nonlinear operation often used in image processing to reduce "salt and pepper" noise.

### **➤ IMAGE LOCALIZATION**

- Localization is the process of 3D fast automatic segmentation of kidney. use one algorithm and one technique.
- Active Appearance Model
- Generalized Hough Transform (GHT)

### III. Flowchart of the proposed method



#### ACTIVE APPEARANCE MODEL

An active appearance model (AAM) is a computer\_vision algorithm for matching a statistical\_model of object shape and appearance to a new image.

The algorithm uses the difference between the current estimate of appearance and the target image to drive an optimization process. By taking advantage of the least\_squares techniques, it can match to new images very swiftly.

#### GENERALIZED HOUGH TRANSFORM (GHT)

The Hough transform was initially developed to detect analytically defined shapes such as line, circle, ellipse etc.

The generalized Hough Transform, the problem of finding the model's position is transformed to a problem of finding the transformation's parameter that maps the model into the image.

3D GHT can find the center of gravity of kidney efficiently

#### SEGMENTATION

The multithreading technology to speed up the segmentation process.

An improved random forests method is used to segment kidney components accurately and efficiently, the proposed method is highly efficient which can segment kidney into four components within 20 seconds.

#### ➤ EVALUATION CRITERIA

The last module of automatic kidney segmentation.

Finally segment the disease part in input kidney image using two methods.

These two methods are analysis the image and provide clear output.

#### IV. CONCLUSION

In this paper, we proposed a fast fully automatic method for kidney components segmentation. The proposed method consists of two main parts: localization of renal cortex and segmentation of kidney components. In the localization phase, a fast

localization method which effectively combines 3D GHT and 3D AAM is proposed, which utilizes the global shape and texture information. In the segmentation phase, a modified RF method and a cortex thickness model are proposed to efficiently accomplish the multi-structure segmentation task. The proposed method was tested on a CT dataset comprised of 37 images. Currently the proposed algorithm works well for kidneys whose structures are not significantly altered by diseases. If diseases such as kidney tumor causes dramatic change in kidney morphology or texture, our modified AAM which are trained on the normal dataset may not perform well. For renal cortex and column segmentation, the renal cortex thickness model is also designed for normal cortex shape. A more flexible cortex model will be developed in the near future. For random forest classification, to segment kidney with significant change in morphology or texture, training on specific dataset is also desired. Another limitation of the proposed method is all images used in this paper were contrast-enhanced. These segmentation task is more difficult for non-contrast-enhanced CT images.

## **ACKNOWLEDGMENT**

*The author deeply indebted to honorable Shri A. SRINIVASAN (Founder Chairman), SHRI P. NEELRAJ (Secretary) Dhanalakshmi Srinivasan Group of Institutions, Perambalur for giving me opportunity to work and avail the facilities of the College Campus. The author heartfelt and sincere thanks to Principal Dr. ARUNADINAKARAN, Vice Principal Prof. S. H. AFROZE, HoD Mrs. V. VANEESWARI, (Dept. of CS & IT) Project Guide Ms. R. ARUNADEVI, (Dept. of CS & IT) of Dhanalakshmi*

*Srinivasan College of Arts & Science for Women, Perambalur.*

*The author also thanks to parents, Family Members, Friends, Relatives for their support, freedom and motivation.*

## **REFERENCES**

- [1] Source: Summary Health Statistics for U.S. Adults: National Health Interview Survey, 2011, tables 7, 8, <http://www.nlm.nih.gov/medlineplus/kidneydiseases>.
- [2] Source: Deaths: Final Data for 2010, tables 9, 10, 11, <http://www.nlm.nih.gov/medlineplus/kidneydiseases>.
- [3] WL. Clapp. "Renal Anatomy". In: XJ. Zhou, Z. Laszik, T. Nadasdy, VD. D'Agati, FG. Silva, eds. *Silva's Diagnostic Renal Pathology*. New York: Cambridge University Press; 2009.
- [4] Siemer, Stefan, et al. "Efficacy and Safety of TachoSil as Haemostatic Treatment versus Standard Suturing in Kidney Tumour Resection: A Randomised Prospective Study." *European urology*, vol. 52. no. 4, pp.1156-1163, 2007.
- [5] L. Jun, Z. Xiaodong, L. Erping, —Study on Differential Diagnosis of Renal Column Hypertrophy and Renal Tumors by Pulsed Subtraction Contrast-enhanced Ultrasonography, *Chinese Journal of Ultrasound in Medicine*, 4. 039, 2006.
- [6] T. Hart, M. Gorry, P. Hart, et al. —Mutations of the UMOD gene are responsible for medullary cystic kidney disease 2 and familial juvenile hyperuricaemic nephropathy, *Journal of medical genetics*, vol. 39(12), pp. 882-892, 2002.
- [7] J. Bennington, J. Beckwith, —Tumors of the kidney, renal pelvis, and ureter, *Washington, DC: Armed Forces Institute of Pathology*, 1975.
- [8] O. Gloger, K. Tonnie, R. Laqua, et al. —Fully Automated Renal Tissue Volumetry in MR Volume Data Using Prior Shape Based Segmentation in Proband-Specific

Probability Maps,|| *IEEE Trans. Biomed. Eng.*, vol. 62, no. 10, pp. 2338-2351, 2015.

[9] M. D. Beland, N. L. Walle, J. T. Machan, and J. J. Cronan, —Renal

cortical thickness measured at ultrasound: Is it better than renal length

as an indicator of renal function in chronic kidney disease?,|| *Am. J.*

*Roentgenol.*, vol. 195, no. 2, pp. 146–149, 2010.

[10] N. S. Muto, T. Kamishima, A. A. Harris, F. Kato, Y. Onodera, S. Terae, and H. Shirato, —Renal cortical volume measured using automatic contouring software for computed tomography and its relationship with BMI, age and renal function,|| *Eur. J. Radiol.*, vol. 78, no. 1, pp. 151–156, 2011.

[11] F. Artunc, S. Yildiz, C. Rossi, A. Boss, H. Dittmann, H. P. Schlemmer,

T. Risler, and N. Heyne, —Simultaneous evaluation of renal morphology

and function in live kidney donors using dynamic magnetic resonance imaging,|| *Nephrol. Dial. Transplant.*, vol. 25, no. 6, pp. 1986–1991, 2010.

[12] L. A. Stevens, J. Coresh, T. Greene, and A. S. Levey, —Assessing kidney function—Measured and estimated glomerular filtration rate,||

*N. Engl. J. Med.*, vol. 354, no. 23, pp. 2473–2483, 2006.

[13] C. Mounier-Vehier et al., —Cortical thickness: An early morphological

marker of atherosclerotic renal disease,|| *Kidney Int.*, vol. 61, no. 2, pp. 591–598, 2002.

[14] SA. Koff, L. Binkovitz, B. Coley, et al. —Renal pelvis volume during diuresis in children with hydronephrosis: implications for diagnosing obstruction with diuretic

renography,|| *The Journal of urology*, vol. 174, no. 1, pp. 303-307, 2005.

[15] J. A. d. Priester, A. G. Kessels, E. L. Giele, J. A. d. Boer, M. H. Christiaans, A. Hasman, and J. M.v. Engelshoven, "MR renography by semiautomated image analysis: performance in renal transplant recipients,|| *J Magn Reson Imag*, vol. 14, pp.134-140, 2001.

## BIOGRAPHICAL NOTES

Ms.ANU.V is presently pursuing Computer Science M.Sc., Final year the Department of Computer Science From Dhanalakshmi Srinivasan College of Arts and Science for Women, Perambalur, Tamil Nadu ,India.

Mrs.VANEESWARI.V - Received M.S.c., M.Phil

Degree in Computer Science. She is currently working as Assistant Professor in Department of Computer Science in Dhanalakshmi Srinivasan College of Arts and Science for Women, Perambalur Tamil Nadu, India.