

A comparative study of magnetic resonance imaging and arthroscopy in internal derangement of knee

Vellanki Sarath^{1,*}, A. Srinivasa Rao², K. Jyotsna Vibhari³

¹Associate Professor, ²Professor and HOD, ³Post Graduate, Dept. of Orthodontics, Katari Medical College & Hospitals, Chinakondrupadu, Guntur, Andhra Pradesh, India

***Corresponding Author:**

Email: drsarathvellanki@rediffmail.com

Abstract

The purpose of this study is to compare the findings of magnetic resonance imaging with arthroscopy in internal derangements of knee and to assess the sensitivity, specificity and accuracy of magnetic resonance imaging in comparison to arthroscopy.

Methods and Materials: Fifty six patients with history of suspected internal derangement of knee were evaluated prospectively with MRI and compared with arthroscopy during a one and half a year period from January 2016 to June 2017 at Katari Medical College & Hospitals, Chinakondrupadu, Guntur. 1.5 Tesla MRI machine using a closed extremity coil is used. Commonly used sequences in MRI of the knee include Turbo-spin echo (TSE), FFE (Gradient echo) and Short Tau Inversion Recovery (STIR) sequences in Axial, Sagittal and Coronal planes using a slice thickness of 3 mm with a 0.3 mm slice gap. Arthroscopy of the knee with standard anteromedial and anterolateral portals with the patient in supine position done in all the cases.

Observations: The diagnostic sensitivity, specificity and accuracy of MRI in detecting cruciate ligament and meniscal injuries as compared to arthroscopy is as follows: Anterior Cruciate Ligament (ACL): 97.29%, 89.47%, 94.64% ; Posterior Cruciate Ligament (PCL): 100%, 100%, 100%; Medial Meniscus (MM): 100%, 93.33%, 98.21% and Lateral Meniscus (LM): 93.10, 92.59, 92.85. Most common lesions found were ACL and Medial Meniscal tears (posterior horn of MM being the most common site).

Summary and Conclusion: MRI is a useful non-invasive modality having high sensitivity, specificity and accuracy in diagnosing cruciate ligament and meniscal injuries. MRI should be considered as the first line of investigation in all patients with suspected internal derangements of knee. MRI being easily available and non-invasive is useful as a pre-operative screening modality, thus improves the quality of diagnostic and therapeutic arthroscopies and further reduces the morbidity. Arthroscopy is the gold standard in diagnosing cruciate ligament and meniscal injuries.

Keywords: Arthroscopy, MRI.

Introduction

The knee joint is one of the most vulnerable and frequently injured joints of the body. The injuries can be either acute or chronic and they constitute a major cause of pain and instability.

The various imaging modalities currently used to evaluate pathological conditions of the knee include conventional radiography, fluoroscopy, arthrography, sonography, computed tomography, nuclear medicine and magnetic resonance imaging.

The imaging of most pathological entities requires plain films. The use of fluoroscopy and sonography to guide interventional procedures and CT to evaluate complex fractures has become routine. The role of MRI in imaging of knee has steadily increased over the years and is often the main or only imaging tool for evaluation of suspected internal derangements of knee.¹

The most significant advances in imaging of the knee has been made in the realm of magnetic resonance imaging, which has clearly emerged as a primary tool in evaluation and guiding the management of internal derangements of knee. With the development of newer sequences with improved SNR, higher resolution, shorter imaging times and improved accuracy, MRI has changed the traditional algorithm for workup of suspected internal derangements of knee.

Advantages of MRI over other imaging modalities include lack of ionizing radiation, excellent soft tissue contrast, multiplanar imaging capabilities, non-invasive and do not require manipulation of the knee as in Arthrography.

MRI Cartigram is showing promise in evaluation of cartilage lesions of the knee, which is now being increasingly done in many centres.

Arthroscopy is a minimally invasive surgical procedure in which an examination and sometimes treatment of damage of the interior of a joint is performed using an arthroscope, a type of endoscope that is inserted into the joint through a small incision. Arthroscopic procedures can be performed either to evaluate or to treat many orthopaedic conditions.

Knee arthroscopy has in many cases replaced the classic arthrotomy that was performed in the past. Today knee arthroscopy is commonly performed for treating meniscus injury, reconstruction of the anterior cruciate ligament and for cartilage microfracturing. Arthroscopy can also be performed just for diagnosing and checking of the knee; however, the latter use has been mainly replaced by magnetic resonance imaging.

During an average knee arthroscopy, a small fiberoptic camera (the arthroscope) is inserted into the joint through a small incision, about 4 mm (1/8 inch)

long. A normal saline is used to visualize the joint parts. More incisions might be performed in order to check other parts of the knee. Then other miniature instruments are used and the surgery is performed.

Aims and Objectives

1. To compare the findings of magnetic resonance imaging of Knee with arthroscopy in internal derangements of Knee.
2. To assess the sensitivity, specificity and accuracy of magnetic resonance imaging in comparison to arthroscopy.

Materials and Methods

Fifty six patients with history of suspected internal derangements of knee were evaluated prospectively with MRI and correlated with arthroscopy during a one and half a year period between January 2016 to June 2017 at Katuri Medical College & Hospitals, Chinakondrupadu, Guntur. MR imaging was performed on a 1.5 Tesla (Philips Achieva) machine. Relevant clinical history and clinical findings were taken into consideration in performing MRI. In this study, arthroscopy was considered to be the gold standard and MRI finding were correlated.

Patient Positioning and Coil Selection: Patient is placed in supine position with the knee in a closely placed extremity coil. The patient's knee is placed in a relaxed position with slight external rotation (15 to 20°) which facilitates the visualisation of ACL completely on sagittal images²³. The knee is flexed slightly of about 5 to 10° which increases the accuracy of assessing the patellofemoral compartment and patellar alignment.⁵⁷

Imaging Protocol and Pulse Sequences: Routinely used sequences in MR imaging of the knee include turbo-spin echo (TSE), FFE (Gradient echo) and Short Tau Inversion Recovery (STIR) sequences. The standard imaging planes used are Axial, Sagittal and Coronal views. Imaging protocols for MRI knee was done using a field of view (FOV) of 200×200 mm, 256×256 matrix and slice thickness of 3 mm with a 0.3 mm gap. An axial acquisition through the patellofemoral joint is used as an initial localiser for subsequent sagittal and coronal imaging planes.

Arthroscopy: Arthroscopy is a minimally invasive surgical procedure in which an examination and sometimes treatment of damage of the interior of a joint is performed using an arthroscope, a type of endoscope that is inserted into the joint through a small incision. Arthroscopy of knee can be done under spinal anaesthesia or general anaesthesia. Position of the patient is supine position. A tourniquet may be used around the thigh to help control bleeding during knee arthroscopy. Standard anteromedial and anterolateral portals of the knee are used. A narrow tube with a tiny camera on the end will be placed inside through one of the cuts. The camera is attached to a video monitor in

the operating room. The surgeon looks at the monitor to see the inside of knee. Saline will be pumped into the knee to stretch the knee.

Arthroscopy was performed within a period of approximately one day to 20 days. Arthroscopy was performed by senior Orthopaedician. The MR images were reported by senior radiologists. In our study the orthopaedic surgeon performing the arthroscopy was aware of the MRI findings. Patients with grade 1 and grade 2 meniscal tears were excluded from the study as these lesions do not reach the articular surface and are not visualised during arthroscopy. The images were reviewed for the presence of ACL, PCL &/or meniscal tears.

ACL and PCL tears were diagnosed based on the presence of any of the primary signs. Only grade 3 meniscal tears which extend to one of the articular surfaces were included in the study.

The sensitivity, specificity and accuracy of MRI was based on the findings of arthroscopy as arthroscopy was taken as the gold standard for the diagnosis of internal derangements of the knee.

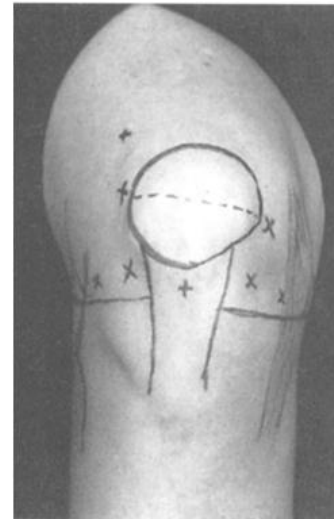

Fig. 1:

Anterior view of knee showing standard and optional portal sites and landmarks.

Diagnosis & Modalities of Treatments: Internal derangement of knee injuries are easily diagnosed with careful history and physical examination of the knee. Patients present with history of twisting injury to knee in motion C/o pain mild to moderate swelling locking/catching/click of the knee, inability to bend or straighten the knee, difficulty in squatting / climbing up stairs, limp, instability.

Evaluation of Meniscal injury by clinical test

1. Localised joint line tenderness
2. Mc Murray's test
3. Apley's test

4. Squat test
5. Anterior and Posterior Drawer's test
6. Pivot shift test
7. Lachman's test
8. Varus /Valgus stress test

Investigation: Plane Radiography of the knee AP and lateral view were taken to rule out associated fracture, ligamentous avulsion, loose bodies, arthritic changes

Routine investigation to assess the fitness of the patient for procedure which are Hb%. TC, DC, ESR, BT/CT, RBS, Blood Urea, serum creatinine

Observations: A total of 56 patients in suspected internal derangements of knee were evaluated with MRI and subsequently by Arthroscopy. Out of 56 patients, 44 were males and 12 were females. Patients' age range from 14 to 65 years (mean of 35 yrs).

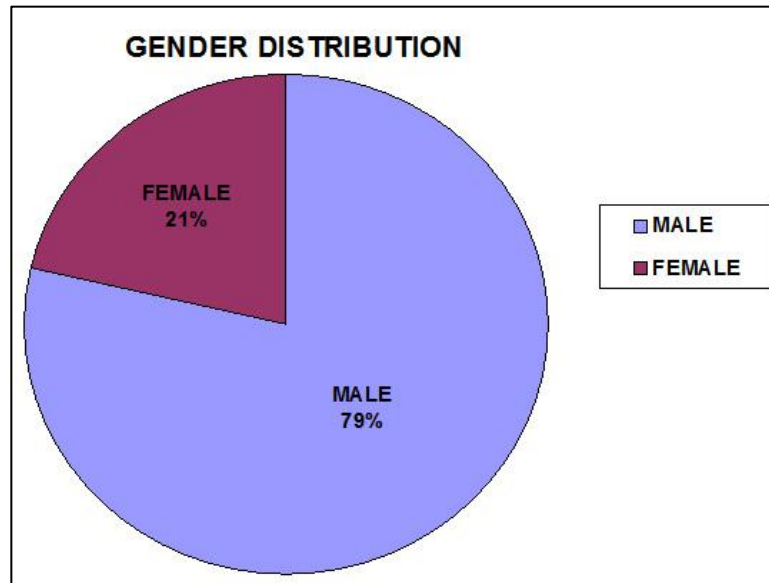


Fig. 2:

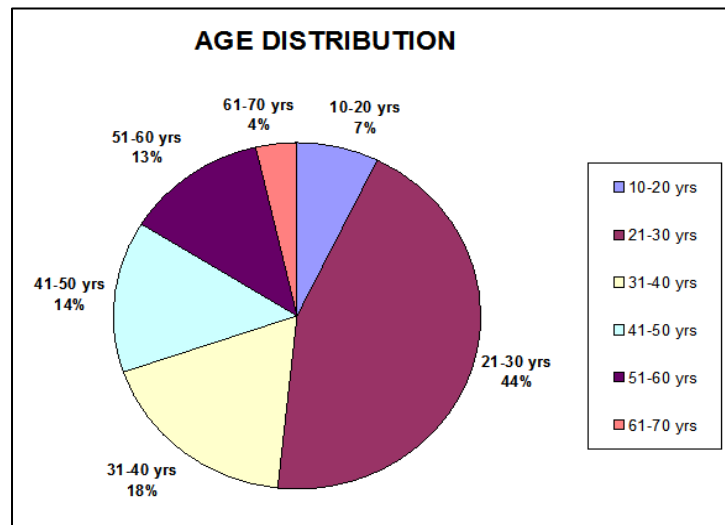


Fig. 3:

Table 1: Comparison

	MRI	Arthroscopy
ACL	38	37
PCL	3	3
Medial meniscus	42	41
Lateral meniscus	29	29

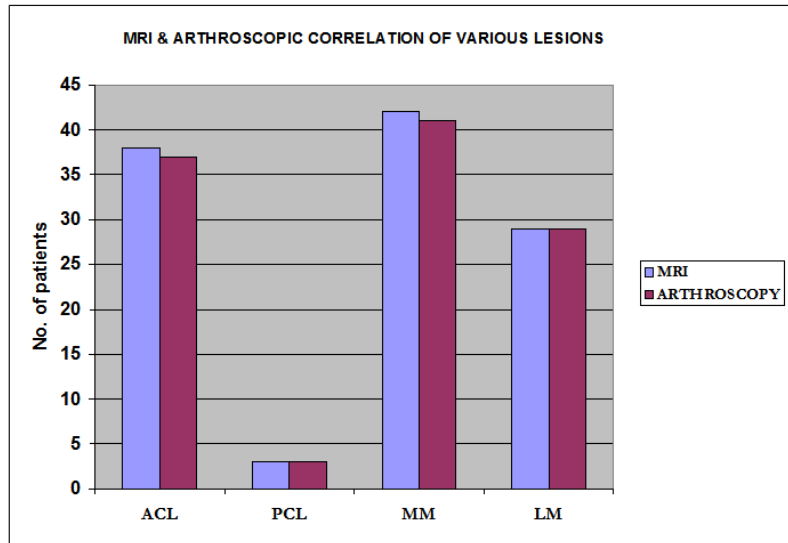


Fig. 4:

Cruciate Ligament Tears: Out of 56 patients, 38 cases showed ACL tears and 3 cases showed PCL tears. ACL tears were also associated with tears like meniscal tears and PCL tears. 28 out of 38 ACL tears showed associated meniscal tears. Buckling of PCL was seen in 7 cases of ACL tears. Isolated ACL tears were seen in 8 cases. Of the 3 cases of PCL tears, 2 cases were associated with ACL tears also.

MRI findings of ACL tears were correlated with arthroscopy. Sensitivity, specificity and accuracy of MRI in ACL tears were 97.29%, 89.47% and 94.64% respectively.

All the 3 patients who had PCL tears on MRI were reported to have PCL tears on arthroscopy. The diagnostic sensitivity, specificity and accuracy of MRI in diagnosing PCL tears are 100% in this study.

Meniscal Tears: Out of 56 patients, 42 cases showed medial meniscal tears and 29 cases showed lateral meniscal tears. 27 cases of medial meniscal tears were associated with ACL tears and 18 cases of lateral meniscal tears were associated with ACL tears. Both meniscal tears were seen in 24 cases. 5 cases of bucket handle tears were seen in medial meniscus. Discoid meniscus with tear was seen in one patient, involving medial meniscus.

Out of 42 patients with medial meniscal tears, 3 cases showed tears in anterior horn, 7 cases showed tears in the body and 41 cases showed tears in the posterior horn.

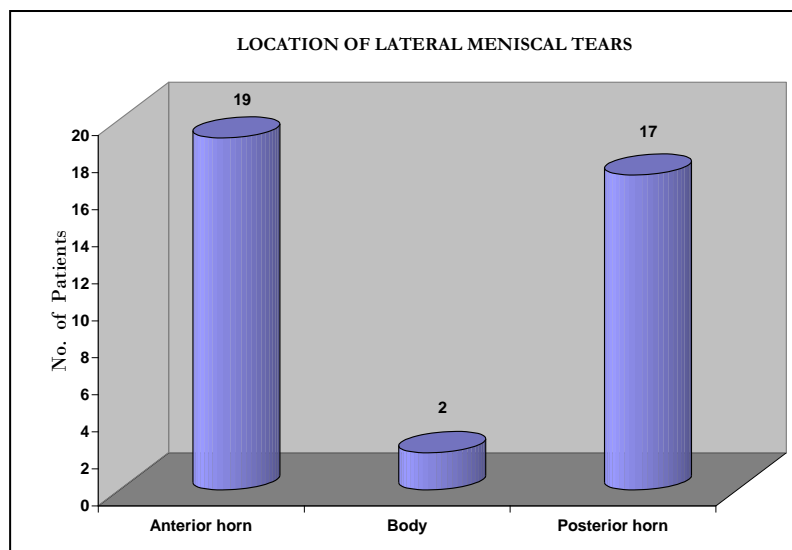


Fig. 5:

Out of 29 patients with lateral meniscal tears, anterior horn tears were seen in 19 cases, tears in the body were seen in 2 cases and posterior horn tears were seen in 17 cases.

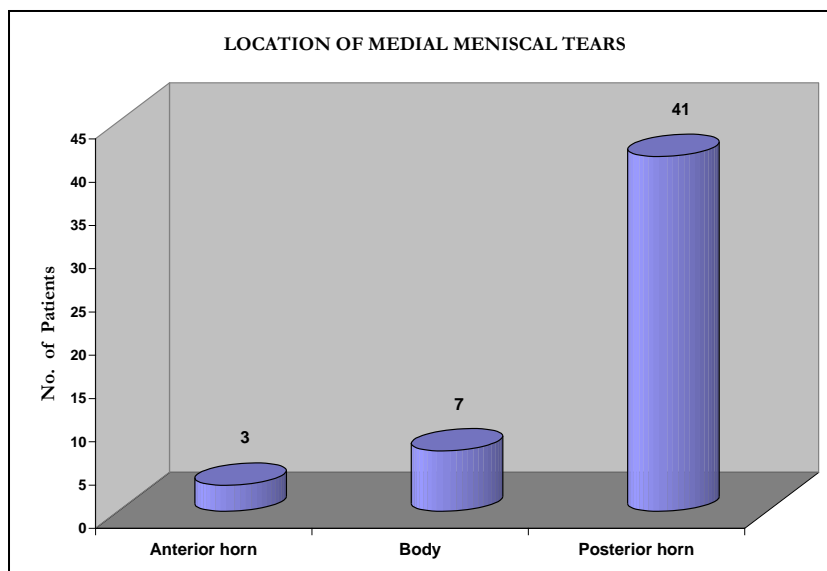


Fig. 6:

Table 2: Sensitivity, Specificity, Accuracy

	ACL	PCL	Medial meniscus	Lateral Meniscus
True positives	36	3	41	27
False positives	2	0	1	2
False negatives	1	0	0	2
True negatives	17	53	14	25
Sensitivity	97.29	100	100	93.10
Specificity	89.47	100	93.33	92.59
Positive predictive value	94.73	100	97.61	93.10
Negative predictive value	94.44	100	100	92.59
Accuracy	94.64	100	98.21	92.85

Discussion

Our study spanned over a 1¹/₂ year period from January 2016 to June 2017. Prospective evaluation of 56 patients with suspected internal derangements of knee with MRI and subsequently arthroscopy was done.

The cruciate ligaments and menisci were studied on both the modalities and comparisons were drawn.

Arthroscopy was considered as gold standard and the sensitivity, specificity and accuracy of MRI were calculated.

Of the 56 patients studied, there were 38 ACL tears, 3 PCL tears, 42 medial meniscal tears and 29 lateral meniscal tears on MRI.

Cruciate Ligament Tears: The accuracy of MR imaging in assessing cruciate ligament tears has been reported to be high. MRI diagnosis of ACL tears was based on primary and secondary signs, as described earlier. Out of 56 patients, 38 ACL tears and 3 PCL tears were seen. Several studies including the study done by Carrino et al⁵⁸ in 2002, reported that incidence of ACL tear is more common than PCL tear.

Out of 38 ACL tears on MRI, 2 cases were reported to be normal ACLs on arthroscopy (false positive). Rest of the 36 cases were confirmed on arthroscopy. One case which was reported to have an ACL tear on arthroscopy was reported as normal on MRI (false negative).

Two false positive cases of ACL tears were seen. One was because of intrasubstance hyperintensities, which was reported as normal on arthroscopy. The other case showed non-visualization of ACL, which may be contributed to ligament laxity.

One false negative case of ACL tear was identified, which probably is because of a partial tear. Studies by Yao et al⁵⁹ and Umans et al⁶⁰ showed that MR imaging has relatively low sensitivity but moderate to high specificity in diagnosing partial ACL tears.

In evaluating ACL tears, the sensitivity, specificity and accuracy in our study were 97.29%, 89.47% and 94.64% respectively. These results were comparable to the studies done by Fischer et al⁵⁷ and Jackson et al³¹.

The role of MRI in diagnosing PCL tears is extremely accurate. In our study 3 PCL tears were seen, which were confirmed on arthroscopy. The sensitivity,

specificity and accuracy of MRI in detecting PCL tears in this study was 100%, which was comparable to the study done by *Sonin et al*³⁷ where they have reported sensitivity, specificity and accuracy of 99 to 100%.

Meniscal Tears: Role of MRI in assessing meniscal tears is extremely accurate. Patients with Grade III

meniscal tears were only included in the study as Grade I and Grade II tears are not clearly visualized on arthroscopy. Out of 56 patients, 42 cases had Grade III medial meniscal tears and 29 cases had Grade III lateral meniscal tears. Both meniscal tears were seen in 24 cases.

Table 3: Diagnostic performance statistics for MRI of ACL²³

Reference	No. of patients	Sensitivity	Specificity	Accuracy
Mink et al	242	92	95	95
Fischer et al	997	93	93	93
Heron et al	100	88	96	94
Kelly et al	60	88	94	93
Jackson et al	87	100	96	97
Lee et al	41	94	100	98
Niitsu et al	52	71	88	79

Table 4: Diagnostic performance statistics for MRI of PCL²³

Reference	No. of patients	Sensitivity	Specificity	Accuracy
Lee et al	41	94	100	98
Niitsu et al	52	100	96	96
Gross et al	201	100	100	100
Fischer et al	1014	80	99	99

Table 5: Diagnostic performance statistics for MRI of medial meniscus²³

Reference	No. of patients	Sensitivity	Specificity	Accuracy
Glashow et al	50	77	71	74
Raunest et al	50	94	37	72
Kelly et al	60	97	77	88
Mandelabum	80	96	82	90
Jackson et al	87	98	89	94
Crues et al	171	98	91	99
Spiers et al	58	97	77	86
Quinn et al	219	92	82	89
Fischer et al	911	93	84	89

Table 6: Diagnostic performance statistics for MRI of lateral meniscus²³

Reference	No. of patients	Sensitivity	Specificity	Accuracy
Reicher et al	43	75	84	81
Glashow et al	50	93	94	94
Raunest et al	50	78	69	72
Kelly et al	60	90	87	88
Mandelabum	80	75	95	91
Jackson et al	87	85	99	97
Crues et al	171	96	98	98
Spiers et al	58	100	97	97
Quinn et al	219	70	95	87
Fischer et al	911	68	94	88

Summary and Conclusions

MRI is a useful non-invasive modality having high sensitivity, specificity and accuracy in diagnosing cruciate ligament and meniscal injuries.

Patients in the age group of 21–30 years accounted for maximum number of cases.

MRI is extremely useful in the evaluation of internal morphology and also the surface of the meniscus. MRI is more sensitive than arthroscopy in detecting intra substance tears and small peripheral meniscal tears.

MRI should be considered as the first line of investigation in all patients with suspected internal derangements of knee. Arthroscopy should be reserved for selected cases where intervention is required and as a problem solving tool.

MRI being easily available and non-invasive is useful as a pre-operative screening modality, thus improves the quality of the arthroscopic evaluation and interventions and further reduces the morbidity.

Financial Support and Sponsorship: Nil

Conflicts of Interest: There are no conflicts of interest

References

- Gray SD, Kaplan PA, Dussault RG. Imaging of knee: current status. *ONCA* 1997;28(4):643-658.
- Irizarry JM, Michael PR. MR Imaging of the knee ligaments and the postoperative knee. *Radiologic clinics of North America* 1997;35:45-76.
- Rubin DA, George AP. Current concepts and controversies in Meniscal Imaging. 2000;8:243-270.
- Kean DM, Worthington BS, Preston BJ. Nuclear MRI of knee: Examples of normal anatomy and pathology. *Br J Radiology* 1983;56:355-361.
- Moon KL, Genant HK, Helms CA, Chafetz NI, Crooks LE, Kaufman L. Musculoskeletal applications of nuclear MR Radiology 1983;147:161-171.
- Li KC, Henkelman M, Poon PY, Robenstein J, MR Imaging of the knee *J Comput Assist Tomogra* 1984;8:1147-1154.
- Reicher MA, Rauschnig W, Gold RH, Basset LW, Lufkin RB, Glen W: High resolution MRI of the knee joint: Normal anatomy. *AJR* 1985;145:895-902.
- Reicher MA, Basset LW, Gold RH: High resolution MRI of the knee joint: Pathological correlations. *AJR* 1985;145:903-909.
- Hajek PC, Baker LL, Sartoris DJ, Neumann CH, Resnick D. Mr Arthrography: An anatomic – Pathologic investigation. *Radiology* 1987;163:141-147.
- Kieser CW, Jackson RW (May 2001). "Severin Nordentoft: The first arthroscopist". *Arthroscopy* 17 (5):532-5. doi:10.1053/jars.2001.24058. PMID 11337723.
- CH Bennett & C Chebli, 'Knee Arthroscopy'
- Kieser CW, Jackson RW (2003). "Eugen Bircher (1882–1956) the first knee surgeon to use diagnostic arthroscopy". *Arthroscopy* 19 (7): 771–6. doi:10.1016/S0749-8063(03)00693-5. PMID 12966386.
- Böni T (1996). "[Knee problems from a medical history viewpoint]" (in German). *Ther Umsch* 53 (10): 716–23. PMID 8966679.
- Watanabe M (1983). "History arthroscopic surgery". In Shahriaree H. *O'Connor's Textbook of Arthroscopic surgery* (1st ed.). Philadelphia: J.B. Lippincott.
- Jackson RW (1987). "Memories of the early days of arthroscopy: 1965–1975. The formative years". *Arthroscopy* 3 (1): 1–3. doi:10.1016/S0749-8063(87)80002-6. PMID 3551979.
- Metcalf RW (1985). "A decade of arthroscopic surgery: AANA. Presidential address". *Arthroscopy* 1 (4):221–5. doi:10.1016/S0749-8063(85)80087-6. PMID 3913437.
- Allen FR, Shahriaree H (1982). "Richard L. O'Connor, M.D., 1933–1980" (PDF). *J Bone Joint Surg Am* 64 (2):315.
- Spiers ASD, Meagher T, Ostlere SJ, Wilson DJ, Dodd CAF. Can MRI of the knee affect Arthroscopy practice? A prospective study of 58 patients. *J Bone Joint Surg (Br)* 1993;75(b):49-52.
- Ruwe PA, Wright J, Randall RL, Lynch JK, Johl P, Mc Carthy. Can MR Imaging effectively replace diagnostic Arthroscopy? *Radiology* 1992;183:335-339.
- Noble J: Unnecessary Arthroscopy. *Editorial J Bone Joint Surg (Br)* 1992;74B:797-799.
- Elvenes J, Jerome CP, Reikeras O, Johansen O. MRI as a screening procedure to avoid Arthroscopy for meniscal tears. *Arch Orthop Trauma Surg* 2000;120 (1-2):14-16.
- Pappenport ED, Mehta S, Weislander SB, Lausten GS, Thomsen HS. MR Imaging before Arthroscopy in knee disorders? *Acta Radiol* 1996;37(5) 602-609.
- Kaplan PA, Walker CW, Kilcoyne RF, Brown DE, Tusek D, Dussault RG. Occult fractures patterns of the knee associated with ACL tears. Assessment with MR Imaging. *Radiology* 1992;183:835-838.
- Hollinshead WH. *Anatomy for surgeons*, vol 3, 3rd Ed. New York: Harper and Row, 1982;563-583.
- Remer EM, Fitzgerald SW, Friedman H, Rogers LF, Hendrix RW, Schafer MF. ACL injury: MR diagnosis and patterns of injury. *Radiographics* 1992;12:901-915.
- Gentili A, seeger LL, Yao L, DoHM. ACL tear: Indirect sign at MRI: *Radiology* 1994;193:835-840.
- Mink JH, Levy T, Crues JV. Tears of the ACL and menisci of the knee: MR evaluation. *Radiology* 1988;167:769-774.
- Vahey TN, Broome DR, Keyes KJ, Shelbourne KD. Acute and Chronic tears of the ACL. Differential features of MR Imaging. *Radiology* 1991;181:251-253.
- Tung GA, Davis LM, Wiggins ME, Fadale PD. Tears of the ACL: Primary and Secondary signs at MR Imaging. *Radiology* 1993;188:661-667.
- Mc Cauley TR, Moses M, Kier R, Lynch JK, Barton JW, Johl P. MR diagnosis of tears of ACL of the knee: importance of ancillary findings. *AJR* 1994;162:115-119.
- Schweitzer ME, Cerville V, Kursunoglu Brahne S, Resnick D. The PCL line: an indirect sign of ACL injury. *Radiology* 1999;213:705-708.
- Chan WP, Peterfy C, Fritz RC, Genant HK. MR diagnosis of complete tears of the ACL of the knee: Importance of anterior subluxation of tibia. *AJR* 1994;162:355-360.
- Vahey TN, Hunt JE, Shelbourne KD. Anterior translocation of the tibia. MR Imaging: A secondary sign of ACL tear. *Radiology* 1993;187: 817-819.
- Murphy BJ, Smith RL, Uribe JW, Janecki CJ, Hetchman KS, Mangasarin RA. Bone signal abnormalities in posterolateral tibial and lateral femoral condyle in complete tears of ACL: a specific sign? *Radiology* 1992;182:221-224.
- Kaplan PA, Gahl RH, Dussault RG, Anderson MW, Diduch DR. Bone contusions of the posterior lip of the medial tibial plateau (contrecoup injuries) & associated internal derangements of the knee at MR Imaging. *Radiology* 1999;211(3):747-753.
- Arndt WF, Traux AL, Barnett FM, Simmons GE, Brown DC. MR diagnosis of bone contusions of knee: comparison of coronal T₂ weighted FSE with Fat Sat & FSE STIR images with conventional STIR images. *AJR* 1996;166:119-124.
- Sonin AH, Fitzgerald SW, Friedman H, Hoff FL, Hendrix RW, Rogers LF. PCL injury: MR Imaging diagnosis and pattern of injury. *Radiology* 1994;190:455-458.

38. Geissler WB, Whipple TL. Intraarticular abnormalities in associated PCL injuries. *Am J Sports Med.* 1993;21:846-854.
39. Cherney S. The Knee. Principles of Orthopaedic practice, vol.2. 2nd edition, New York: McGraw Hill, 1989;1283-1380.
40. Schweitzer ME, Tran D, Deely DM, Hume EL. Medial collateral ligament injuries: evaluation of multiple signs, prevalence and location of associated bone bruises and assessment with MR Imaging. *Radiology* 1995;194:825-829.
41. Yao L, Dungan D, Seeger LL. MR Imaging of Tibial collateral ligament injury: Comparison with clinical examination. *Skeletal Radiology* 1994;23:521-524.
42. Rubin DA, Kneeland JB, Listerud J, Underberg E, Davis SJ. MR diagnosis of meniscal tears of the knee: Value of FSE vs conv SE Pulse sequences. *AJR* 1994;162:1131-1138.
43. Stoller DW, Martin C, Crues JV, Kaplan L, Mink JH. Meniscal tears: Pathologic correlation with MR Imaging. *Radiology* 1987;163:731-735.
44. Crues JV, Mink JH, Levy T, Lotysch M, Stoller DW. Meniscal tears of the knee. Accuracy of MR Imaging. *Radiology* 1998;164:445-448.
45. Lotysch M, Mink JH, Schwartz SA. Magnetic resonance imaging in the detection of meniscal injuries. *Magnetic resonance imaging* 1986;4:94.
46. Levinson ME, Baker BE. Prearthrotomy diagnostic evaluation of the knee: Review of 100 cases, diagnosed by Arthrography and arthroscopy. *AJR* 1980;134:107-114.
47. Raunest J, Hotzinger H, Burring KF. MRI and Arthroscopy in detection of meniscal derangements. *Arthroscopy* 1994;10:624-630.
48. Weiss KL, Morehouse HT, Levy IM. Sagittal MR images of the knee: A low signal band parallel to the PCL caused by a displaced bucket handle tear. *AJR* 1991;156:117-119.
49. Singson RD, Feldman F, Staron R, Kieman H. MR Imaging of the displaced bucket handle tear of the medial meniscus. *AJR* 1991;156:117-119.
50. Wright DH, Desmet AA, Norres M. Bucket handle tears of the medial and lateral menisci of the knee: Value of MR Imaging in detecting displaced fragments. *AJR* 1995;165:621-625.
51. Helms CA, Laorr A, Cannon WD. The absent bow-tie sign in bucket handle tears of the menisci in the knee. *AJR* 1998;170(1):57-61.
52. Watt S, Tonya H, Nigel R. The value of the absent bow-tie sign in MRI of bucket handle tears. *Clinical Radiology* 2000;55:622-626.
53. Weiner B, Rosenberg N. Discoid medial meniscus associations with bone changes in the tibia. *J Bone Joint Surg (AM)* 1974;56: 171-176.
54. Mink JH, Levy T, Crues JV. Tears of the anterior cruciate ligaments and menisci of the knee. MR Imaging evaluation. *Radiology* 1998;167:769-774.
55. Arthur DeSmet, Norris MA, Yandow DR, Quintana FA, Graf BK, Keene JS. *AJR* 1993;161:101-107.
56. Araki Y, Ootoni F, Tsukaguchi I. MR diagnosis of meniscal tears of the knee: Value of axial three dimensional fourier transformation GRASS images. *AJR* 1992;158:587-590.
57. Fischer SP, Fox JM, Del Pizzo W et al. Accuracy of diagnosis from magnetic resonance imaging of the knee: A multi-centre analysis of one thousand and fourteen patients. *J Bone Joint Surg (Am)* 1991;73 A:2-10.
58. Carrino JA, Schweitzer ME. Imaging of sports-related knee injuries. *Radiology clinics of North America* 2002;40:181-202.
59. Yao L, Gentili A, Lee K. Partial ACL rupture: An MR diagnosis? *Skeletal Radiology* 1995;24:247-251.
60. Umans H, Wimphfeimer O, Haramati N et al. Diagnosis of partial tear of the anterior cruciate ligament of the knee. Value of MR Imaging. *AJR* 1995;165:893-897.
61. La Prade RF, Burnett QM, Veenstra MA, Hodgman CG. The prevalence of abnormal MR findings in asymptomatic knees. *Am J Sp Med* 1994;171:761-766.
62. Mansfield GT, Youngberg RA, Warme W, Pitcher JD, Nguyen PL. Potential cost savings of MR Imaging obtained before arthroscopy of the knee: Evaluation of 50 consecutive patients. *AJR* 1997;168: 913-918.
63. Bonamo JJ, Saperstein A. Contemporary magnetic resonance imaging of the knee: the orthopaedic surgeon's perspective. *Mag Res imaging clinics Of North America* 1994;2:481-495.
64. Quinn SF, Brown TF. Meniscal tears diagnosed with MR Imaging versus Arthroscopy: How reliable a standard is Arthroscopy? *Radiology* 1991;183:843-847.
65. Santosh Kumar, Arun Bansal: A Comparative Study of Accuracy of Clinical Examination, MRI & Arthroscopy Findings in Cruciate Ligament and Meniscal Injuries of the Knee; *Indian Journal of Basic & Applied Medical Research*; December 2011: Issue-1, Vol.-1, P. 106-113.
66. Abhi A. Mane, P.G. Kulkarni: To study and evaluate the MRI and arthroscopic findings in knee problems with special attention towards false positive & false negative reports; *The Journal of Maharashtra Orthopaedic Association* 2013;8(4):17-21.
67. Saurav Singla, Nitin Kansal: Sensitivity and specificity of MRI versus arthroscopy in internal derangement of knee; *International Journal of Scientific and Research Publications*, Volume 3, Issue 4, April 2013 | ISSN 2250-3153.
68. Nilton Orlando Júnior, Marcos George de Souza Leão and Nelson Henrique Carvalho de Oliveira: Diagnosis of knee injuries: comparison of the physical examination and magnetic resonance imaging with the findings from arthroscopy; 10.1016/j.rboe.2015.10.007.