

Calcinosis cutis of usual and unusual sites: An eight year retro-prospective study in a tertiary teaching hospital in Western Uttar Pradesh, India

Alok Mohan^{1,*}, Shruti Singh², Veena K. Sharma³, Purva Sharma⁴, Swarn Kaur⁵

^{1,2}Associate Professor, ^{3,5}Professor, ⁴Junior Resident, Dept. of Pathology, ^{1,3,4}Muzaffarnagar Medical College, Muzaffarnagar U.P., ²U.P. Rural Institute of Medical Sciences & Research, Saifai, U.P., ⁵Govt. Medical College, Khanpur Ialan, Sonapat, Haryana

***Corresponding Author:**

Email: dr.alokmohansinha@gmail.com

Abstract

Introduction: Calcinosis cutis is characterized by deposition of calcium in the skin. Case reports of calcinosis cutis form a wonderful data in clinical and pathological literature.

Aims and Objectives: The aim of the present study was to highlight the various clinicopathological aspects of calcinosis cutis lesions of various sites in our archives.

Materials and Methods: We performed an analysis of clinicopathological features of all diagnosed cases of calcinosis cutis from our archives. This was a retro-prospective type of study for eight years i.e. from July 2008- June 2016.

Observation and Results: In our study we studied 18 cases of calcinosis cutis from various sites. A few cases were unusual in terms of locations, size and presentation. Most common site was scrotum. Wide surgical excision was the treatment of choice. Histopathological diagnosis was rarely difficult. Histochemical Von Kossa staining was done in all cases for confirmation.

Conclusion: The results from the present study displayed the various presentations, locations and variability on histopathological architecture, thus highlighting the various clinicopathological aspects of calcinosis cutis lesions. Special histochemical staining is required for confirmation.

Keywords: Calcinosis cutis, Dystrophic calcification, Histopathology, Metastatic calcification.

Introduction

Deposition of calcium salts in tissues, other than osteoid or enamel, is known as Heterotopic calcification. Calcinosis cutis is the deposition of calcium in the skin and subcutaneous tissues.⁽¹⁾ Various types of calcinosis cutis have been described based on histology and location.⁽²⁾ There are mainly four forms of calcinosis cutis-

1. Metastatic calcinosis cutis
2. Dystrophic calcinosis cutis
3. Idiopathic calcinosis cutis
4. Subepidermal calcific nodule

Metastatic calcinosis cutis: develops as a result of metabolic disorders resulting in hypercalcemia or hyperphosphatemia. Instances of cutaneous metastatic calcinosis are rare. Most patients are related to renal hyperparathyroidism and osteodystrophy. The cutaneous lesions are of variable presentation- may consist of firm white papules⁽³⁾ or papules in linear arrangement⁽⁴⁾ or symmetric nodular papules⁽⁵⁾ or papules and nodules from which a granular, white substance can be expressed.⁽⁶⁾

Histopathological findings show deposition in histiocytes. It deposits as small granules or small deposits in dermis and as massive deposits in subcutaneous fat. Foreign body giant cell reaction, inflammation and occasionally fibrosis may be present.⁽⁵⁾

Dystrophic calcinosis cutis: In dystrophic calcinosis cutis, the calcium is deposited in previously damaged tissue. The values of serum calcium and phosphorus are

normal, and the internal organs are spared. There may be numerous large deposits of calcium (calcinosis universalis) or only a few deposits (calcinosis circumscripta).

Idiopathic calcinosis cutis: resembles cases with dystrophic calcinosis cutis but no underlying disease is detected.^(7,8,9) Tumoral calcinosis is regarded as a special manifestation of idiopathic calcinosis.

Idiopathic calcinosis of scrotum consists of multiple asymptomatic nodules⁽¹⁰⁾ of the scrotal skin. Earlier studies showed that some areas of calcium deposition were surrounded by foreign body giant cell reaction, while other areas were not. Recent studies by few researchers pointed out that calcinosis of scrotum represents the end stage of dystrophic calcification of scrotal epidermal cysts. Thus, lesions were eventually originated from cysts.^(11,12)

Another opinion was that eccrine duct milium is the origin because of positivity for CEA, which is the marker of sweat glands.⁽¹³⁾ Another author found various types of cysts- epidermal, pilar and intermediate cysts showing different degrees of calcification.⁽¹⁴⁾

Subepidermal calcified nodule: also known as cutaneous calculi. Usually presents as a single, small, hard nodule. Sometimes 2-3, or numerous nodule may be present.^(15,16,17) Most patients are children. Some babies have nodules since birth.⁽¹⁸⁾ Histopathologically, calcified nodule is located predominantly in uppermost dermis. If deposit is large, deeper layers of dermis are also involved. Calcium is deposited mostly as closely aggregated globules. Sometimes, homogenous masses of

calcified material are seen. Macrophages and foreign body giant cells arrange around these masses.^(16,17) Epidermis is often hypertrophic. Calcium granules may be observed within the epidermis, which is indicative of trans epidermal elimination.^(19,20) Primary event seems to be the formation of large, homogeneous masses that undergo calcification and breakup into numerous calcified globules. The origin of the homogeneous masses is obscure.^(17,18,21)

Aims

The aim of the present study was to highlight the various clinicopathological aspects of lesions of calcinosis cutis in our archives.

Materials and Methods

The material for the present study was collected from the department of Pathology, Muzaffarnagar Medical College and Hospital, Muzaffarnagar. This was a retro-prospective type of study in which eighteen cases were studied for eight years from July 2008- June 2016. All the relevant material like blocks and slides available in Pathology Department, MMCH were studied. Biochemical investigations, especially for serum Calcium, Phosphorus, Uric acid etc were noted from hospital records, wherever available.

We also studied all the relevant new excised lesions from the Department of Surgery and Dermatology which were sent for histopathology as a part of our prospective study (July 2011 - June 2016). The relevant clinical

history like age of the patient, duration of swelling, any rapid progression, development of pain etc. were recorded. Examination included both general clinical examination and examination of the swelling proper. Biochemical investigations, especially for serum Calcium, Phosphorus, Uric acid etc. were essentially requested and done. .

After removal of lesion, gross examination was carefully done and represented areas were cut into pieces, processed, blocks made, sections cut and stained with both Haematoxylin and Eosin and Von Kossa stain. Stained sections were subjected for histopathological examination.

Observations

We made our study on a total of eighteen cases of calcinosis cutis of various sites. (Table 1) In retrospective study (July 2008 - June 2011) 06 cases were studied and in prospective study 12 cases were studied (July 2011 -June 2016). Prospective cases were studied clinically, their fine needle aspiration cytology and biochemical tests were performed as far as possible and biopsies were studied histopathologically.

Maximum numbers of the cases were in 40-49 years of age group. Mean age is 46.16 years.

Thirteen cases were males (72.22 %) and 05 cases were females (27.78%). There was a significant variation in size of lesions ranging from few millimeters up to 4.8 centimeters.

Table 1: Distribution of cases on basis of age, sex, site and laboratory investigations.

S.no	Age (years)/ Sex	Site	Soliatry/ multiple	Size of lesions (cms)	FNAC done	Calcium levels	PO4 Levels	Uric acid levels
1	42/F	Scalp	Single	3.2	Done	Not done	Not done	Not done
2	48/M	Scrotum	Multiple	1-2.5	Not done	Not done	Not done	Not done
3	32/F	Scalp	Single	2.8	Done	Normal	Not done	Not done
4	47/M	Scrotum	Multiple	0.5-2.2	Not done	Normal	Not done	Not done
5	35/M	Scrotum	Multiple	0.5-2.0	Not done	Normal	Not done	Not done
6	76/M	Back	Single	2.5	Done	Normal	Normal	Raised
7	40/M	Elbow	Single	3.5	Done	Normal	Normal	Normal
8	50/M	Arm	Single	2.5	Done	Normal	Normal	Raised
9	38/F	Face	Single	1.5	Not done	Reduced	Not done	Not done
10	45/M	Knee	Single	3.5	Not done	Normal	Normal	Normal
11	32/M	Scrotum	Multiple	0.5-2.5	Not done	Normal	Normal	Not done
12	22/M	Hip	Single	4.8	Not done	Normal	Normal	Normal
13	65/M	Knee	Two	1.5,2.0	Done	Normal	Normal	Raised
14	69/F	Elbow	Single	2.5	Done	Reduced	Normal	Normal
15	80/M	Hip	Single	2.5	Done	Raised	Normal	Raised
16	48/M	Scrotum	Multiple	1.0-2.5	Not done	Normal	Not done	Not done
17	52/F	Shoulder	Single	2.0	Done	Normal	Normal	Not done
18	10/M	Hip	Single	3.5	Done	Normal	Normal	Not done

We encountered eleven cases of dystrophic calcification, six cases of idiopathic calcinosis (one case of tumoral calcinosis and five cases of idiopathic scrotal calcinosis), a single case of metastatic calcification.

Most common site involved in our study was scrotum, followed by hip region. FNAC was performed in ten out of eighteen cases (55.55%). Fine needle aspiration cytology (FNAC) revealed chalky white amorphous calcified deposits. Biopsy was done under general anesthesia. Hematoxylin & Eosin stain and Von Kossa stain were done.

Biochemical investigations done were serum Calcium, serum Phosphorus and Uric acid levels. Calcium levels were done in 16 cases. Serum Calcium levels came out to be normal in 13 cases, reduced in two cases and high in one case. Phosphorus levels were done in 11 cases came out to be within normal range. Serum Uric acid levels were done in only 08 cases. Serum Uric acid levels were found to be raised in 04 cases and normal in rest 04 cases.

Discussion

Calcinosis cutis is an entity that can present at variable age, size, sites and with variable pathogenesis. It can even be present at birth. It may present with variable case history e.g. as a simple case of post acne facial dystrophic calcification or as markedly deranged metabolic functions or as calcified epidermal cysts or as manifestation of life-threatening conditions or as a manifestation of tumour.

The only common finding in among all the variables is the deposition of calcium salts in the skin. In the present study histopathological examination of the biopsy revealed deposition of calcium salts which appear on H&E stained sections as basophilic substance. A foreign body giant cell reaction is found around large deposits of calcium.(Fig. 1)

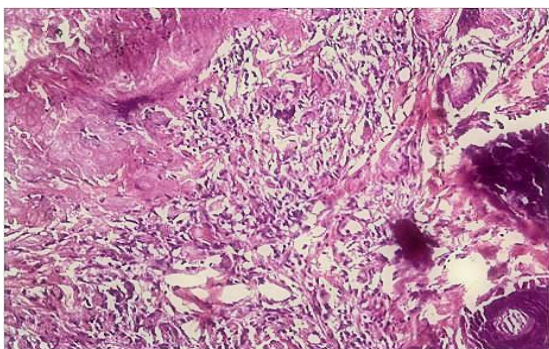


Fig.1: Calcinosis cutis with giant cell reaction (H&E x400)

Silver stain (Von Kossa) was positive. (Fig. 2). Diagnosis of calcinosis cutis was thus made.

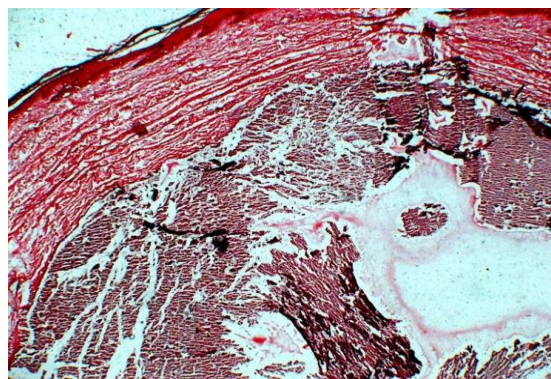


Fig. 2: Calcinosis cutis confirmed on Von Kossa stain (x400)

In the present study, the mean age of diagnosis was 46.16 years. Mohammad et al⁽²²⁾ did a study on 59 cases of calcinosis cutis. They diagnosed cases at a mean age of 50.7 years, which is comparable to our results.

Metastatic Calcinosis: We only found one case of this type, which resulted in settings of hypercalcemia. The patient was a 82 years old male with a nodular swelling of 2.5 cms size over hip. The cause of hypercalcemia was metastatic prostatic carcinoma to bones. Cutaneous metastatic calcinosis is rare. Common causes of hypercalcemia mentioned in literature are Primary hyperparathyroidism, excessive intake of vitamin D⁽²³⁾, excess intake of milk and alkali substances⁽²⁴⁾ and extensive destruction of bone through osteomyelitis or metastatic carcinoma.⁽²⁵⁾

Hyperphosphatemia occurs in chronic renal failure as a result of a decrease in renal clearance of phosphorus and is associated with a compensatory drop in the serum calcium levels. The low levels of ionized calcium in the serum stimulate parathyroid secretion, leading to secondary hyperthyroidism and to resorption of calcium and phosphorus from bone.

Dystrophic: manifests in dead, degenerated, diseased tissues. We found eleven cases of dystrophic calcification. Sites involved were scalp, back, elbow, arm, face, knee, hip and shoulder. There are a fair number of cases reported in medical literature from various usual and unusual sites.

The main reason of calcium deposition was local injury at the site, followed by chronic inflammatory process and lastly by ischemic injury. Valenzuela and Chung⁽¹⁾ also mentioned local trauma, chronic inflammation and hypoxic injury as common potential pathomechanisms.

Most common site of dystrophic calcification in our study came out to be upper extremity, followed by head and neck region. The main probable reasons were injury (due to injection by quacks, falls etc.).

Muhammad et al,⁽²²⁾ studied a case series of 59 cases of calcinosis cutis in females. Most common site they encountered was around hip region on both sides due to the weight bearing of water containers. Nanjuanaswamy

and Usman^(2,28) have mentioned cases of calcinosis cutis in gluteal region. We encountered a single case of dystrophic calcification around hip.

In the present study we encountered a case from face region. There was a nodule over the cheek which was secondary to facial acne. Cases from face have been reported by Kayhan et al, Sahu et al.^(27,28)

In the present study, we encountered a case of 10 years old boy with dermatomyositis. He had a swelling over the buttock area of hip region. The swelling was due to the deposition of calcium beneath the epidermis. He also had calcification of muscles and tendons. (Fig. 3)

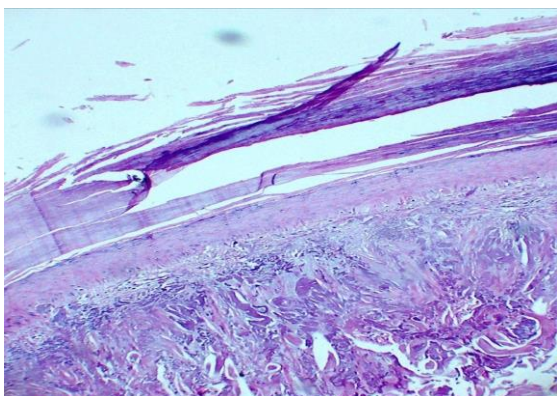


Fig. 3: Calcinosis cutis in a case of dermatomyositis (H&E x400)

Medical literature describes cases of collagen vascular diseases as an important cause of dystrophic calcinosis cutis. There may be universally numerous large calcium deposits (calcinosis universalis) or only a few deposits (calcinosis circumscripta). Calcinosis universalis occurs as a rule with dermatomyositis, but, exceptionally, it has also been seen in cases with systemic scleroderma. Large calcium deposits are seen in skin, subcutaneous tissues, muscles and tendons.⁽²⁵⁾ Calcinosis circumscripta occurs in patients with systemic scleroderma. Exceptionally, in cases of morphea.⁽²⁶⁾ CREST syndrome is manifestation of systemic scleroderma comprising of calcinosis, Raynaud's phenomenon, esophageal dysmotility, sclerodactyly and telangiectasia.⁽²⁷⁾ Calcium is deposited in areas of collagen degeneration and fatty tissue destruction. Histopathologically, granules or small deposits in the dermis and as massive deposits in the subcutaneous tissue.⁽²⁶⁾

A foreign body giant cell reaction is found around large deposits of calcium.⁽²⁸⁾ Rarely, SLE is associated with dystrophic calcinosis cutis.⁽²⁹⁾ Also seen in other connective tissue diseases, subcutaneous fat necrosis of newborn and Ehlers- Danlos disease.

Idiopathic Tumoral Calcinosis: Tumoral calcinosis consists of numerous large calcified subcutaneous masses that may be associated with papular and nodular skin lesions.⁽³⁰⁾ Massive spontaneous deposits of calcium salts are often seen over large joints in otherwise healthy

individuals. The disease is usually familial, associated with hyper-phosphatemia.^(31,32) Tumoral calcinosis, on histopathological examination, shows subcutaneous large masses of calcium surrounded by foreign body giant cell reaction.⁽³³⁾ Electron microscopically, calcium deposits came out to be of pleomorphic calcium phosphate (apatite) crystals.^(7,8)

We encountered one case of tumoral calcinosis. The patient was male with nodular swelling of 3.5 cms around knee joint. Muddegowda et al⁽³⁴⁾ studied a case of tumoral calcinosis in thoracic region. Lesion was 5x 3x1.5 cms. Histopathological findings were similar.

Idiopathic Scrotal: We got 05 cases of idiopathic scrotal calcinosis. (Fig. 4). Andola et al studied a case series of nine cases of idiopathic scrotal calcinosis.⁽³⁵⁾ Killedar et al studied four cases of idiopathic scrotal calcinosis, one of which had scrotal calcinosis involving the whole scrotum.⁽³⁶⁾ In our study patient's age ranged between 32 years -48 years of age, mean age being 42 years. Andola et al had age range from 26-65 years but the mean age was same as ours i.e. 42 years. Size of nodules varied from 0.5 cms to 2.5 cms. Andola et al encountered cases with nodule size varying from 0.5-3 cms which is again comparable.

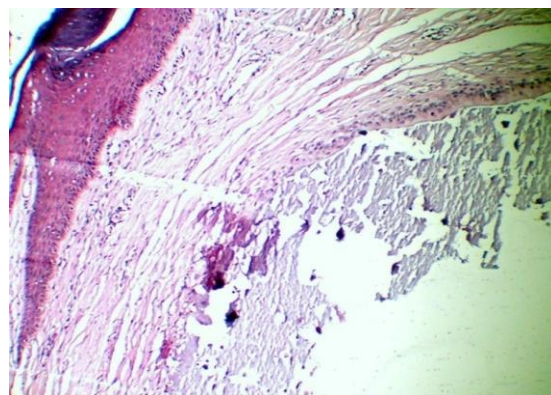


Fig. 4: Calcinosis cutis in a case of Idiopathic scrotal calcinosis (H&E x400)

Conclusion

Calcinosis cutis is prevalent in many cases but the diagnosed is often missed due to improper work-up. A clinical knowledge of calcinosis cutis is the first step towards the diagnosis of calcinosis cutis. A laboratory investigative work-up in the form of fine needle aspiration cytology, followed by histopathology and special staining techniques for calcium is necessary. Ancillary techniques like serum calcium levels, phosphorus levels, uric acid levels help. Further investigations are needed to find out any underlying abnormalities of calcium and phosphorus metabolism, collagen vascular diseases, renal insufficiency, malignant processes, excessive milk ingestion, vitamin D poisoning etc. This will result in diagnosis of many more cases.

References

1. Valenzuela A, Chung L. Calcinosis: pathophysiology and management. *Curr Opin Rheumatol.* 2015;27(6):542-8.
2. Nanjundaswamy NH. Calcinosis cutis: A rare cause for difficult airway. *Anesth Essays Res.* 2015; 9(3):405-7.
3. Posey RE, Ritchie EB. Metastatic calcinosis cutis with renal hyperparathyroidism. *Arch Dermatol* 1967;95:505.
4. Putkonen T, Wangel GA. Renal hyperparathyroidism with metastatic calcification of the skin. *Dermatologica* 1959;118:127.
5. Kolton B, Pedersen J. Calcinosis cutis and renal failure. *Arch Dermatol* 1974;110:256.
6. Eisenberg E, Bartholow PV Jr. Reversible calcinosis cutis. *N Engl J Med* 1963;268:1216.
7. Paegle RD. Ultrastructure of mineral deposits in calcinosis cutis. *Arch Pathol* 1966;2:474.
8. Cornelius CE III, Tenenhouse A, Weber JC. Calcinosis cutis. *Arch Dermatol* 1968;98:219.
9. Hain S, Friedman- Birnbaum R. Two cases of circumscribed calcinosis. *Dermatologica* 1971;143:111.
10. Shapiro L, Platt N, Torres- Rodriguez VM. Idiopathic calcinosis of the scrotum. *Arch Dermatol* 1970;102:199.
11. Bode U, Plewig G. Klassifikation follikularer zysten. *Hautarzt* 1980;31:1.
12. Swinehart JM, Golitz LE. Scrotal calcinosis: dystrophic calcification of epidermoid cysts. *Arch Dermatol* 1982;118:985.
13. Dare AJ, Axelsen RA. Scrotal calcinosis: origin from dystrophic calcification of eccrine milia. *J Cutan Pathol* 1988;15:142.
14. Song DH, Lee KH, Kang WH. Idiopathic calcinosis of the scrotum. *J Am Acad Dermatol* 1988;19:1095.
15. Shmunes E, Wood MG. Subepidermal calcified nodules. *Arch Dermatol* 1972;105:593.
16. Woods B, Kellaway TD. Cutaneous calculi. *Br J Dermatol* 1963;75:1.
17. Tezuka T. Cutaneous calculus: its pathogenesis. *Dermatologica* 1980;161:191.
18. Winer LH. Solitary congenital nodular calcification of the skin. *Arch Dermatol Syph* 1952;66:204.
19. Eng AM, Mandrea E. Perforating calcinosis cutis presenting as milia. *J Cutan Pathol* 1981;8:247.
20. Duperrat B, Goetschel G. Calcification nodulaire solitaire congenital de la peau. *Ann Dermatol Syphigr* 1963;90:283.
21. Steigledeger GK, Elschner H. Lokalisierete calcinosis. *Hautarzt* 1957;8:127.
22. Mohammad IA, Schneider J, Schiffer R, Hussein J, Hailu J, Eshete M, Abate F, Sabir A, Habte D. Calcinosis cutis- a series of 59 consecutive cases confined among women. *Eadt Afr Med J.* 2013;90(4):142-6.
23. Wilson CW, Wingfield WL, Toone EC Jr. Vitamin D poisoning with metastatic calcification. *Am J Med* 1953;14:116.
24. Wermer P, Kuschner M, Riley EA. Reversible metastatic calcification associated with excessive milk and alkali intake. *Am J Med* 1953;14:108.
25. Mulligan RM. Metastatic calcification. *Arch Pathol* 1947;43:177.
26. Usman N. Calcinosis cutis. *Arch Med Health Sci* 2015;3:354-5.
27. Kayhan TC, Temiz P, Ermertcan AT. Calcinosis cutis on the face. *Indian J Dermatol Venerol Leprol* 2009;75:180-1.
28. Sahu SK, Gupta N, Vohra S. Calcinosis cutis secondary to facial acne vulgaris: A rare complication. *Indian Dermatol Online J* 2015;6:37-9.
29. Velayos EE, Masi AT, Stevens MB, et al. The "CREST" syndrome: comparison with systemic sclerosis (scleroderma). *Arch Intern Med* 1979;139:1240.
30. Whiting DA, Simson IW, Kallmeyer JC, et al. Unusual cutaneous lesions in tumoral calcinosis. *Arch Dermatol* 1970;102:465.
31. Pursley TV, Prince MJ, Chausmer AB, et al. Cutaneous manifestations of tumoral calcinosis. *Arch Dermatol* 1979;115:1100.
32. Mozaffarian G, La fferty FW, Pearson OH. Treatment of tumoral calcinosis with phosphorous deprivation. *Ann Intern Med* 1972;77:741.
33. Reich H. Das Teutschlaender Syndrom. *Hautartz* 1963;14:462.
34. Muddegowda PH, Lingegowda JB, Ramachandrarao RK, Konapur PG. Calcinosis cutis: Report of 4 cases. *J Lab Physicians* 2011;3:125-6.
35. Andola SK, Karangadan S, Patil S. Idiopathic scrotal calcinosis: A case series. *Indian Journal of Dermatopathology and Diagnostic Dermatopathology.* 2014;1:86-9.
36. Killedar MM, Shivani AA, Shinde U. Idiopathic Scrotal Calcinosis. *Indian J Surg.* 2016;78(4):329-30.