

Protrusive Bite Registration, TENS, vertical, a combination bite: what is the answer for a snoring/OSA appliance?

Dr. Derek Mahony

BDS, MScOrth, DOrth RCS, MOrth RCPS, MOrth RCS, FRCD, MOrth RCS/CDS, FICD, IBO

Dr. Edmund A. Lipskis

DDS, MS, DABCP, FAACP, FAAFO, FIAO

I would like to thank Dr Ken Lipworth for giving me the idea to write this article. After attending my recent OSA symposium, Ken told me that he, and many other course participants, were confused about the role of TENS, in establishing the “correct bite” for a snoring appliance.

“My understanding is that the TENSing will fatigue the muscle sufficiently to get to a point where the condyles will be in a neutral position (analogous to the effect of a deprogrammer) and will also give us a neutral vertical dimension. If this is correct, I don't understand the next step - how to establish the protrusive position from the silicone bite.”

To answer this question, you have to understand that there are actually two general philosophies on how to take a bite for a sleep appliance. Both have evidence to support their use. In the case of using a TENS (like an “LVI” neuromuscular protocol), the philosophy essentially expresses a belief that when the mandible is repositioned, from a condylar perspective and divine proportion sense, function becomes normalized, parafunction diminishes and airways are maximally opened. This, in some patients, occurs without

any forced anterior repositioning. If done correctly, followed up with a bite registration technique (such as a sibilant phonetic bite,¹ you get a 3-dimensional repositioning of the mandible. When evaluated, this bite repeatedly positions the mandible to align the skeletal midline, levels the body of the mandible (as much as anatomy allows) and positions the condyles correctly in the TM Joint (improving pitch, yaw and roll). Sometimes, there is an anterior repositioning that occurs, but almost always there is vertical repositioning. This vertical repositioning isn't always the same on the left and the right. Dr Steve Olmos, Dr Ed Lipskis and other contributors, are beginning a series of studies. One of these studies is intended to measure the difference between the results achieved with sleep appliances (using this type of bite technique) compared to simple selection of a vertical with a frankly arbitrary protrusion. The results, from a sleep disordered breathing standpoint, seem to be about equal. The advantage of the sibilant bite is that the TM Joints are ideally aligned.

The protrusive bite technique, usually promoted by those in the Dental Sleep Community, is the one most people are

familiar with. You take something like a George Gauge (Fig. 1) and, based on what vertical height you need for the appliance, you choose either 2 mm or 5 mm of vertical opening. (Fig. 2).

This “vertical” selection usually has nothing to do with the patient. No cant correction is attempted. The patient is usually asked to protrude as far as they can and then the bite is registered anywhere from 50% to 70% of maximum protrusion (Fig. 3-12 demonstrate the George Gauge bite technique).

The OSA appliance is then made to this position. The thought process with this technique comes from the incredible success achieved in correcting apnoea via bi-maxillary advancement Orthognathic surgery. In this surgery, both the maxilla and mandible are anteriorly repositioned. Obviously we can't reposition the maxilla, but the mandible can be brought forward using a dental appliance. This moves the hyoid and the base of the tongue forward to open the airway. With this technique, you generally need to titrate to find the best position with regards to airway. With the TENS technique, however, very little titration is needed. With the protrusive bite




Fig. 1. A George Gauge.



Fig. 2. A George Gauge: Disposable vertical bite fork options, 5mm on the left & 2 mm on the right.

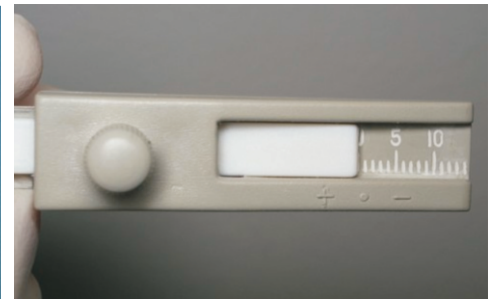

Fig. 3. George Gauge “zeroed” as a step in determining desired protrusive recording position.

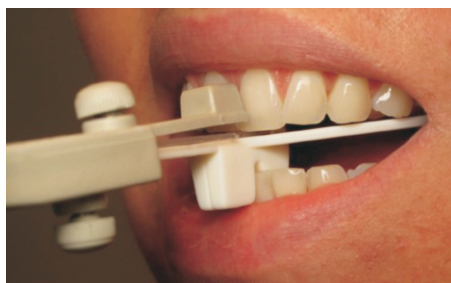


Fig. 4. Patient biting in the “zero” position.

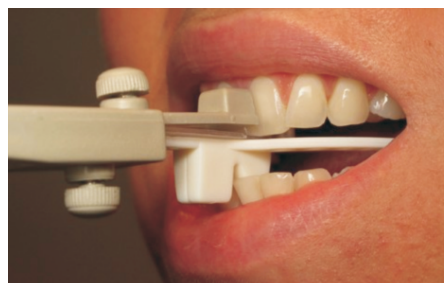


Fig. 5. Patient biting in their most protrusive position possible

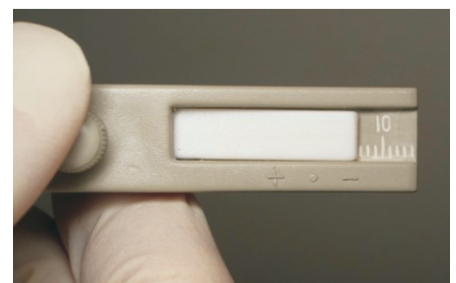


Fig. 6. Recorded protrusive position in mm.

technique, you are more likely to create TMD and muscular issues. Either technique can leave the patient with a posterior open bite, upon awakening.

Obstructive sleep apnoea (OSA) is characterized by recurrent obstructions of the upper airway, often resulting in oxygen desaturation and arousal from sleep.² Continuous positive airway pressure (CPAP) is generally considered the "gold standard" of treatment for OSA.³ CPAP, however, is not always well-tolerated by patients and it is used less frequently than required.⁴ As an alternative, oral appliances may be prescribed to prevent upper airway collapse during sleep, especially for mild to moderate OSA cases.^{5,6}

In a recent evidence-based review on the use of oral appliances for the treatment of OSA, Ferguson et al.⁷ indicated that more information was needed on the design elements. He based this statement on signs (polysomnographic variables) and symptoms (e.g., reports of snoring and excessive daytime sleepiness). According to the review, a larger mandibular protrusion will produce a greater decrease in OSA events. Short-comings in the available literature and conflicting data, however, do not allow definitive conclusions to be drawn, especially when it relates to the vertical dimension.⁸

Since the role of vertical opening remains a controversy (i.e., negative or positive influence on the OSA condition),⁹ it is important to appreciate this variable when taking a bite for a mandibular repositioning appliance (MRA).

MRAs vary in four major areas: freedom of mandibular movement; amount and rigidity of dental coverage; amount of mandibular advancement; and amount of bite opening. Each of these areas appears to affect the appliance's efficacy, and safety. The main potential detrimental effect of MRAs is occlusal changes. This paper presents biological and mechanical considerations in an attempt to determine the optimum parameters for each of the MRA variations. The MRA must be constructed in a manner and with a material that secures the mandible in its optimum position. The optimum mandibular position needs to be captured and transferred to the articulator with an accurate construction bite.

To better understand how the dental system can effect distant bodily alterations, in disease and health processes, we must consider the 68 pairs of muscles above and below

the mandible.¹⁰ Together, these 136 muscles determine head, cervical, shoulder and jaw posture. The Dental Research Group of Chicago began studying the functional movements of the mandible during the 1940s.^{11,12} This research shed new light on mandibular and condylar movements.¹³ As a student of physics and engineering, Casey Guzay, put these dental findings into a sophisticated series of drawings. Casey called this, The Quadrant Theorem.¹⁴ In this theory, the muscles controlled the pivotal axis of the mandible. This occurs at the dens i.e. between the atlas and axis vertebrae.^{13,15,16,17}

Therefore, the mandibular dysfunction negatively effects a posturing of C1 and C2.¹⁵ These vertebrae are intimately related to spinal and head posturing and malposturing of these key vertebrae can affect the spine and head.

The malposturing of C1 and C2, through the dental malocclusion and the resultant mandibular dysfunctioning, torques the dura mater. This is related to the frontal and dorsal attachments of C1, C2 and C3. Torquing of the dura may cause scoliosis; cervical hypolordosis (military neck); thoracic hyperkyphosis (hump back); excessive lumbar lordosis (sway back); rotation of the pelvis causing uneven leg length; and uneven shoulder height, etc. It also aids in creating head tilt through the dura's attachment around the foramen magnum. The cranial bones, because of their multiple attachments to the dura, can also be malpostured through this torquing stress of the dura mater.¹⁵

When these 136 muscles are allowed to assume a more physiologically balanced relationship i.e. by correcting the malocclusion and correct vertical (free way space), the patient's head immediately assumes an upright posture, the shoulders level off and pelvic rotation ceases. This allows the leg length to equalize and overall body posture to normalize. These changes are sometimes instantaneous, but may be reversed by altering the occlusal support.¹⁸

The jaws, teeth and their supporting tissues (the muscles of mastication and the temporomandibular joint) are all components of the masticatory system. However, these are not the only structures necessary for activities such as speech, respiration, chewing and swallowing. Whole systems of muscles in the head, neck, and shoulder girdle are also affected by these actions. In the neck, the hyoid bone forms another integral part of the

dental mechanism. On a smaller scale, the hyoid bone resembles the U-shaped mandible and together with the mandible (and the anterior part of the shoulder girdle), forms a series of bow-shaped structures with interconnecting musculature. This musculature works in conjunction with the musculature above the mandible and together, the two create a suspensory apparatus that controls mandibular function and aids in head balance.

Besides the hyoid mechanism, the neck contains vital circulatory vessels, i.e. the trachea, larynx, thyroid and cricoid cartilages, with their accompanying musculature. Taken together, these structures provide a link between the head and chest systems. Therefore, if there is maladjustment of any of these structures, because of incorrect positioning or functioning of the mandible, adverse reactions may be visible. These include interruption of proper function when swallowing, speech, hearing, breathing and other important functional processes.

The AP (protrusive) bite

To take a bite registration, with the George Gauge, first place the George Gauge in the patient's mouth without the bite fork attachment. Centre the lower incisor notch over the anterior teeth. Cinch up the lower incisor clamp to firmly grip these teeth and tighten the lower turn screw to secure this position.

Remove the instrument from the mouth. Insert the bite fork, into the body of the gauge and slide it until the indicator end is at the 0 point on the millimetre scale (Fig. 3). Lightly tighten the upper turn screw. Return the instrument to the mouth, with the lower incisor notch centred over the lower midline. Instruct the patient to close into the upper incisor notch, with the mid-line indicator between the central incisors (Fig. 4). Modify the upper notch with an acrylic bur if the incisors are rotated, or if the incisal edges are excessively thick.

While the patient is firmly biting into the notches, instruct them to slide the jaw forward as far as possible (Fig. 5). Note the + reading on the millimeter scale (Fig. 6).

Then ask the patient to move the jaw back as far as they can (Fig. 7). Note the position on the end of the millimeter scale (Fig. 8).

Add these two numbers without regard to the + and - signs. The total is the patient's protrusive range. Multiply that sum by 0.7 (70%), and add this number to the minus

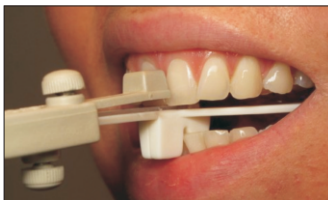

Fig. 7. Patient biting in the most retruded position possible for them.

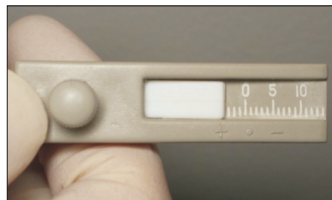


Fig. 8. Recorded retruded position in mm.

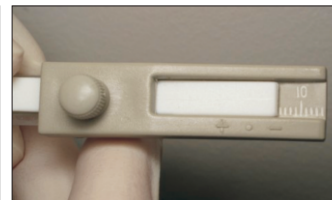

Fig. 9. Gauge locked at calculated desired protrusive position for appliance construction (usually 50 to 70% of the distance from most retruded to most protruded).

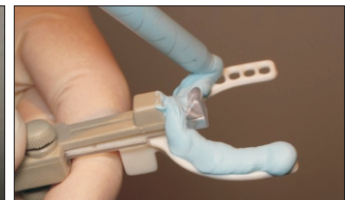


Fig. 10. Bite registration paste applied to the top of the bite fork.

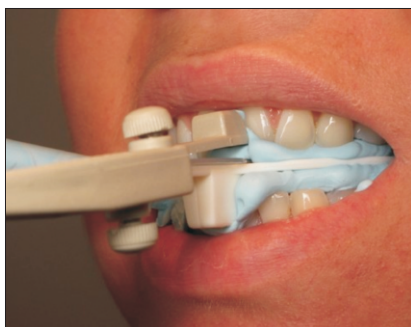


Fig. 11. Registration paste is applied to the lower teeth, the bite fork inserted and the patient asked to bite into the pre-selected position. Any gaps in the registration material are filled in to make indexing clear for lab mounting of the case.

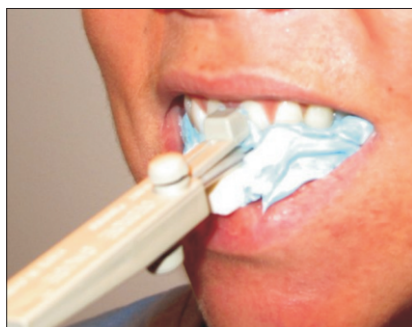

Fig. 12. Allow the bite registration to set, remove the apparatus from the patient's mouth, unscrew the bite fork and send it to the lab along with accurate dental casts.



Fig. 13. TENS unit applied.

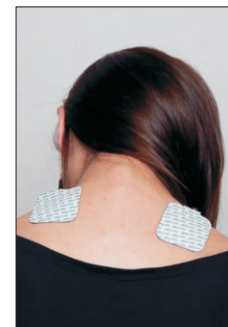

Fig. 14. TENS Typical pad secondary placements.

number (retrusive position). The result is the number at which you will preset the George Gauge (Fig. 9).

As an example, your patient can protrude to the +6 mark on the millimeter scale and can retrude to -4. Therefore, his protrusive range is 10mm. Take 70% of that range, which is 7mm, and add it to the most retruded position, which is -4. This gives you a setting of +3. Slide the marking end of the bite fork over the millimeter scale until its indicator end rests over the +3 mark. Then tighten the upper turn screw.

George Gauge tips

- Repeat the measurement three times to ensure consistency.
- For most patients two thirds of centric to maximum protrusion is a valid formula. However, if there are TMD problems, it may be necessary to advance the mandible by gradually titrating forward.
- Once a position is obtained, ask the patient to hold in that position for 2-3 minutes and seek their feedback. Adjust if necessary.

Taking the Bite Record

When taking the bite record, full occlusal coverage is essential. Apply the bite material directly to the lower teeth, going back to the most posterior tooth. Then apply the bite material to the top of the bite fork, which is attached to the George Gauge (Fig. 10).

Return the gauge to the mouth with the lower incisor notch centered over the midline and allow the patient to bite into the upper groove (Fig. 11). This position should not be uncomfortable for the patient to hold. If it is uncomfortable, take the bite in a slightly less protrusive position.

When the bite registration material has set (Fig. 12), unscrew the upper turn screw and remove the bite fork. Send the bite fork, and impressions/models, to "your certified lab of preference". Keep the body of the George Gauge, to sterilize and reuse.

The Neuromuscular Bite

TENS (Fig. 13 and 14) is commonly used by "neuromuscular" dentists to establish a vertical dimension for their full mouth reconstructive cases. Although I understand the principles behind this, it has never made much sense to me i.e., to tire out the elevator

musculature to establish a vertical dimension. What is so natural about that? If you carefully look at some of these reconstructive cases, the teeth are very large incisogingivally, and it doesn't look natural.

In regards to dental sleep medicine, the importance of vertical dimension has had mixed reviews. Pitsis, et al¹⁹ stated that "the amount of bite opening does not have a significant impact on treatment efficacy, but does have an impact on patient acceptance". Dr Isono,²⁰ on the other hand, showed an improved response with more vertical (up to a certain amount). The increased (posterior) vertical dimension does, however, have greater use in TMD cases. In these cases, decompression is often needed to reduce symptoms of capsulitis or retrodiscitis.

The famous physical therapist, Mariano Rocabado, recently told me that an increased vertical dimension causes an extension of the cranium. This may result in stress of the sub-occipital musculature and lead to supra orbital headaches. He attributes this to, amongst other factors, compression of the greater occipital nerve. So I must caution the dentist NOT to create too much vertical. This is also the case with too much horizontal!

There are some studies that prove neuromuscular diagnostic devices do not work. Dao et al²¹ tested Myomonitor model J3 and made recordings with intra-muscular electrodes. They concluded that TENS stimulus acts only in the periphery, without the participation of the central nervous system. Dao went on to say that the ability of the instrument to produce a reflex controlled occlusal position is highly questionable. There is no evidence that reflex jaw closure could ever be used to establish a physiologic occlusal position.

Baba et al²² published a review on TMD

1983-1998. Methods discussed include pressure-pain threshold, EMG, jaw tracking and Joint sound Vibration Analysis (JVA). EMG activity has not been demonstrated to relate to pain or TMD. High individual variation results in poor reliability and low sensitivity. Thus, EMG alone is not a suitable diagnostic device. Joint sound-vibration analysis, in those studies reviewed, tended to lack reproducibility over time. Although many studies showed good specificity and sensitivity, their study design was debatable. Many of the studies used arthrography as a control diagnostic method; however, this in itself is questionable. Authors concluded that none of the methods have sensitivity and specificity levels that can demonstrate JVA as a diagnostic tool, but did state that it may provide good ancillary documentation.

I have taken many post-graduate courses in TMD, OSA, Bruxism and Snoring. Most of these lectures are unfortunately occlusally driven, with people naming splints after themselves. It's all about occlusal therapy. If you review the research on occlusal therapy in TMD and/or bruxism cases (occlusal splint vs MRA vs palatal splint as active control vs tensing) there is no difference in the arousal index. An improvement of the patient's airway will often result in an improvement of their TMD symptoms. Unfortunately for dentists, occlusion plays a minimal role in TMD and/or Bruxism.

There are other methods to assess and double check the freeway space. A dentist can use a combination of these methods to assess this important space. Average freeway space for a Class III patient is 1mm, a Class I patient 2-3mm and a Class II patient 4-5mm. Some schools open the bite too much e.g. a minimum of 4 mm inter-incisal space for all individuals. One issue I have with a TENS bite

"There are a lot of techniques to take a bite registration, but I find diagnosing the patient and offering a solution, based on the diagnosis, is the most important aspect of the case. This is in contrast to only using one technique and saying it always works..."

diagnostic techniques. This is a good review and includes a critique on studies with 62 references. These references are found from

is that those teaching the technique say you need a minimum of 4mm of inter-incisal vertical spacing. While some patients, (with

reduced facial verticals) may need this, it certainly isn't a requirement based on a "neurologically neutral position". If you like to create a lot of this vertical space so you can very quickly prep 20 crowns and rationalize the technique, that might be a lucrative restorative preference, but generally not an OSA or TMD treatment requirement.

I also question whether you fatigue the muscles. If you rhythmically contract any muscle for 45 minutes, you are unlikely NOT to be fatiguing the muscle. This is one reason TENS bites tend to have more vertical than any other bite. Also, the relaxation of the cervical, pharyngeal and hyoid muscles have more to do with airway than with anything else. You can't override the brain's (sympathetic control) response to mandibular repositioning, by claiming to open the airway via TENS.

Having made this point, please be aware that not all TENS units are the same. Most of those available and those used in physiotherapy are a high frequency TENS units. These act as pain "gate blockers". Due to the high frequency, the muscles could indeed fatigue as they have very little time for recovery between impulses. Most of the physical therapists and chiropractors, however, use High Frequency TENS machines. The dental companies selling this technology tend to recommend an Ultra Low Frequency TENS. The concept is to send a specific electrical signal to the 5th and 7th cranial nerves, thus contracting the muscles that are innervated by those respective nerves.

The TENS is specifically used for the purposes of relaxing (not fatiguing) muscles, but will probably benefit only those patients with no pathology to start with. Unfortunately, this is not the case for the majority of sleep or TMD patients. Modern TENS units deliver a bilateral multichannel synchronous, ultra low, frequency stimulus. They are neutrally mediated and electrodes are placed intentionally over the trigeminal, facial, accessory and C1/C2 nerves. These units deliver a stimulus every 1.5 seconds. This causes ALL the muscles innervated by these nerves to fully contract at the same time. The stimulus lasts for 0.2 seconds and for the remaining 1.3 seconds, the opposite of contraction occurs - i.e. relaxation or the giving up of tension. This allows the blood to once again flow freely through the muscle fibres. We must remember that this is normally true for normal/non pathologic muscles. Studies have shown that a contraction of as little as 10-25% of maximum can completely cut off the blood supply to the muscle. This is common in the TMD patient and in malocclusions that result in a retruded mandibular position, such as Class 2 div 2.

Over time (one hour/minimum 45 minutes), the healthy bio-chemistry of the muscles is once again established - lactic acid taken away, ATP, Calcium, and oxygen replenished. In other words, we can say it normalizes metabolism by normalizing blood

flow and this allows the muscles to relax to their resting length. This length is essential to reverse/prevent fatigue.²³

The giving up of tension/relaxation of the muscles facilitates the jaw to come downwards and forward (if that is the direction that achieves a neuromuscularly neutral posture). Forward movement is common, but not always resultant. Vertical change, however, always happens. This is a desired outcome for treatment in dental sleep medicine. A TENS induced Neuromuscular bite is often in the same direction as a sleep appliance, but usually with far less distance from centric occlusion. During the bite taking process, we do not allow the jaw to go back to the centric occlusion position due to the powerful memory (engram) associated with this position. The patient only references their front teeth (I personally think that this is a flaw in the technique, as you still elicit a neural response due to the proprioceptive input from this anterior tooth contact. This returns the patient towards their habitual bite.) In a perfect world, this bite registration would be driven by the muscles and neurology only. This is particularly important in Class 2 patients.

The multi-channel application of stimulus to all of the nerves (mentioned above), allows this relaxation to reach far beyond the muscles of mastication and facial expression. It is thought that the cervical, pharyngeal, supra and infrahyoid muscles are also relaxed. All of these factors act in favour of a relaxed and patent airway.

The traditional thinking of simply protruding the mandible takes an already fatigued system and potentially fatigues it further. This fatigue increases the sympathetic nervous system drive, which has been shown to be the root cause of the far reaching effects of sleep apnoea. Others feel that the apnoea is much more likely to be driving the sympathetic state, as opposed to the sympathetic state, being the root cause.

The neuromuscular dentistry approach is purported to work in harmony with the physiology of the patient - not against it. This concept is not really well demonstrated in the literature i.e. that TENSing creates a situation in which either the muscles, or the neural signals, mimic responses of non-inflamed and non-pathologic states. This is certainly what neuromuscular dentists hope for. Some of these clinicians feel that their machines can measure such changes and in their experience,

with phonetic bites and inflammation reducing techniques, but not through the use of TENS. TENSing can be a solution for taking a bite for some patients, but I would generally recommend its use only when there is a healthy jaw joint.

There are a lot of techniques to take a bite registration, but I find diagnosing the patient and offering a solution, based on the diagnosis, is the most important aspect of the case. This is in contrast to only using one technique and saying it always works.

The next article will continue this discussion and explain the phonetic bite and the Moses bite.

About the authors

Dr. Derek Mahony is a Sydney-based specialist orthodontist who has been actively involved in research that links constricted maxillary archforms to nasal breathing problems, adverse facial growth and systemic health problems such as nocturnal enuresis. He has presented over 400 lectures on orthodontic topics in more than 50 countries. As a practising clinician, Dr Mahony's research interests are in the aetiology of malocclusion and the guidance of facial growth. He references the Orthoapnea manual as the source of the information contained in this 6 part series of articles. Please contact info@derekmahony.com for further information or clinical questions.

Dr Edmund Lipskis graduated from Loyola University School of Dentistry, Chicago, USA in 1981. He joined the faculty and Department of Pediatric Dentistry at Loyola in 1982 where he became an Associate Professor. Dr Lipskis started his orthodontic training at Loyola, when the Orthodontic and Pedodontic Departments merged in 1983. Recognizing his interest in orthodontics, Dr Lipskis began a 30-year journey with over 2,000 hours dedicated to learning the broad spectrum of philosophies and techniques that orthodontics and facial orthopedics has to offer. Dr Lipskis' interests and continued education have expanded to include craniofacial orthopedics, treatment of chronic pain, TMD, and sleep disordered breathing. Dr Lipskis has been in private practice in St. Charles, Illinois for 29 years with focus on Orthodontics, TMD and Sleep Disorders.

If you're interested in learning more about the dentist's role in the diagnosis and management of snoring/sleep apnoea/TMD/bruxism, a one year mini residency program is starting in 2013. NB: Attending a one day introduction to sleep medicine course is essential before applying to register for the mini-residency.

For more info, email info@dentaeducation.net.au

If you're interested in learning more about the dentist's role in the diagnosis and management of snoring/sleep apnoea/TMD/bruxism, a one year mini residency program is starting in 2013. NB: Attending a one day introduction to sleep medicine course is essential before applying to register for the mini-residency. For more info, email info@dentaeducation.net.au or contact (02) 9700-9173.

References

References are available on request at editor@healtalkht.com

it is much more comfortable for the patient, which results in less need for titration, before the MMI. I feel that this is better demonstrated