Isolated Gingival Recession Coverage By Lateral Pedicle Graft With Tetracycline Root Conditioning And Platelet Rich Fibrin In Mandibular Anterior Tooth-A Case Report.

Dr. Anamika Sharma[1], Dr. Sachin Gupta[2]

Professor & Head[1], PG Student[2] Department of Periodontology[1,2], Subharti Dental College & Hospital, Meerut, U.P.[1,2]

Access Online

Abstract

Gingival recession is a very common muco-gingival defect which brings about esthetic discomfort, sensitivity, etc. Several techniques have been proposed to cover the denuded root looking for satisfactory outcomes both esthetically and functionally. In the present case report an isolated gingival recession is managed using lateral pedicle graft (LPG) technique in combination with tetracycline root biomodification along with Platelet rich fibrin.

Keywords: Gingival recession, lateral pedicle graft, Root biomodification, Tetracycline, Platelet rich fibrin

Introduction

Gingival recession is defined as the exposure of root surface by an apical shift in the position of gingiva.[1] It is a mucogingival defect of multifactorial origin. Gingival recession can be of two types, one due to periodontitis and the other primarily related to the mechanical factors, especially faulty brushing. However, there are certain other factors that can predispose to gingival recession including high frenum attachment, tooth malpositioning, bone dehiscence, thin marginal soft tissue, plaque induced inflammation and dental restorative, orthodontic, or periodontal treatments.[2] The consequences of gingival recession are poor aesthetics, plaque retention, gingival bleeding, root caries, root abrasion, hypersensitivity and tooth loss. In general, complete coverage of facial recession defects can be achieved if the biologic conditions for accomplishing root coverage are satisfied like no loss of interdental soft and hard tissues height and other anatomic variations.[3] Periodontal plastic surgical procedures proposed to treat gingival recession can be divided into three main groups: pedicle soft tissue grafts, free soft tissue grafts and regenerative techniques. Amongst the various pedicle and soft tissue grafts used for recession coverage after connective tissue (CT) graft with LPG has found to be most predictable for covering of isolated recession defect.[4] Root surface biomodification or use of GTR along with flap have proven to be shown enhanced collagen fibrils exposure that may facilitate adhesion of blood clot to root surface and favor migration of fibroblasts. Other additive materials like the PRF as a membrane, acellular dermal matrix or amniotic membranes etc. has proven their efficacy in recession coverage.[5]

This case report highlights the use of the laterally positioned pedicle flap technique in combination with PRF along with tetracycline hydrochloride as a root surface biomodification agent, in the management of localized gingival recession defect.

Case Report

A 35 years old healthy male patient reported to Outpatient department of Periodontology, Subharti Dental College and Hospital, Meerut, Uttar Pradesh with achief complaint of sensitivity in lower front tooth region and esthetic concern for past 9-10 months. Patient had a non- contributory medical history. Intraoral examination revealed anterior crowding with recession of 7mm depth in the lower left central incisor.(Fig 1)Radiographic examination showed mild interdental bone loss. (Fig2)

Informed consent was taken after explaining the procedure. Following pre-surgical rinse with chlorhexidine the area was anesthetized using local anesthesia. (2% lignocaine with 1:80000 adrenaline) The exposed root surface was thoroughly scaled and root planed. Convexity of the root surface was reduced by mechanical root biomodification. Root conditioning was performed with a cotton pellet soaked in a solution of 100mg/ml tetracycline for 3 minutes. (Fig 3)

At the recipient site 'V' shaped incision was made along the soft tissue margin with an internal bevel incision on the gingival margin adjacent to the donor site and an external bevel incision on the opposite margin to remove the epithelium and connective tissue. A horizontal incision 1-2 mm below the gingival margin followed by vertical incision in an oblique direction till mucogingival junction incorporating the frenal pull was made. Flap was raised using blunt dissection. To ensure that the flap was free enough to permit free movement to the recipient site a cut back releasing incision was made.

After the preparation of recipient and donor site, 5 ml of the venous blood was drawn from antecubital vein, collected in a sterile test tube without any anticoagulant, immediately centrifuged for 10 minutes at 3000 rpm. After centrifugation , PRF separated from RBC base and PRF membrane was prepared in a PRF box by placing the PRF clot in it for 5 minutes. PRF membrane was placed over the denuded root surface (Fig 4) and the flap was approximated 1 mm coronal to the cement-enamel junction and sutured by 5-0 silk sutures. (Fig 5) Periodontal dressing was placed to protect the surgical site.

Post- operative instructions were given to patient, and was asked not to brush at the surgical site for 2 weeks. Analgesics and antibiotics were prescribed for 5 days along with 0.2% chlorhexidine mouthwash twice daily for 3 weeks. Sutures were removed 2 weeks postoperatively. Healing was uneventful with complete coverage of root surface with excellent color matching seen after 3 months. (Fig6)

Figure 1: Miller class II recession 31

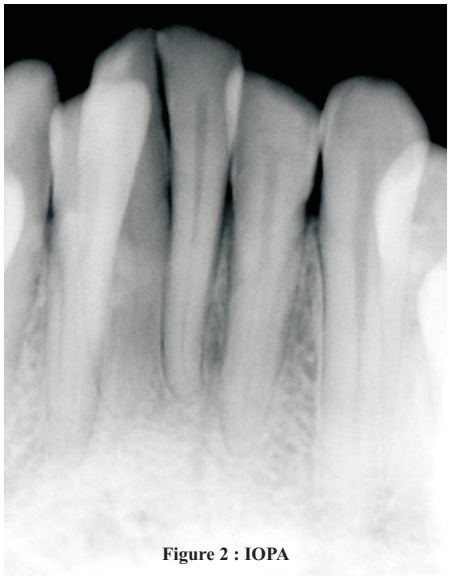

Figure 2 : IOPA

Figure 3: Root conditioning with Tetracycline-HCL

Figure 4: PRF placed at defect site

Figure 5: sutures placed

Figure 6: 3 months post operative

Discussion

In the present case, patient had a Millers class II recession in the tooth no 31 with the concern regarding unpleasant esthetics and hypersensitivity. Elimination and control of etiology, interproximal bone level and the choice of best suitable coverage procedure based on the clinical situation are the several factors on which success of root coverage procedure depends.[6] In the present case, Lateral pedicle graft technique was performed because of the good periodontal condition of the neighbouring tooth with adequate keratinized gingiva and normal bone height as data from literature[7-9] suggests that pedicle flap surgical techniques are recommended in the patients with esthetic demand where there is adequate keratinized tissue apical or lateral to recession defect.

Grupe and Warren[10] described lateral pedicle graft as a surgical procedure comprising the use of full thickness pedicle flap but it leads to exposure at the donor site. Staffileno[7] advocated the use of partial thickness pedicle flap, that prevented the exposure of donor site. The advantage of this technique is that single site is required with no additional surgical site and excellent color matching of the recipient site with the surrounding tissue as seen in this case.

Root surface biomodification agents can improve the outcome of recession coverage procedures.[11] These agents lead to removal of smear layer and bacterial endotoxins, widen the orifices of dentinal tubules and expose the dentinal collagen matrix. Successful periodontal wound healing can be achieved by this dentinal collagen matrix as itis thought to provide substrate that supports the chemotaxis, migration and attachment of fibroblasts.[12]

Platelet rich fibrin is a second generation platelet concentrate developed by Choukroun[13] in 2005. Placement of PRF membrane in recession defects can be used to restore the functional properties of the labial gingiva by repairing gingival defects and re-establishing the continuity and integrity of the zone of keratinized gingiva. Various growth factors released from PRF have been shown to accelerate soft and hard tissue healing. They promote fibroblast proliferation, angiogenesis, increase tissue vascularity, rate of collagen formation, mitosis of endothelial and mesenchymal cells. **Bouchard et al**[14] compared tetracycline –HCL and citric acid in the treatment of class I and class II gingival recessions and concluded that both agents have comparable clinical effects. **Jankovicet al**[15] conducted a RCT in which PRF membrane provided acceptable clinical results in gingival recession treatment.

Conclusion

Various root coverage techniques can be employed in successful root coverage. Lateral pedicle graft along with tetracycline HCL and PRF provides a biocompatible surface and improves the connective tissue attachment of the flap to the root surface which finally leads to the excellent outcome in the form of significant root coverage of the exposed root surface.

References

1. Carranza FA, Newman MG, Glickman I. Clinical Periodontology. 8th ed. Philadelphia: Saunders; 1996.
2. Hoag P. Isolated areas of gingival recession: Etiology and treatment. CDS Rev 1979;72:27-34.
3. Wennström JL. Mucogingival surgery. In: Lang NP, Karring T, editors. Proceedings of the 1st European Workshop on periodontology. Berlin: Quintessence Publishing Co.; 1994. p. 193-209.
4. Prato GP, Clauser C, Cortellini P. Periodontal plastic and mucogingival surgery. Periodontol 2000. 1995;9:90-105.
5. Oates TW, Robinson M, Gunsolley JC. Surgical therapies for the treatment of gingival recession. A systematic review. Ann Periodontol 2003;8:303-20.
6. Greenwell H, Bissada NF, Henderson RD, Dodge JR. The deceptive nature of root coverage results. J Periodontol 2000;71:1327-1337.
7. Staffileno H. Management of gingival recessions and root exposure problems associated with periodontal disease. Dent Clin North Am1964;3:111-120.
8. Valletta G, Matarasso S, Gagliardi G. Lateral sliding flaps in mucogingival surgery. Minerva Stomatol. 1978;27(4):231-44.
9. Caffesse RG, Kon S, Castelli WA, Nasjleti CE. Revascularization following the lateralsliding flap procedure. J Periodontol. 1984;55(6):352-8.
10. Grupe HE, Warren R. Repair of gingival defects by sliding flap operation. J Periodontol 1956;27:92-5.
11. Oliveira GH, Muncinelli EA. Efficacy of root surface biomodification in root coverage: a systematic review. Can Dent Assoc 2012;78:c122.
12. Polson AM, Frederick GT, Ladenheim S, Hanes PJ. The production of a root surface smear layer by instrumentation and its removal by citric acid. J Periodontol1984 ;55(8):443-446.
13. Choukroun J, Dohan DM, Simonpieri A, Schoeffler C, Dohan SL, Dohan AJ, et al. Platelet rich fibrin (PRF): A second generation platelet concentrate: Part V: Histologic effects of PRF effects on bone allograft maturation in sinus lift. Oral Surg Oral med Oral Patho Oral Radio Endod. 2006;101:E299–303.
14. Bouchard P, Nilveus R, Etienne D. clinical evaluation of tetracycline HCL conditioning in the treatment of gingival recessions. A comparative study. J Periodontol 1997;68:262-269.
15. Jankovic S, Aleksic Z, Klokkevold P, Lekovic V, Dimitrijevic B, Kenney EB, et al. Use of platelet-rich fibrin membrane following treatment of gingival recession: A randomized clinical trial. Int J Periodontics Restorative Dent 2012;32:e41-50.