Attachment Retained Maxillary Over-Denture

Dr. Sunil Dogra[1], Dr. Maya Dalaya[2], Dr.Mahesh Ghadage[3], Dr. Geeta Hatte[4], Dr. Sagarika[5]

P.G.Student[1],Professor[2],P.G.Student[3],P.G.Student[4] Department of Prosthodontics Bharati Vidya Peeth Dental College & Hospital, Navi Mumbai [1,2,3,4]
P.G.Student[5],Department of Oral & Maxillofacial Surgery V. S. Dental College & Hospital, Bangalore[5]

Access Online

Abstract

The over denture, a complete or partial denture prosthesis constructed over existing teeth or root structure, is not a new concept in a technical approach to a prosthodontic problem. Indeed, its use dates back over 100 years. It is simple and cost effective treatment than the implant supported over denture. The use of overdenture preserves the sensation of proprioception, preserves the edentulous ridge, maintains the border seal and provides the patient with good speaking ability, chewing efficiency. The retention and stability of the prosthesis can be enhanced greatly in bar supported overdenture. This case report depicts the step by step procedure for bar and clip retained maxillary overdenture that opposes conventional mandibular complete denture.The bar was fabricated from prefabricated castable bar and female clips were attached by direct technique.the mode of retention was primarily through frictional resistance.

Keywords: Hader Bar Retained Overdenture, Attachment, Direct Technique.

Introduction

Since miller's classic article[1] appeared in 1958, significant advances have been made in over denture treatment. Improved over denture procedures and materials have increased treatment effectiveness, furthering the application of over denture concepts.[2] Over-dentures have advantages and disadvantages. Prominent among advantages is the conservation of natural teeth, slowing of residual ridge atrophy.[3,4] Stability and support can be better than conventional complete denture, masticatory performance may be enhanced, perhaps as a result of abutment support and increased masticatory force potential. Disadvantages of overdenture treatment include the need for pre requisite treatment which requires additional time and increases cost.in patients with poor oral hygiene, maintenance of abutments and overdentures are also time consuming and financial consideration, though critical to treatment success. Overdentures may be considered for patients who have congenital or acquired defects as a result of catastrophic face and jaw injuries or disease. Overdentures are classified into three basic types, immediate overdentures, transitional overdentures, remote overdentures.[5] According to heartwell,[6] overdentures can be classified as coping , non coping, attachments, submerged vital roots: effective in preserving submerge vital roots.

Most of the attachments are secured to the abutment bya cast coping. Objective of attachment is to improve theretention of denture.[7] the use of attachments can direct occlusal forces away from weak supporting abutments and into soft tissue, or redirect occlusal forces toward stronger abutments and away from the soft tissues.They act as shock absorbers,stress redirectors as well as providing superior retention.Attachments used to retain overdenture prosthesis are physically classified as studs and bars. Bar attachment retainers have the dual role of acting as splints for root spanning the edentulous space and providing overdenture retention.

Overdenture attachments can also be functionally classified as rigid or resilient. Because the periodontal support has been lost, the resilient attachment is used more often for overdenture therapy. The resilient attachment spreads the functional load over both the retained root structure and the edentulous ridge.[8]

This case report depicts tooth supported over denture with castablehader bar metal superstructure attached to the maxillary denture with direct technique. The designincorporates use of plastic retention clips inside a metalsuperstructure. This gives the added advantage of plastic clip removal and replacement with new clip after wear or loosening of the existing clip.The Hader bar is a pear-shaped bar when viewed incrosssection. Thayer and Caputo[9] studied the various tissue bar attachments and concluded that the Hader bar produced less torquing force and distributed the forcesmore evenly between the posterior edentulous area and the contralateral abutments in comparison with the other tissue bar designs.

Case Report

A 61 year old female patient came to the department of Prosthodontics in Bharati Vidyapeeth Dental College Navi Mumbai with a chief complaint of missing teeth and difficulty in chewing food. Shehad a completely edentulous mandibular arch and partially edentulous maxillary arch with Kennedy's class II. Tooth no 11 13 21 23 were present. (Fig 1) Patient gave a history of loss of teeth due to caries and periodontal problems. She had already worn interim removable partial denture and was not satisfied with the fitting. Patient wanted prosthesis with good retention and stability compared to her previous prosthesis.

Because of poor bone support and carious involvement which was seen radiographically, it was decided to extract maxillary central incisors and retain both the canines which can be used as abutments for overdenture therapy. Oral prophylaxis was carried out for the remaining teeth and tentative jaw relation was made to assess the interocclusal space and was found to be adequate for hader bar attachment retained over denture.

The different treatment options available for this patient was

- Extraction of all remaining teeth followed by conventional maxillary complete denture.
- Extractions followed by implant supported overdenture.
- Tooth supported over denture.

All the treatment options were discussed with the patient, due to the financial condition of the patient it was decided to procede with hader bar attachment supported over denture therapy in maxillary arch and conventional complete denture in lower arch.

Clinical Procedure

Maxillary impression was made using alginate (Fig 2) and mandibular impression was taken using impression compound (Fig 3). Diagnostic casts were articulated at anticipated vertical dimension of occlusion. The tentative articulation helped in assessing the available interarch space, and this was found to be adequate for hader bar supported overdenture. Abutment teeth were prepared with a dome shaped contour hemispherically rounded in all dimensions. Abutment teeth height was 3-4 mm with finish line placed equigingivally. Border moulding of the maxillary arch was done with tracing sticks (DPI Pinnacle). Radicular canal preparation was done with reamers 4mm short of the apical length. (Fig 4). Indirect cast coping

impression was taken with the help of trimmed matchstick and medium body elastomeric impression material which was retrieved in border moulded custom tray. (Fig 5). Border moulding and final impression of lower arch has been done in a conventional manner. Both impressions were poured in type IV dental stone and casts were retrieved after complete set.(Fig 6). Petroleum jelly was applied within the prepared canal and impression was taken with the help of pattern resin (duralay inlay pattern resin) (Fig 7). An inlay wax pattern coping was fabricated on both the abutments 13, 23 and prefabricated bar of 2mm thickness and 3mm height was attached with the wax copings.(Fig 8) . Parallelism of the abutment coping was checked by the surveyerand whole assembly was invested, burnout and casted in cobalt chromium alloy.(heraneuskulzar) (Fig 9). The whole framework with stud attachments was finished and highly polished to avoid any plaque accumulation and was tried in patient's mouth, the fit was found to be satisfactory. The assembly was lutedonto the abutment teeth with resin cement (relyx u200,3m) (Fig 10).

After luting the assembly in patient mouth, a final impression of the upper arch was made using medium body elastomeric impression material in special tray. Care was taken to block the undercut below the bar with soft wax at the time of impression making. The remainder of the procedures till try in was done as conventional method for complete denture. After denture fabrication it was checked in patient mouth for occlusion and extentions (Fig 11). Medium retention silicon sleeves were used on metal super structure for added advantage of plastic removal and replacement with new clip after wear or loosening of the existing clip. Silicon sleeves were retrieved chairside with direct method using autopolymerising acrylic resin while space between the haderbar and tissue was blocked by wax for easy removal of the sleeves (Fig 12).

Discussion

Success of attachment retained over denture mainly depends on proper abutment selection, attachment selection, interarch space, clinical experience, patient motivation, precise laboratory work and maintenance by the patient. The decision first should be made to retain the teeth as overdenture and then attachment should be planned. In this case canines were used as an abutment as they are the most important proprioceptive organs, the shape, position, larger root length, larger periodontal attachment area makes them ideal abutments.[10] retained roots primarily help in retention and positional orientation of the prosthesis.[11]The earliest reference to the use of roots for providing support was by prothero[12] in 1916; he stated,"often times two or three widely separated roots or teeth can be utilized for supporting a denture"[13]

Miller[1] in his study concluded that alveolar bone resorption depends on three variables which are:

1. The character of the bone.
2. The health of the individual.
3. The amount of trauma to which the structures are subjected.

Over denture helps reduce shrinkage of surrounding bone and reduces pressure on the alveolar ridge.

Rissinet al. In 1978 compared masticatory performance inpatients with natural dentition, complete denture and overdenture. They found that the over-denture patients had a chewingefficiency one -third higher than the complete denture patients.[14]Overdenture with attachments can redirect occlusal forcesaway from weak supporting abutments and onto a soft tissueor redirect occlusal forces toward stronger abutments thereby resulting in superior retention.[15] It has been proved that reducing abutment 1.5 mm-2.0 mm above gingival margin reduces the crown root ratio thus reducing mobility by 40%.[16]As the bar is close to the alveolar bone, forces of mastication exert much less leverage to the teeth.The bar joint offers slight vertical and rotational movement of the denture as well as a stress breaker action. Bar exhibits more cross-arch involvement and allows occlusal forces to be shared between the abutments.[17]Since there was adequate inter arch space, so the thickness of the acrylic denture over the copings and bar assembly was not compromised. Customized Bar assembly calls for perfection both at the dentist and technician level, so it is challenging to execute, but the results are worth the effort.These days implant treatment has become the norm, thus toothsupported overdentures have taken a backseat as a result of competitive (belligerent) commercialization of implants.

A tooth supported over denture is very much at the forefront as the treatment modality incorporating preventive prosthodontics concepts to the core. Let's not forget our basics rather reinvigorate them and make them a regular part of our clinical practice.

Conclusion

Although advances in methods and improved materials have contributed to better treatment results, caries and periodontal problems still remain significant threats to over denture life. The prevention of caries and recurrent periodontal disease thus becomes a most important aspect of post insertion care.

Undoubtedly, there are a number of successful overdenture methods. Common to most over denture technique is that an overdenture may be the only treatment that permits retention using the patient's last few retainable teeth. A conservative approach to root preservation still is a valid and practical measure in preventive dentistry.

Reference

References are available on request at editor@healtalkht.com



Fig. 3 Fig. 4

Fig. 5 Fig. 6

Fig. 7 Fig. 8

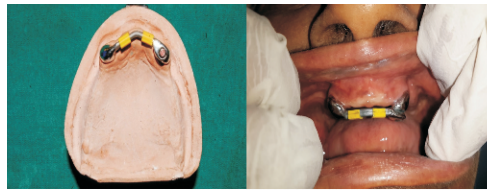

Fig. 9 Fig. 10

Fig. 11 Fig. 12

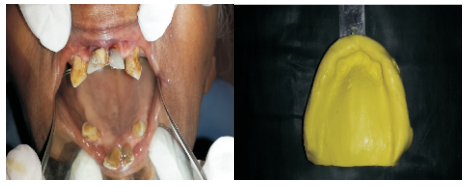

Fig. 1 Fig. 2