Prosthetic Approach of Badly Mutilated Endodontically Treated Tooth:A Case Report

Dr. Rajnikanth A.V.[1], Dr. Aamina Nisar[2], Dr. Achyut Sinha[3]

Professor[1], P.G. Students[2, 3] Department of Prosthodontics and Crown & Bridge, Rama Dental College, Kanpur (U.P.) India.[1,2,3]

Access Online

Abstract

The prosthetic treatment of seriously damaged, endodontically treated teeth often require an endodontic post as an additional retentive element for core build-up prior to placement of the crown. For post and core placement there should be atleast 2mm of sound tooth structure to provide ferrule effect. Periodontal crown lengthening or orthodontic tooth eruption is carried out if the sound tooth structure is not sufficient for ferrule design. These posts can be custom made or pre-fabricated. Pre-fabricated composite post systems are replacing metal post systems because of their superior properties like increased retention, no corrosion, and good esthetics.

This case report demonstrates the restoration of badly mutilated endodontically treated tooth by fiber reinforced post after periodontal crown lengthening.

Key Words: post & core, fiber-reinforced post, ferrule effect, crown lengthening.

Case Report

A 40 year old male patient reported to the department of prosthodontics with the chief complaint of broken upper right front tooth.

Intra-oral and radiographic examination: revealed badly broken, discolored, root canal treated 11 with good apical seal (Fig 1).

Fig 1(a): Pre-operative

Fig 1(b): RCT treated 11

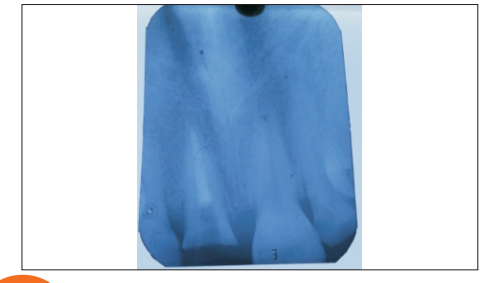

There was insufficient tooth structure present circumferentially so, it was decided to do crown lengthening followed by placement of fiber reinforced post and composite core build up with final PFM crown.

Crown lengthening: 2mm of gingiva was cut circumferentially with the help of BP blade (no. 12) to provide ferrule effect (fig 2).

Fig 2: Crown lengthening

Steps in Post and Core:

1. Removal of gutta-percha
2. Enlargement of canal and placement of post
3. Core build-up

The length of the canal was measured in IOPA and gutta-percha was removed with the help of gates glidden leaving 3-5mm of it apically. Fiber reinforced post was selected and canal was enlarged with the corresponding drill. The length of the post was marked with stopper and placed inside the canal (Fig 3).

The post should snuggly fit in the canal. Once the length and fit of post was confirmed it was cemented with GIC (Fig 4).

Fig 3: Placement of fibre post

Fig 4: Cementation of the post

Core build up: the excess post was cut and over it core was build with composite resin (B-2). Core was then finished and proper finish line was placed on the natural tooth structure (Fig 5). Retraction cord was placed around the tooth (fig

6) and impression was made with PVS (fig 7).

Cast was poured and PFM crown was fabricated over it. Fit of the crown was checked and it was finally cemented with GIC (Fig 8).

Fig 5(a): Core-build up with composite

Fig 5(b): Palatal view

Fig 6: Placement of retraction cord

Fig 7: Impression with PVS

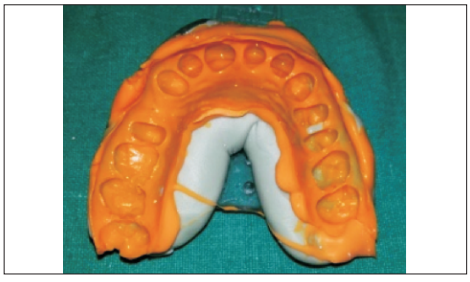

Fig 8: PFM crown

Discussion

The successful treatment of a badly mutilated tooth with pulpal involvement depends not only on good endodontic treatment, but also on good prosthetic restoration.[1]

With time endodontically treated teeth dry out and the dentin undergoes changes in collagen cross-linking because of which these teeth become more brittle and may fracture more easily than non-endodontic treated teeth.[2] The amount of sound tooth structure present to support the final restoration determines whether a post is needed or not.

Retention of the core to support the coronal restoration is the basic function of the post so it should only be used when there the coronal sound tooth structure is not sufficient to support the restoration.[1] The completed preparation should possess a collar or ferrule effect which provides anti-rotational feature for the stability of the crown and also aids in fracture resistance and retention of the crown.[3]

There should be at-least 1.5-2mm of sound tooth structure to provide ferrule effect.[4] Periodontal crown lengthening or orthodontic tooth eruption should be carried out if there is insufficient sound tooth structure for ferrule design.

The concept of using root for retaining the crown is not new. Fauchard in 1700s used wooden dowel in canal to aid in retention of the crown. The wood expanded with time in the moist environment and enhanced the retention of the dowel.

Posts available now are either custom made or pre fabricated. Custom made posts are used in flared canals, elliptical cross-section canal and in multiple canal teeth and these can be cast from a direct pattern or indirectly in the laboratory. Gold alloys, pt-pd, base metal, Co-Cr-Mo and Ni- Cr alloys are used for casting these posts.[5]

Prefabricated posts are used in straight canals with circular cross-section. Prefabricated posts may be made up of stainless steel, titanium alloys, gold plated, brass, ceramic & fiber reinforced polymer. Fiber reinforced posts are made of carbon or silica fibers surrounded by a matrix of polymer resin (epoxy resin). These fibers are available as braided, woven and longitudinal with the diameter of 7-10 micrometers.[1] Fiber-reinforced posts are replacing metal posts because of their superior properties like no corrosion, no metal allergy, improved retention, strengthens tooth-restorative interface after bonding, good esthetics, modulus of elasticity similar to dentine, easy to remove in case of endodontic failure.[6]

Based on mode of retention posts may be sub-grouped as active or passive. Active posts use threads to derive the retention directly from the root dentine whereas, passive post derive their retention from luting cement by passively seating in close proximity to the post space walls. According to the shape each post type can further be sub divided as tapered or parallel sided.

In general active posts are more retentive than passive posts and parallel sided posts are more retentive than tapered posts.[7]

Factors that influence the post selection

Amount of sound coronal tooth structure present, anatomy of the tooth, tooth position, length and width of root, configuration of canal, function of the tooth, torquing force and stresses, hydrostatic pressure development, design & material of the post, capability of bonding, retrievability, material of the crown and esthetics.[8]

The length of the post must be 2/3 the length of the root or atleast equal to the length of the crown.

Increase in length increases the retention but 3-5mm of the apical seal must be maintained.

Post diameter should not exceed 1/3 diameter of the root. Minimum of 1mm of sound dentine should be maintained circumferentially.

Materials for cementation of the post

Zinc phosphate, poly carboxylate, glass ionomer, resin-modified glass ionomers and composite resins. Core build up is must when there is insufficient sound tooth structure as it aids in the retention and resistance provided by the residual tooth structure.

Materials for core-build up

The most commonly used core materials are cast gold, amalgam, resin-based composite and glass ionomer cement.

Conclusion

The successful treatment of badly mutilated tooth demands good endodontic as well as good prosthodontics treatment. Endodontically treated teeth are more brittle than non-endodontic treated teeth. When there is insufficient tooth structure present the retention of the crown is hampered, so, in these situations a post is used which provides additional retention to the crown. There should be at-least 1.5- 2mm of sound tooth structure to provide ferrule effect. Periodontal crown lengthening or orthodontic tooth eruption should be carried out if there is insufficient sound tooth structure for ferrule design.

Post diameter should not exceed 1/3 diameter of the root. Minimum of 1mm of sound dentine should be maintained circumferentially. Post must be 2/3 the length of the root or atleast equal to the length of the crown. Increase in length increases the retention but 3-5mm of the apical seal must be maintained.

Posts may be custom made or pre-fabricated. Pre-fabricated fiber reinforced post systems are replacing metal post systems because of their superior properties.

Various factors influence the post selection like the amount of coronal structure present, length & width of the root, torquing forces, post design, post material and esthetics.

References

1. Cheung W. A review of the management of endodontically treated teeth (post, core & the final restoration). JADA 2005; 136:611-19.
2. Rivera EM, Yamauchi M. Site comparisons of dentine collagen cross-links from extracted human teeth. Arch Oral Biol 1993;38:541-6.
3. Terry DA, Leinfelder KF, Geller W. Aesthetic & Restorative Dentistry: Material Selection & Technique. Stillwater, Minn: Everest Publishing Media; 2009.
4. Juloski J, Radovic I, Goracci C, Vulicevic ZR, Ferrari M. Ferrule effect: A literature review. JOE 2012;38(1):11-9.
5. Luthra RP, Gupta R, Sirohi R, Kumar N, Mehta S. Management of mutilated teeth with Post and Core: A Review. J Adv Med Dent Sci Res 2015;3(4):99-101.
6. Cormier CJ, Burns DR, Moon P. In vitro comparison of fracture resistance and failure mode of fiber, ceramic and conventional post systems at various stages of restoration. J Prosthodont 2001;10:26-36.
7. Smith CT, Schuman N. Prefabricated post-and-core systems: an overview. Compend Contin Educ Dent. 1998;19:1013-1020.
8. Fernandes SA, Shetty S, Coutinhon I. Factors determining post selection: a literature review. J Prosthet Dent 2003;90:556-62.