


Asian Pacific Journal of Tropical Disease

journal homepage: <http://www.apjtc.com>



Letter to editor

<https://doi.org/10.12980/apjtd.7.2017D6-418>

©2017 by the Asian Pacific Journal of Tropical Disease. All rights reserved.

A relapse case of HIV-PKDL co-infection associated with diabetes and its microvascular complications

Rakesh Kumar¹, Vidyanand Rabidas¹, Biplab Pal², Roshan Kamal Topno³, Kanhaiya Agarwal¹, Rajendra Babu², Chandra Shekhar Lal⁴, Neena Verma⁵, Pradeep Das⁶, Krishna Pandey^{1*}

¹Department of Clinical Medicine, Rajendra Memorial Research Institute of Medical Sciences (Indian Council of Medical Research), Agamkuan, Patna, Bihar, India

²Department of Pharmacy Practice, National Institute of Pharmaceutical Education and Research, Hajipur, Bihar, India

³Department of Epidemiology, Rajendra Memorial Research Institute of Medical Sciences (Indian Council of Medical Research), Agamkuan, Patna, Bihar, India

⁴Department of Biochemistry, Rajendra Memorial Research Institute of Medical Sciences (Indian Council of Medical Research), Agamkuan, Patna, Bihar, India

⁵Department of Pathology, Rajendra Memorial Research Institute of Medical Sciences (Indian Council of Medical Research), Agamkuan, Patna, Bihar, India

⁶Department of Molecular Biology, Rajendra Memorial Research Institute of Medical Sciences (Indian Council of Medical Research), Agamkuan, Patna, Bihar, India

Dear editor,

A 38-year old male patient, a relapse case of post kala-azar dermal leishmaniasis (PKDL) with HIV presented with type 2 diabetes and its micro-vascular complications including non-proliferative diabetic retinopathy and diabetic neuropathy. In 2008, patient was diagnosed with visceral leishmaniasis and assessed by positive splenic aspiration for *Leishmania donovani* bodies. He was treated with single dose injection of liposomal amphotericin B (AmBisome) at 10 mg/kg *i.v.* at Rajendra Memorial Research Institute hospital, Patna, Bihar, according to the guidelines recommended by World Health Organization/National Vector Borne Disease Control Program. In 2010, he was diagnosed to have HIV with diabetes. He was started on antiretroviral treatment by an antiretroviral treatment center with tenofovir + lamivudine + efavirenz. He had relapses of kala-azar four times during the period of 2011–2015. He was treated with AmBisome plus miltefosine in 2011, single dose of AmBisome in 2012 and with AmBisome plus miltefosine another two times in the year 2015 at primary health center.

Patient developed nodular skin lesions on face, chest, back, hand and leg six months back. Skin biopsy was suggestive of PKDL and he was treated with AmBisome 5 mg/kg body weight twice a week for 3 weeks. Patient improved clinically and parasitologically (0 parasite in the slit skin smear) at the end of treatment. After 6 months of PKDL treatment, the patient was readmitted at Rajendra Memorial Research Institute hospital with complaints of papulo-nodular skin lesions for two months, tingling and numbness of hand and foot, along with joint pain for same duration. Skin biopsy was again suggestive of PKDL. Sputum for acid fast bacilli and serology for hepatitis B and C was negative. CD4 count was 152 cells/mm³, CD8 count was 442 cells/mm³, CD4/CD8 ratio was 0.34 (0.57–2.03). Apart from serum creatinine and blood glucose, all the hematological and biochemical parameters were found within the normal range. His serum creatinine was 2.5 mg/dL, urea was 34 mg/dL, fasting blood sugar was 180 mg/dL, post prandial blood sugar was 280 mg/dL, glycosylated hemoglobin was 8.4% and there was microalbuminuria in urine examination. After strict blood sugar control with regular insulin subcutaneously and on

*Corresponding author: Dr. Krishna Pandey, Scientist F, Department of Clinical Medicine, Rajendra Memorial Research Institute of Medical Sciences (Indian Council of Medical Research), Agamkuan, Patna, Bihar, India.

Tels: 919955313284 (R Kumar); 0612-2245744 (K Pandey)

E-mails: drakeshkmr@gmail.com (R Kumar); drkrishnapandey@yahoo.com (K Pandey)

The journal implements double-blind peer review practiced by specially invited international editorial board members.

Article history:

Received 15 Nov 2016

Received in revised form 7 Dec 2016

Accepted 28 Dec 2016

Available online 19 Jan 2017

diabetic and renal diet with proper hydration, renal parameters became normal. Fundus examination was suggestive of mild non-proliferative diabetic retinopathy in right eye and early non-proliferative changes in left eye. Diabetic neuropathy was diagnosed with clinical features of tingling, numbness, joint pain, resting tachycardia, anhydrosis and slowing of nerve conduction velocity. These neurological symptoms subsided after strict blood sugar control. Patient was treated with miltefosine 50 mg twice per day for 12 weeks, according to World Health Organization/ National Vector Borne Disease Control Program guidelines for PKDL. At the end of treatment, patient improved clinically, hematologically and parasitologically (Figure 1). Slit skin smear

revealed absence of parasites.

Visceral leishmaniasis in HIV is increasingly reported, but PKDL is rare in HIV and only few cases are reported in India[1]. Parasitic load is high in immunocompromised individual and present in severe form, hence nodular skin lesions are more common as compared to immunocompetent where it is mainly of maculo-papular type[2,3]. Diabetes is known to harbor infectious diseases, so its presence increases the fatality of the disease. Here we are reporting a relapse case of PKDL in HIV associated with diabetes and its complications. Our case is unique, because of unusual presentation and recurrence of PKDL in HIV and diabetes. There are no specific treatment

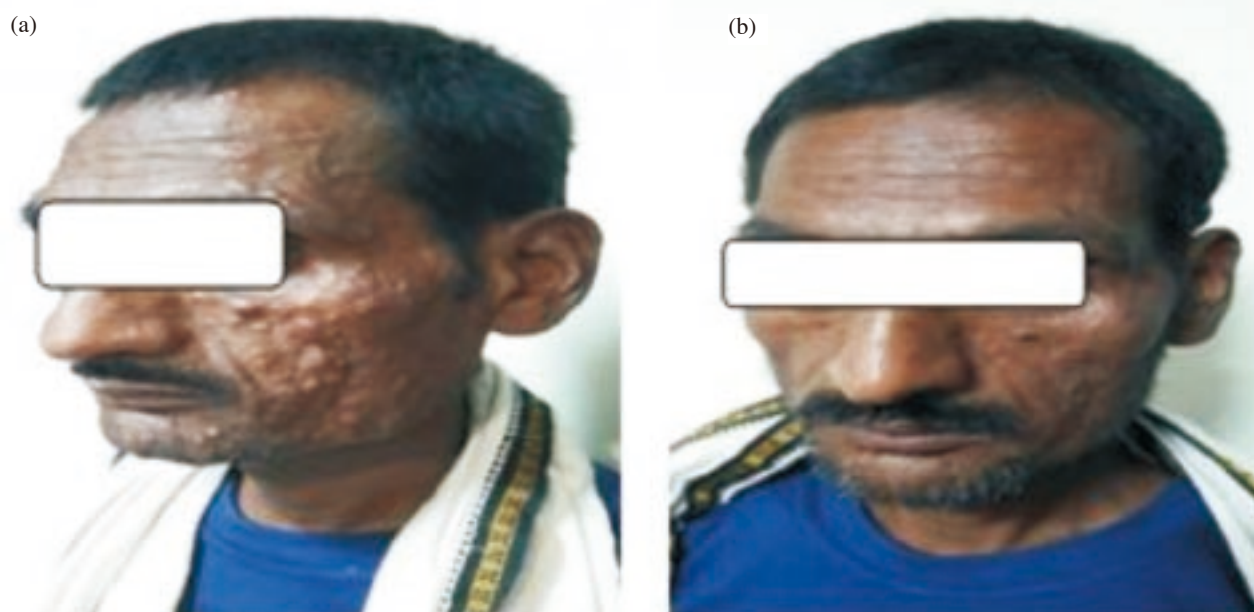

Figure 1. Patient with nodular lesions before treatment (a) and after treatment (b).

guidelines for this co-infection, especially in such complicated cases. Treatment of PKDL in HIV is miltefosine 50 mg twice a day for 12 weeks. The other treatment option for PKDL is amphotericin-b in the dose of 1 mg/kg in 5% dextrose *i.v.*, on alternate days for 20 injections in 3 to 4 courses at fifteen day intervals. This treatment regimen is very lengthy, requires prolonged hospitalization and has severe side effects. Combination studies are needed so that the treatment duration is shortened with high efficacy and safety. Treatment and diagnostic aspects of these disease combinations are quite difficult. These cases are more prone to frequent relapses, drug interactions and no proper dose authentication. Hence, more attention is needed for these plethoras of diseases when we are knocking at the door of kala-azar elimination in the Indian sub-continent.

Conflict of interest statement

We declare that we have no conflict of interest.

References

- [1] Shah S, Shah S, Prajapati S, Bilimoria F. Post-kala-azar dermal leishmaniasis in HIV-positive patients: a study of two cases. *Indian J Sex Transm Dis* 2010; **31**(1): 42-4.
- [2] Desjeux P, Ghosh RS, Dhalalaria P, Strub-Wourgaft N, Zijlstra EE. Report of the post kala-azar dermal leishmaniasis (PKDL) consortium meeting, New Delhi, India, 27–29 June 2012. *Parasit Vectors* 2013; **6**: 196.
- [3] Zijlstra EE. PKDL and other dermal lesion in HIV co-infected patients with leishmaniasis: review of clinical presentation in relation to immune responses. *PLoS Negl Trop Dis* 2014; **8**(11): e3258.