

MICRO-ENDOSCOPIC DISCECTOMY, A MODERN APPROACH FOR LUMBAR DISC PATHOLOGY

Mohamed El Hussein* & Taghrid Chaaban@

*MD, PhD, Neurosurgeon, Hôpital Libano Français, Zahle, Lebanon. @MS Nursing, IUL, Beirut, Lebanon.

Abstract

In the last decade, the neuro-endoscope has been used increasingly in the surgical management of spinal diseases, both intradural and extradural. Endoscopic discectomy is increasingly performed in lumbar region. This study included 200 patients with lumbar disc pathology operated upon with both techniques: Classic and Endospine Karl Storz system technique introduced by Destandau. Based on results (Macnab modified criteria), microendoscopic discectomy should be used in properly selected patients.

Key words: endoscopic, lumbar disc hernia, Endospine, Destandau technique

Introduction

Lumbar disc hernia became a serious public health problem due to its epidemiological, clinical and socio-economic impact characteristics. In United States it represents the fifth cause of medical service¹. Because of its increased prevalence among the active population, lumbar disc hernia has an increased economic impact.

Developing of surgical techniques to reduce the costs generated by this disease represents an important aim. In 1991, Foley and Caspart introduced in U.S. the first tubular system for the interlaminar approach of lumbar disc hernia; in 1997, Foley and Smith reported the first micro-endoscopic discectomy. In 1993, Destandau developed in France the Endospine system and reported the first endoscopic ablation of a lumbar disc hernia². Endoscopic lumbar discectomy has gained increasing popularity among the spine surgeons for the treatment of herniated intervertebral disc largely because it has the ability to overcome the limitation of muscles splitting³. The use of an endoscope allows the same access port and the same surgical technique to be used on the vertebral canal and disc while

at the same time reducing the skin incision and minimizing the access port. The advantages of this technique are the same as those for discectomy but the immediate postoperative effects are reduced allowing a more rapid rehabilitation and return to previous activities for the patient. Other advantages are a small skin incision with a gentle and minimal tissue dissection and excellent visualization^{4,5}.

Patients and Methods

This study included 200 of patients with lumbar disc hernia operated upon between 2012-2016. One hundred patients had classic open discectomy, and 100 were operated upon by endoscopically endospine method. All patients were re-evaluated at 6 months postoperatively based on Macnab modified criteria and MRI.

Clinically, the patients were re-evaluated at 7 days, 4 weeks and 6 months postoperatively, and for a better appreciation of the results we quantified the persistence of symptoms at 6 months after surgery. We included in this study some factors for better analysis of

morbidity of lumbar disc hernia, such as: age, gender, home environment, profession, obesity, duration of surgery, quantity of blood lost intraoperatively and postoperatively, complications of each technique, duration of hospitalization, and period of recovery.

The Endospine Karl Storz system consists of an operating tube which is positioned on the vertebral lamina after the incision of the skin, aponeurosis and detaching the muscles from the spinous process. This tube contains four channels for telescope (4 mm), suction tube (4 mm), surgical instrument (8 mm) and

nerve root retractor. There is an angle of 12 degrees between the working channel and the channel used by the telescope which enables the neurosurgeon to see the tips of the instruments and to use a suction tube as a second instrument. The nerve root retractor allows the nerve to be medialized thus removing it from the operating region. The Hopkins telescope with an angle of 0 degrees, offers a wide field of vision of the operating area. The fiberoptic light cable with a cold light source is integrated in the telescope (fig.1). The entire procedure is performed under constant video-endoscopic control.



Fig. 1 (a): outer tube and inner tube. (b) inner tube with various parts. Hopkins telescope, working channel and suction channel Endoscopic Spine Surgery-Destandau's Technique' by Rohidass and Destandau.

Under general anesthesia with endotracheal intubation, patients were placed in a modified knee-chest position. The involved disc was localized with the

help of special localization device, and the direction of approach was determined under fluoroscopic control. The place of incision was marked on the skin (fig.2).

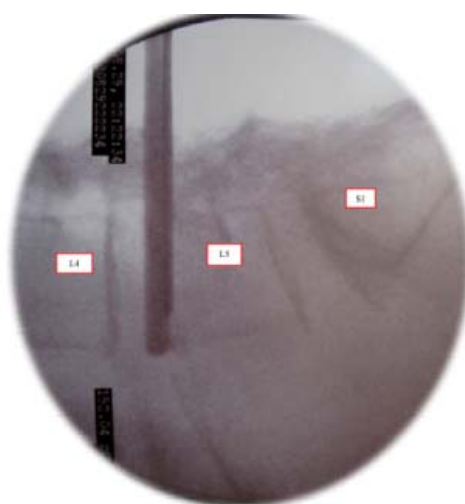


Figure 2: Marking the entry point (fluoroscopic image)

The skin incision was made 5 mm from the midline at the lateral edge of the spinous process. Hemostasis was carried

out by bipolar coagulation. The aponeurosis was incised with scissor at the level of the spinous process from the

affected levels S1 L5 L4. The para-vertebral muscles were spread out and muscles vessels were coagulated with bipolar forceps.

The superior position of Endospine system allowed resection of the lamina and of the yellow ligament and the inferior position allowed zoom effect and facilitated the dissection of the channel (fig.3, 6).

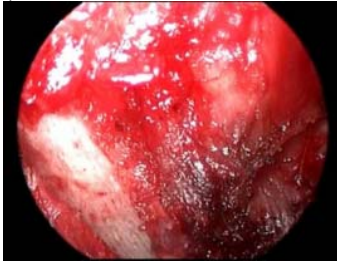

Fig.3: Intraoperative image of the interlaminar space with the superjacent vertebral lamina

Under permanent visual control, a fenestration was made using a Kerrison bone punch (2 and 3 mm) to detach the yellow ligament and expose dura mater (fig.4&5). A cotton swab was slid between lamina and dura mater. Also, a part of the articular process was resected to realize an adequate lateral exposure. Bone hemostasis was done with wax.

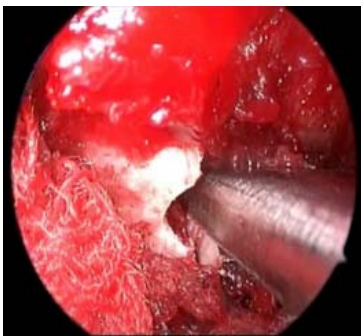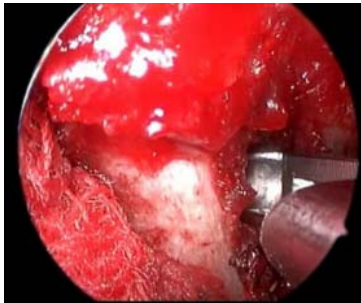


Fig.4&5: Intraoperative, the bone fenestration

The resection of yellow ligament allowed exposure of the affected nerve root.

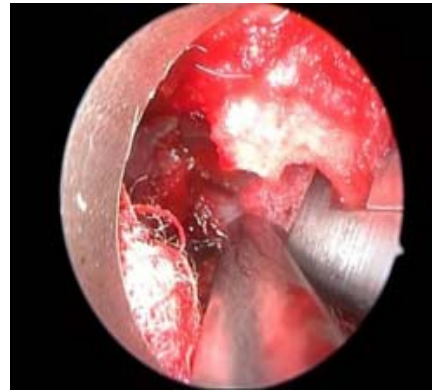

Fig.6: Resection of yellow ligament

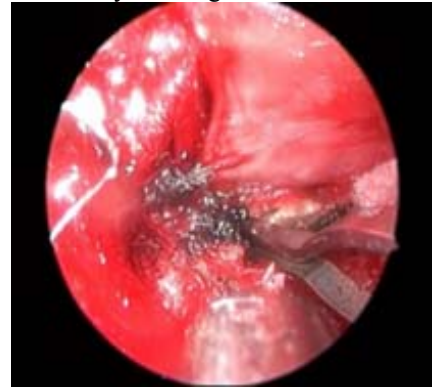

Fig.7: Control of hemostasis periradicular with oblique forceps

The nerve root was retracted medially with a special endoscopic retractor thus exposing the hernia and intervertebral space. A cotton swab was placed to allow medial retraction of the nerve root and removal of the nerve root retractor in order to regain mobility (fig.8).

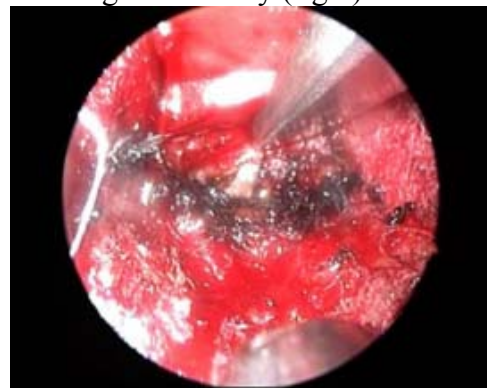


Fig.8: Retraction of the nerve root

An incision of the posterior longitudinal ligament was made and a partial nucleotomy was done (fig.9&10).

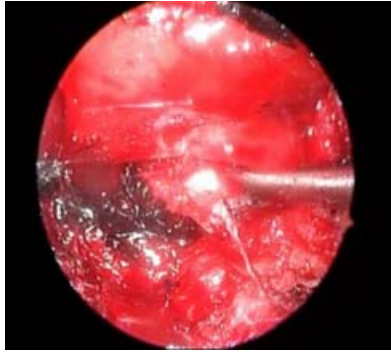


Fig.9: Removal of adherences between disc hernia and nerve root

After exploration of intervertebral space and foramen for any fragments, hemostasis of the muscle vessels was

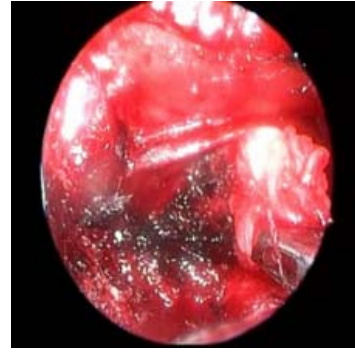


Fig.10: Resection of disc hernia

completed. The Endospine operating tube was removed and the ligament and the skin were sutured.

Results & Discussion

This study revealed that maximal incidence was noticed among the active adult population. Eighty percent of endoscopic microdiscectomies and 56% of open discectomies were made in patients aged 30-59 years. Disc hernia was rare in patients of age group 20-29 (5 cases classic discectomies and 3 cases micro-endoscopic discectomies) and, exceptionally, one case microendoscopic discectomy under 20 years, which is consistent with literature (fig.11).

The increased incidence among 60-69 age group of the patients operated by classic (34% versus 7%) can be explained by associated degenerative pathology (stenosis). The slightly increased incidence of microendoscopic discectomy in patients over 70 years (9% versus 5%) is also consistent with data. This minimal invasive technique due to reduced resection of the tissues allows a quicker mobilization (<24 hours) and healing of these patients.

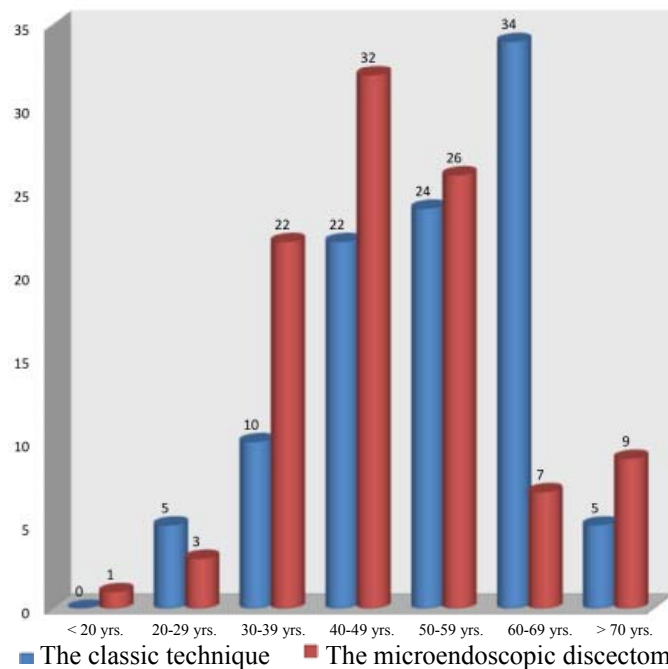


Fig.11: The distribution by age groups

Regarding gender distribution in this study, the incidence was higher among male patients compared to females in both series (fig.12). In classic technique, the ratio was 2:1 for male, while in microendoscopic discectomy, the ratio was 55%/45%, corresponding to those from literature.

There is a male prevalence in lumbar disc hernia operated upon varying from 1.3:1 to 2:1⁶⁻⁹. Kelsey and Ostfeld bring arguments that there is no “real difference” regarding gender, but male patients are more frequent operated upon due to the type of effort at job and because they cannot wait for favorable evolution with conservatory drug treatment¹⁰. Other sustain that male patients are more susceptible to disc hernia due to increased disc stress and deficit nutrition of the disc, because male patients have longer paths of diffusion-nutrition^{11,12}.

The difference may be explained by the height difference which is in absolute value 10.5 cm, female body being 7% less tall than male body, fact which has consequences at the posterior longitudinal ligament, especially in his lateral part. The height decreases every day by 10-30 mm because of pressure given by the weight on the intervertebral discs. The height is greater in the morning, after the

night rest compared to the evening, after the daily activity.

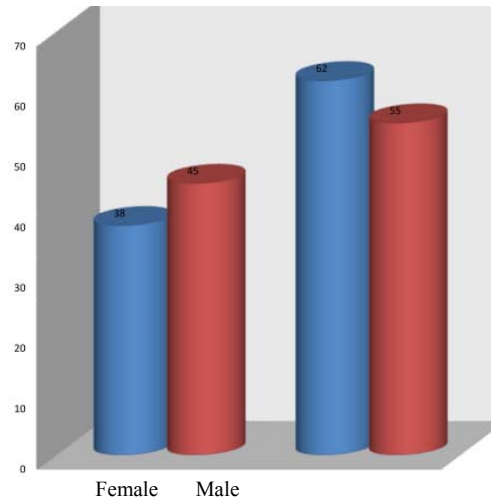


Fig.12: The distribution by gender

Regarding home environment, the prevalence was higher in patients from cities and they had more micro-endoscopic discectomies (71% compared to 55%).

This study marked an increased percentage of microendoscopic discectomies in educated patients compared with workers due to two aspects: grade of information and education and the intensity of physical work which accelerates the degenerative modifications, plus other pathologies (stenosis, lumbar spondylosis) as demonstrated in table I.

Table 1: The distribution by profession

Profession	The classic technique (number/percentage)	The microendoscopic discectomy (number/percentage)
Workers	63 (63%)	44 (44%)
Educated	37 (37%)	56 (56%)

Another aspect we took in consideration was the classification of the patients by BMI (tables II & III).

Table II: The classification of patients by BMI

BMI	Patient
<18.5	Under weight
18.5-24.9	Normal weight
25-29.9	Over weight
30-34.9	Obese grade I
35-39.9	Obese grade II
>40	Obese grade III

Table III: The incidence of obesity by BMI

No. of cases	BMI <18,5	BMI 18,5-24,9	BMI 25-29,9	BMI 30-34,9	BMI 35-39,9	BMI >40
CD	0	28	32	29	11	0
MD	1	30	28	27	13	1

CD: classic discectomy. MD: microendoscopic discectomy. BMI: body mass index

Obesity increases the risk of lumbar disc hernia by several mechanisms: excessive biomechanical load, increased total lipids and atherosclerosis which diminishes the transport of nutrients to disc thus favoring degeneration and by secondary inflammation caused by secretion of adipocytes (adipocytokines: adiponectin, leptin and resistin).

In scientific data, the risk of recurrence of operated lumbar disc hernia is 12 times greater in obese patients with BMI ≥ 30¹³.

In this study, like in other similar studies, the location of lumbar disc hernia is represented by L5-S1 and L4-L5: the classic technique 95% → 46% L4-L5 and 49% L5-S1; the microendoscopic discectomy 92% → 41% L4-L5 and 51% L5-S1.

In series with microendoscopic discectomy, the rest of locations were: 8% (1% L1-L2, 2% L2-L3, and 5% L3-L4), while in classic discectomy 5% (2% L2-L3, 3% L3-L4). The increased percent in microendoscopic discectomy is explained by the fact that patients were from urban medium and the traumatic factor was present in all cases.

Regarding the most affected part, we registered an increased incidence in the left side (52% classic, and 62% microendoscopic), data corresponding with literature and explained by the fact that right handed flip the lumbar column toward right and thus load in lumbar segment, in left.

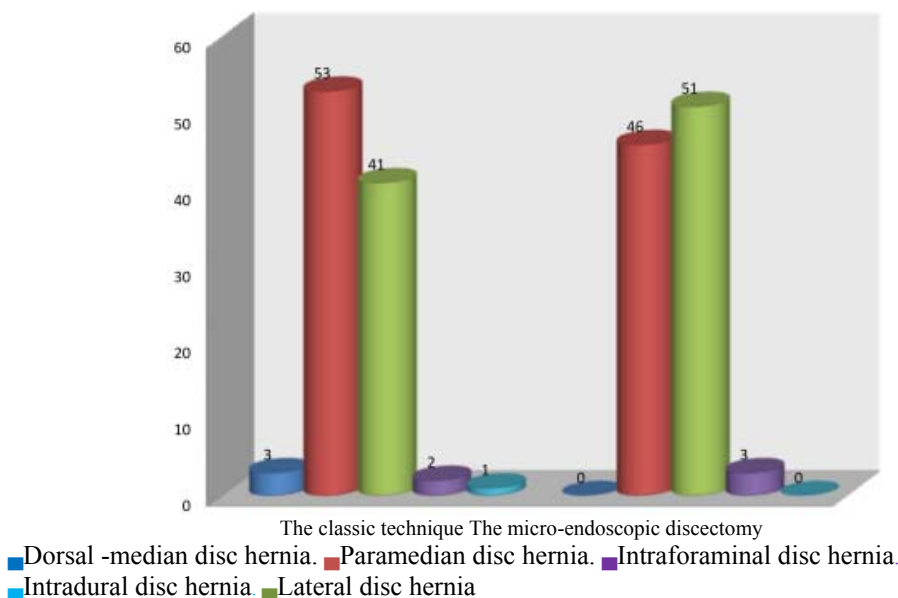


Fig.13: Classification of the disc hernia by anatomy-topography

In this study, we had 3 patients with dorsal median disc hernia operated upon with classic, because they required a large decompression of the nerve elements, difficult to realize by endoscopy (fig.13). The paramedian disc hernia requires

regarding its size unilateral or bilateral decompression, the classic approach allowing a larger opening. The lateral disc hernia compresses unilateral nerve root and election method was microendoscopic discectomy (51% versus

41%). The intra-foramina disc hernia compresses the nerve in foramen and microendoscopic discectomy is preferred for a reduced bone resection thus preventing destabilizing spinal cord. The intradural/intraradicular disc hernia has an incidence 0%-1%, like data mentioned in literature 0, 04%-1,1%^{14,15}.

Although the duration of approach is greater for endoscopic technique (90 min) compared to classic (60 min), loss of blood is less in endoscopic 50 mL (30-70 mL) than in classic (160 mL) and there were fewer complications (2%), as it is mentioned in literature.

Regarding the postoperative symptoms, the classic technique was criticized¹⁶⁻²¹.

The postoperative evolution based on modified Macnab criteria (excellent evolution: no pain, no restriction of movement; good evolution: intermittent lumbar pain, patient returned to job of low intensity; satisfactory evolution: neurologic deficit but improved, patient need retirement; unfavorable evolution: persistence of neurologic deficit, patient needs new intervention or classic) recommend the Endospine method (fig.14).

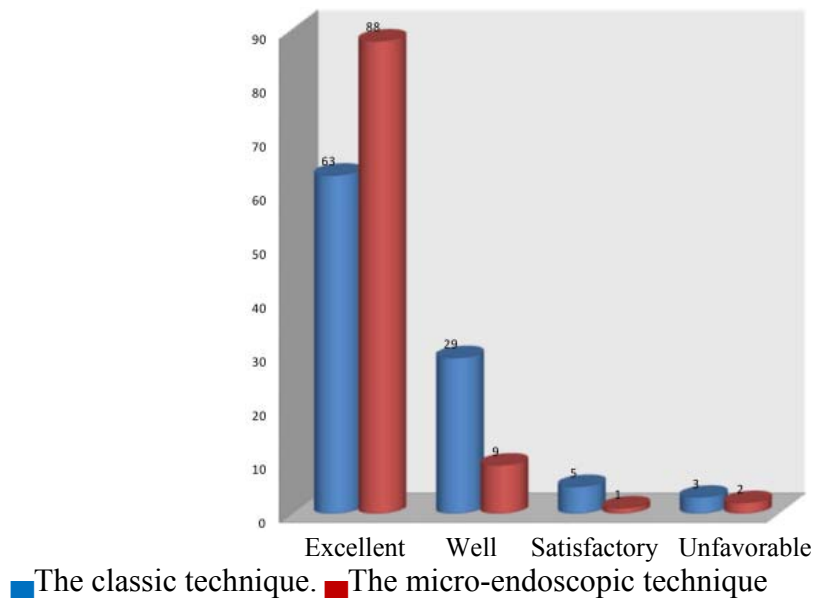


Fig.14: Evolution of the patients (modified Macnab criteria)

In conclusion, the use of the Endospine system in surgical treatment of lumbar disc hernia does not modify the surgical indications. The careful selection of the patients is the key of the excellent postoperative evolution. In this minimally invasive technique it is important to know the location of the affected level in two steps (preoperative and intraoperative) in order to avoid wrong approach. The better visualization offered by the endoscope must be fructified by the surgeon to realize a less aggressive

manipulation and resection thus preventing appearance of adherence postoperatively and extended bone resection, a possible source of instability. Another advantage is lower rate of complications (4%) compared to classic (10%). It also reduces the hospitalization and cost, which reduce the socio-economic impact of this pathology. The initial and long-term results are very good for endoscopic lumbar discectomy, so in selected patients we recommend this method.

References

1. Dickman RD, Zigler JE. Discogenic back pain. In: Spivak JM, Connolly PJ, eds. Orthopaedic knowledge update: Spine 3, Rosemont, IL: North American Spine Society, 2006: 319-329
2. Destandau J. Technical features of endoscopic surgery for lumbar disc herniation: 191 patients. *Neurochirurgie*. 2004;50:6-10
3. Smith MM, Foley KT. Microendoscopic discectomy (MED): surgical technique and initial clinical results; Proceedings of the Thirteen annual Meeting of the joint section of Disorders of the Spine and Peripheral Nerve of the American Association of Neurological Surgeons; 1997 Feb; Newport Beach, CA.
4. Destandau J. A special device for endoscopic surgery of lumbar disc herniation. *Neurol Res*. 1999;21:39-42
5. Roshan B, Bhavna K, Kisan P. Long-term results of endoscopic lumbar discectomy by "Destandau's Technique" *Asian Spine J*. 2016 Apr; 10(2): 289-297
6. Bruske-Hohlfeld I, Merritt JL, Onofrio BM, et al. Incidence of lumbar disc surgery: a population-based study in Olmsted County, Minnesota, 1950-1979. *Spine* 1990; 15:31-35
7. Kelsey JL, Githens PB, O'Conner T, et al. Acute prolapsed lumbar intervertebral disc: an epidemiologic study with special reference to driving automobiles and cigarette smoking. *Spine* 1984; 9:608-613
8. Spangfort EV. The lumbar disk herniation: a computer -aided analysis of 2504 operations. *Acta Orthop Scand Suppl* 1972; 142: 1-95
9. Weber H. Lumbar disk herniation: a controlled, prospective study with ten years of observation. *Spine* 1983; 8:131-140
10. Kelsey JL, Ostfeld AM. Demographic characteristics of persons with acute herniated lumbar intervertebral disk. *J Chronic Dis* 1975; 28: 37-50
11. Miller JA, Schmatz C, Schultz AB. Lumbar disk degeneration: correlation with age, sex and spinal level in 600 autopsy specimens. *Spine* 1988; 13: 173-178
12. Nachemson A, Lewin T, Maroudas A, Freeman MA. In vitro diffusion of dye through the end-plates and the anulus fibrosus of human lumbar inter-vertebral disks. *Acta Orthop Scand* 1970; 41: 589-607
13. Meredith DS, Huang RC, Nquyen J, Lyman S. Obesity increases the risk of recurrent herniated nucleus pulposus after lumbar microdiscectomy. 2010; 10/7: 575-580
14. Ciapetta P, Delfini R, Cantore GP. Intradural lumbar disc hernia: description of three cases. *Neurosurgery*, 1981; 8: 104-107
15. Kataoka O, Nishibayashi Y, Sho T. Intradural lumbar disc herniation: Report of three cases with a review of the literature. *Spine*, 1989; 529-533
16. Caaragee EJ, Han MY, Suen PW, Kim D. Clinical outcomes after lumbar discectomy for sciatica: the effects of fragment type and annular competence. *J Bone Joint Surg*. 2003; 85: 102-108
17. Donceel P, Du Bois M. Predictors for work incapacity continuing after disc surgery. *Scand J Work Environ Health*. 1999; 25: 264- 271
18. Dzioba RB, Doxey NC. A prospective investigation of the orthopedic and psychological predictors of outcome of first lumbar surgery following industrial injury. *Spine*. 1984; 9: 614-623
19. Herron L, Turner JA, Novell LA, Kreif SL. Patient selection for lumbar discectomy with a revised objective rating system. *Clin Orthop Relat Res*. 1996; 325: 148-155
20. Hoffman RM, Wheeler KJ, Deyo RA. Surgery for herniated lumbar discs: a literature synthesis. *J Gen Intern Med*. 1993; 8: 487-496
21. Kjellby-Wendt G, Styf J. Early active training after lumbar discectomy. A prospective, randomized, and controlled study. *Spine*. 1988; 23: 2345-2351