



## **Percutaneous nephrostomy in women: A retrospective review of an audit of procedures undertaken in one year with a review of the literature**

**Anthony Kodzo-Grey Venyo\***, **Christiana Oluwashola Fatola\*\***, **Ali Nawaz Khan\*\*\***

Department of Urology,\* Ear Nose and Throat\*\*, and Radiology\*\*\*, North Manchester General Hospital, Manchester United Kingdom

### **Abstract**

Percutaneous nephrostomy (PCN) is inserted for a variety of causes in women and the associated complications should be known by health care workers. The aim of the study was to audit PCN insertions undertaken in women over a one-year period (2014) in order to ascertain the outcome, complications and their management, the age distribution and causes/indications for the procedures. Various sections of the Health Views System including the PACS Centre Web, The Radiology Results Section, The laboratory Results section, and the automated letter system were used to obtain all the relevant data of women who underwent PCN insertions in 2014. Seventy-one patients whose ages had ranged between 18 and 96 underwent 86 procedures in one year with 100% success. Five patients had minor complications during the procedure (3 minor haemorrhages, one nausea and vomiting episode). Whilst in the ward post procedure, one patient was treated for UTI and two patients experienced transient non-drainage of nephrostomy tubes which were successfully flushed and 16 patients were readmitted after their discharge because of urinary tract infection, non-drainage of nephrostomy tubes which were either flushed successfully or a new nephrostomy tube was inserted, nephrostomy tubes that were dislodged or had fallen out requiring insertion of new nephrostomy or nephrostomy tube related pain/discomfort which required analgesia. There was no severe haemorrhage. PCN insertion can be carried out safely in women of all ages including very old patients. The complication rate in our experience is low. Nephrostomy tube blockage/falling out may occur which the urologist and radiologist should expect to manage. Perhaps regular flushes of nephrostomy tubes may help reduce the frequency of nephrostomy tube blockages. Radiology departments should have trained interventional radiologists capable of inserting nephrostomies.

**Key Words:** Percutaneous nephrostomy; women; sepsis; infection; obstruction; complications

**\*Corresponding Author: Dr. Anthony Kodzo-Grey Venyo, MB, ChB, FRCS(Ed), FRCSI, FGCS, Urol. LLM. Department of Urology, North Manchester General Hospital, Delaunay's Road, Crumpsall, Manchester, United Kingdom. Email: [akodzogrey@yahoo.co.uk](mailto:akodzogrey@yahoo.co.uk)**

Received: June 20, 2016 Accepted: September 12, 2016. Published: September 20, 2016. This is an open-access article distributed under the terms of the Creative Commons Attribution License, which permits unrestricted use, distribution, and reproduction in any medium, provided the original author and source are credited.

### **Introduction**

Percutaneous nephrostomy (PCN) is well-established ultra-sound scan / fluoroscopic guided percutaneous insertion of a catheter into the renal

collecting system. PCN was first described by Goodwin et al. [1] in 1955 and since then the procedure has been performed for many years in the developed countries and with development in interventional radiology the number of departments undertaking the procedure has continued to increase in the developed countries. Furthermore, development of interventional radiology has gradually increased in a number of developing countries whereby percutaneous nephrostomies are gradually being inserted in a number of these developing countries. Percutaneous nephrostomies initially were mostly inserted in adults including men and women but percutaneous nephrostomies have been inserted in children as well. Indications for PCN insertion in women may be related to obstetric and gynaecological or non-obstetric / gynaecological origin conditions. A number of problems / complications may be encountered related to PCN

insertions. It is important for every unit undertaking insertion of percutaneous nephrostomy to ensure that the complications associated with insertion of nephrostomy is low. Chalmers et al. [2] undertook an initial United Kingdom wide retrospective nephrostomy audit which had included 3262 cases over a period of 29 months. They reported a technical success rate of 98% and an overall complication rate of 6.3% with one or more complications. There are very few publications related to complications associated with insertion of per-cutaneous nephrostomies.

### Aims

To review records of all cases of PCN insertion performed in women (adults) from January 2014 to December 2014 in order to document.

- (1) Ages
- (2) Cause / indication for the PCN
- (3) Outcome (success/failure to insert nephrostomy and reasons for failure)
- (4) Complications and if any treatment given for the complications

### Methods

Preparations and aftercare for nephrostomy or ureteric stent insertion

In order to provide effective nephrostomy service and minimize the interventional radiology team has maintained a preparation and after care guideline for insertion of percutaneous nephrostomy and insertion of ureteric stent and the guidelines have been revised periodically. The current guidelines are as follows:

#### (A) Pre-procedure guidelines

- Haematological and serum biochemistry results of the patient are obtained inclusive of full blood count, serum urea and electrolytes and coagulation screen. The nephrostomy procedure is carried if the following conditions are met: (i) haemoglobin > 10, (ii) Platelets >60, (iii) INR < 1.4)
- The Methicillin resistant staphylococcus (MRSA) status is checked, and the procedure is undertaken when negative
- For elective nephrostomy insertion, the patient is not allowed to take any food by mouth 4 hours before the procedure as well as not allowed any water to drink 2 hours before the procedure, unless the procedure has been discussed and accepted as a very urgent procedure. However, patients who require hydration are given intravenous fluids as may be required

- To ascertain that the patient who would be undergoing nephrostomy insertion is stable prior to the procedure, the patient's baseline observations including blood pressure, heart rate, respirations, oxygen saturation, temperature and pain score are recorded.
- A 20 gauge (20 G) cannula is inserted intravenously
- Patients who are diagnosed as having sepsis should have intravenous fluids prescribed and running.
- A print of the patient's EPMA (all prescribed medications of the patient) must accompany the patient to the nephrostomy procedure room.
- Antibiotics should be administered to the patient one hour preceding the procedure. Co-amoxiclav 1.2 grams intravenously of Gentamycin 5mg/kg (maximum dose 320 mg) if the patient is allergic to penicillin. In the situation when the patient is MRSA positive, a single dose of Teicoplanin 400mg intravenously is administered in addition to the other antibiotics.

In the earlier guidelines, the patients were routinely given analgesia (for example 50 mg pethidine to minimise/avoid the patient developing pain during the procedure) as well as an anti-emetic (to minimise nausea which may be associated with the administration of analgesia like pethidine). With the new guidelines patients are not routinely given analgesia and anti-emetic in the ward prior to the procedure. This is because at times the effect of the analgesia may impair the ability of some of the patients to interact with the interventional radiologist during the procedure and may not respond well with regard to following instructions related to their positioning on the table during the procedure. Furthermore majority of patients undergo the procedure well without the analgesia; however, if a patient requires analgesia during the procedure of nephrostomy this can be given carefully by titration.

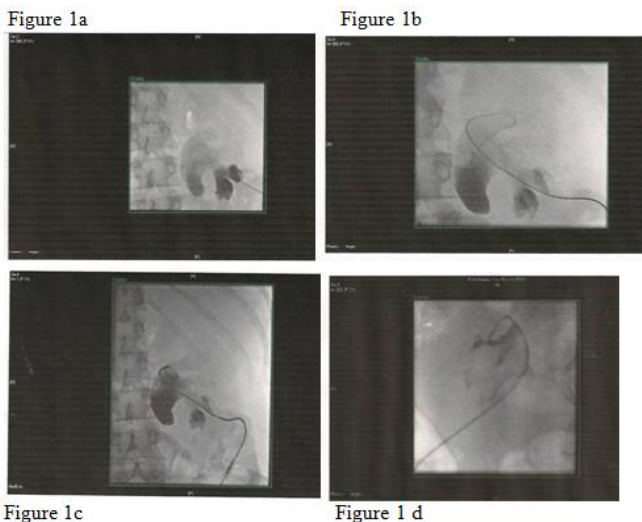
#### (B) Post-procedure guidelines

- Pursuant to the procedure, the patient should nil by mouth for 2 hours
- A number of the patient's parameters are monitored as follows: blood pressure, heart rate, respirations, oxygen saturation, temperature, and pain score. The blood pressure should be measured ½ hourly for initial 2 hours, then hourly for the next 2 hours, and then 4 hourly.

- The patient is observed for signs of blood loss or worsening sepsis, loin pain, tachycardia, hypotension and increased temperature. In the situation when any or some of the aforementioned parameters are observed to be worsening the Urology team is notified immediately.
- The amount and colour of the urine draining through the nephrostomy tube drainage system is recorded and in the event of no drainage of urine out of the nephrostomy tube then the urology team is informed immediately.
- The nursing staff must observe the patient and ensure that the patient is comfortable and the patient is given analgesia as prescribed.
- The patient may need to have an overnight stay in hospital for further observation.
- The patient must be reviewed by a doctor before being discharged.

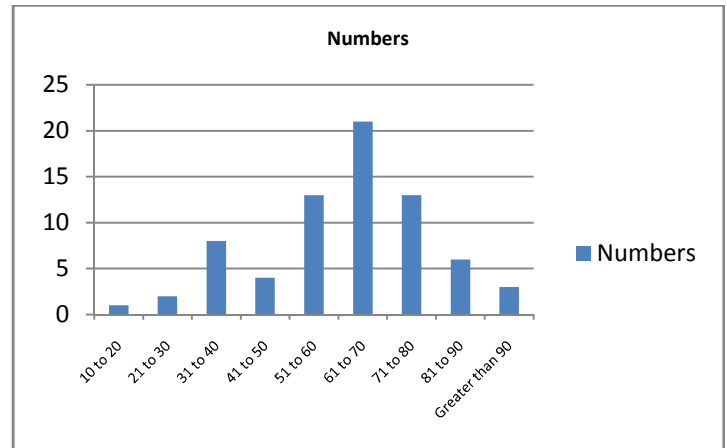
**Percutaneous nephrostomy insertion techniques**

Generally two different types of ultrasound scan-guided techniques can be utilised for the insertion of percutaneous nephrostomy and these include: the Seldinger technique and the “one-step” technique. [3] At the start of the procedure the patients tend to be placed in prone or in prone-oblique position for the percutaneous insertion of the nephrostomy. It is routine practice to give the patients prophylactic antibiotics prior to the procedure. The patients are given analgesia (for example Pethidine intramuscularly or by means of intravenous titration), as well as antiemetic. Coagulation screen is also undertaken prior to the procedure which is undertaken when the INR is 1.3 or below.

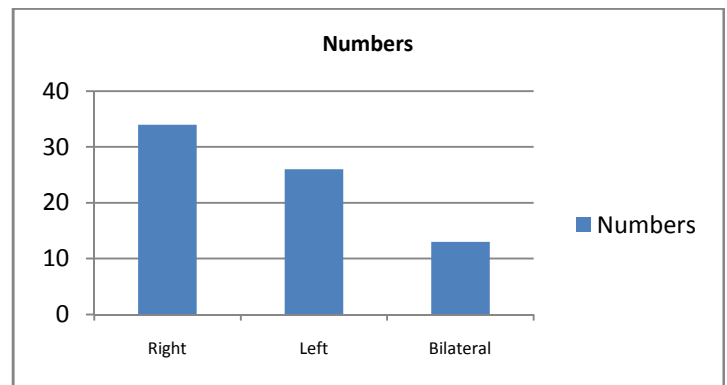


**Figures 1a to 1d:** Show steps of the procedure of

insertion of nephrostomy. Figure 1a: This figure shows that the right lower calyx has been punctured with a Chiba needle. Figure 1b: This figure shows that an Amplatz guide-wire has been advanced in to the right renal pelvis. Figure 1c: This figure shows a Nephrostomy tube size 6 Fr is in situ. Figure 1d: This figure shows a left Nephrostomy tube in situ



**Figure 2:** Age distribution of patients

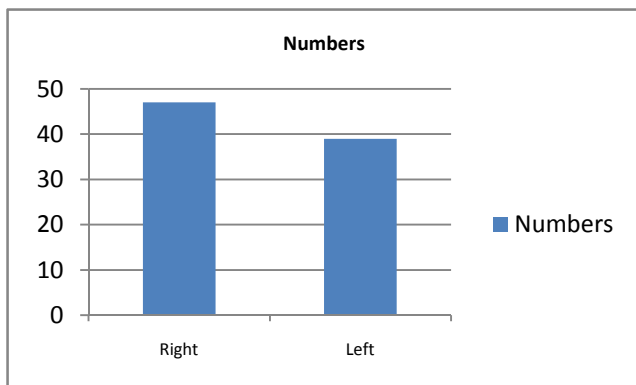


**Figure 3:** Site of nephrostomy insertion

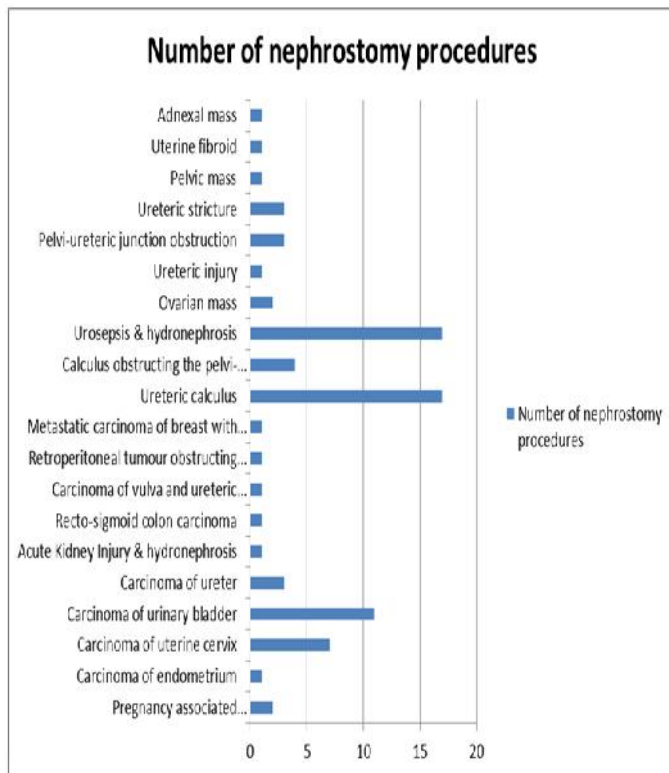
The selection criteria used to select the technique used for the procedure depends upon the anatomical configuration of the renal collection system. “The Seldinger technique” tends to be the approach of choice used for non-dilated renal collecting systems and for cases of suspected pyonephrosis. This technique is undertaken with ultra-sound scan and fluoroscopic guidance. The “one-step” technique which is also called the Bonanno technique tends to be used without the guidance of fluoroscopy for cases of moderate and severe dilated renal collecting systems.

The “Seldinger” technique entails ultrasound-guided puncturing of the dilated renal collecting system with the use of 19 G sheathed needle, placement of a 0.0038” heavy-duty J guide-wire and

serial dilation of the tract with the use of 6 to 10 F dilators up in order to accommodate 8 to 12 F nephrostomy catheters with or without the guidance of fluoroscopy (see figure 1, which depict stages of percutaneous nephrostomy insertion in a patient). Quite frequently, either Locking loop Pigtail (LLP) catheters (Cook Inc. USA) or All Purpose Drainage (APD) catheters (Boston Scientific, USA) have been used for per-cutaneous nephrostomy insertions.



**Figure 4:** Summary of sites of insertion of a total of 86 nephrostomy of procedures into right and left



**Figure 5:** Indications for insertion of nephrostomy

The second technique of percutaneous nephrostomy insertion which is called the “Bonanno technique” or the “one-stab/troca and cannula”

technique involves the utilisation of ultrasound scan-guided “one stab” technique which involves the use of a 6F Bonanno catheter (Beckton Dickenson UK Ltd). The pigtail Teflon catheter is usually mounted onto a hollow 18G needle with a sharp bevelled edge. With the guidance of ultrasound scan the needle tip is introduced and guided into the pelvi-calyceal and when urine backflow is obtained, the catheter is slid over the needle into the collecting system. At the end of the insertion of the nephrostomy, the nephrostomy catheter is next secured on to the skin with the use of catheter fixation disc which has been covered with adhesive dressings and then attached to a urinary drainage bag system.

The ultrasound scan-guided “one stab” technique is a quick and safe procedure option for temporary urinary diversion in selected cases of moderate to severe pelvi-calyceal system hydronephrosis. The primary technical success rate of percutaneous nephrostomy insertion has been reported to range between 88% and 99%, major complications reported have ranged between 4% and 8%, and minor complications associated with nephrostomy insertions reported have ranged between 3% and 15%. [4] Ultrasound-guided nephrostomy insertion is the preferred method for the management of symptomatic upper urinary tract obstruction or urosepsis in pregnancy. [5]

With regard to the insertion of nephrostomy in the unit, quite often a combination of ultrasound guidance to localise the kidney and the pelvi-calyceal system and radiological screening is used for the procedure. A needle with an outer sheath is introduced percutaneously through the kidney into the renal pelvis under ultrasound scan guidance and upon withdrawal of the needle and aspiration of urine, a guidewire is introduced through the channel in the lumen of the outer sheath of the puncturing set under radiological screening control and the tract is dilated over the guide-wire under the same radiological control and an 8Fr nephrostomy tube is inserted with a locking device and the end of the nephrostomy tube is placed in a nephrostomy bag which is then secured to the skin and the patient’s back. The procedure tends to follow the technique described by Siddiqi and Schwartz [6] as follows: Pursuant to appropriate preparation of the patient, a small skin incision in the form of a nick tends to be made at the puncture site in order to enable passage of the needle into the skin. The route of entry of the needle into the collecting system of the kidney tends to be usually along an oblique posterior lateral approach along the Brodel line into the end of a

posterior calyx. This line which is near the posterior axillary line tends to approximately 2cm to 3 cm below the 12<sup>th</sup> rib. The needle which usually tends to be a 21-gauge or 22-gauged, is then angled towards a posterior lower pole calyx or middle pole calyx under ultra-sound scan guidance. With regard to the situation when the collecting system is not dilated contrast medium tends to be given by the intravenous route to enable adequate visualisation of the collecting system. Following insertion of the needle into the calyx and into the renal collecting system, the stylet is next removed and urine is obtained if there is an obstruction of the upper renal tract. In the situation when urine is not obtained, a 10 ml needle tends to be attached to the needle hub, and the needle and syringe retracted slightly, and if urine is aspirated then the tip of the needle is adjudged to be probably in the collecting system. Once the collecting system is accessed, urine specimen tends to be obtained for microscopy, culture and sensitivity. Contrast medium tends to be gently injected into the collecting system to visualise and confirm the location. Once access to the collecting system has been obtained, wire exchanges are continued until a 0.035 in. J-tip wire is placed into the renal pelvis or down into the ureter. The tract is then dilated with polytetrafluoroethylene dilators (but some people also use metal dilators [7] [8] or cutting balloons [9]) The drainage catheter is then flushed, and the trocar that comes with the nephrostomy kit is inserted. The catheter is then advanced into the proximal renal parenchyma over the 0.035-in guide-wire, the trocar is then loosened, and the catheter slipped off the trocar and into the renal pelvis. The internal wire is then pulled to lock the pigtail catheter, ensuring that the catheter is seated approximately in the renal pelvis. The position of the catheter is next checked by using contrast material and the catheter is then tied to the skin with suture and attached to the external drainage bag. [10]

#### Data Collection

A list of all women who underwent nephrostomy insertions between January 2014 and December 2014 at North Manchester General Hospital was obtained from the PACS Manager of the hospital.

The PACS System was used to obtain details of all women who had undergone insertion of percutaneous nephrostomy to work out the patients' ages, sides of nephrostomy insertion, outcome of the insertion procedure whether successful or not and the reason for non-success; immediate complication or

no immediate complication, the indication / cause of obstruction

The Automated Letter System (ALS) in the Health Views System was used to confirm the details obtained from the PACS system to be sure the details noted in the PACS system were correct and to document discharge letter and follow-up data to document if there were any late complications as well as treatment / outcome of these treatments. Documentation of adherence to nephrostomy protocol of (a) normal pre-procedure coagulation, (b) pre-procedure antibiotic medication; (c) pre-procedure analgesia medication, (d) pre-procedure anti-emetic medication was recorded. The cause of the obstruction / indication for the obstruction was recorded and immediate and late outcome were recorded plus further treatment documented. It was noted down whether or not there was any blood transfusion post-procedure and the reason for the transfusion. Follow-up details and re-admissions as well as reasons for re-admission were documented including any further treatment and outcome following treatment.

The laboratory results were checked to assess the full blood count results before and after the procedure; the serum urea and electrolytes before / after the procedure; the coagulation screen profile before the procedure; evidence of cross matching of blood after the procedure if any and the ALS system checked for evidence blood transfusion and post transfusion results.

#### Results

Seventy one women including 2 pregnant women underwent 86 procedures of percutaneous nephrostomy insertions. The ages of the women ranged between 18 years and 96 years and their mean age was 57 years. The distribution of the patients by age group were as follows: 10 years to 20 years – 1; 21 years to 30 years – 2; 31 years to 40 years – 8; 41 years to 50 years – 4; 51 years to 60 years – 13; 61 years to 70 years – 21; 71 years to 80 years – 13; 81 years to 90 years – 6; Greater than 90 years - 3 (see figure 2). With regard to the sites of nephrostomy insertions, 34 PCN insertions were performed on the right side, 26 of the PCN insertions were on the left side and 13 of the PCN insertions were bilateral (figure 3). On the whole with regard to the side of insertion of the PCNs whether right or left side, 47 PCNs were inserted on the right and 39 PCN insertions were on the left (see figure 4). With regard

to the diagnosis / indication for the PCNs insertions, the following were documented (see figure 5):

- Pregnancy associated worsening hydronephrosis - 2 cases
- Carcinomas
  - Carcinoma of the endometrium - 1 case
  - Carcinoma of the cervix - 7 cases
  - Carcinoma of the urinary bladder - 11 cases
  - Carcinoma of the ureter – 3 cases
  - Recto-sigmoid carcinoma – 1 case
  - Carcinoma of the vulva – 1 case
  - Retroperitoneal tumour obstructing the renal pelvis – 1 case
  - Metastatic carcinoma of the breast with ureteric obstruction – 1 case
- Calculus
  - Ureteric calculus – 17 cases
  - Renal pelvis calculus with Pelvi-ureteric junction of obstruction – 4 cases
- Miscellaneous causes
  - Acute kidney injury and hydronephrosis – 1 case
  - Urosepsis and hydronephrosis – 17 cases
  - Ovarian mass – 2 cases
  - Ureteric injury – 1 case
  - Pelvi-ureteric injury obstruction – 3 cases
  - Ureteric stricture – 3 cases
  - Pelvic mass – 1 case
  - Uterine fibroid – 1 case
  - Adnexal mass – 1 case

With regard to complications, there was no life threatening complication as such but the following complications were recorded in the immediate peri-procedure period: 1 patient out of the 71 patients (1.4% of patients) who underwent 86 procedures (about 1.2% incidence of nausea and vomiting out of 86 procedures) developed nausea and vomiting despite having had antiemetic prior their procedures; Four patients were noticed during their procedures to have had haematuria (about 4.7% of the procedures), one of the patients was noted to have developed a small haematoma in the renal pelvis on ultra-sound scan screening but in all the four episodes the haematuria settled spontaneously with clear urine in the nephrostomy tubes after observation and none of the patients required any blood transfusion (see table 1 for complications that were observed during the procedure).

With regard to complications that were noticed out of the 86 procedures of PCN insertions after the procedures, whilst on admission after insertion of the nephrostomies, one patient (1.2% of

the procedures out of 86) developed pyrexia and was treated for urinary tract infection / urosepsis with antibiotics and this settled. The nephrostomy tube of one patient stopped draining after four days but after flushing of the nephrostomy tube with normal saline the nephrostomy started draining again without requiring any further action. One patient had bilateral nephrostomy insertions and six days after the nephrostomy insertions both nephrostomy tubes stopped draining and she had bilateral nephrostograms which showed no evidence of obstruction and after she was rehydrated for dehydration both of her nephrostomies started draining well before she was discharged. In all during the procedures of insertion of 86 PCNs, and during the duration of stay of the patients prior to their discharge a total of 8 (11.3%) patients out of the 71 patients who had undergone 86 PCN insertions developed 9 minor complications (about 10.5%) out of the 86 procedures undertaken were associated with minor non-life threatening complications during the procedures and or during the period admission of the patients for the procedures.

| Complications  | Number | Treatment and Outcome   |
|--|--------|---|
| Mild bleeding with small clot noticed in renal pelvis during procedure | 1      | Settled after observation with nephrostomy urine becoming clear on ward and no treatment was required |
| Mild haematuria documented at end of procedure                         | 3      | Settled after observation with nephrostomy urine becoming clear on ward and no treatment was required |
| Nausea and vomiting despite having had pre-procedure antiemetic        | 1      | This subsided with one more anti-emetic treatment   |

**Table 1:** Complications noticed during the procedure

After discharge of the 71 patients from hospital after undergoing 86 procedures 16 of the patients (22.5% of patients and 18.6% of procedures) subsequently developed various problems at home for which they had to be seen by their general practitioners and were referred back to hospital. The complications included: Blocked nephrostomy tubes,

urinary tract infections, nephrostomy tube being dislodged or falling out accidentally during change of nephrostomy bags (see table 2 for the detail account of the individual complications noted on the ward and after discharge). One patient who had undergone percutaneous nephrostomy in the 2013 which was successfully flushed developed another blockage of her nephrostomy in 2014 and this required insertion of a new nephrostomy after removal of her old nephrostomy but was observed not to have developed any further blockage of her nephrostomy tube in 2014 (during the study period). With regard to the brake down of the blocked nephrostomies, apart from the two patients whose nephrostomy tubes stopped draining after insertion of the nephrostomies and were successfully flushed before their discharge, six other patients developed 7 blocked nephrostomies after discharge as follows: One patient developed blockage of her nephrostomy tube four times over a six weeks period and she was admitted and observed on each occasion after flushing of her nephrostomy and on each occasion the flushing of the tube was successful and she was discharged. One patient developed blocked nephrostomy tube associated with urinary tract infection 6 weeks after insertion of her nephrostomy tube and she was successfully treated with antibiotics and after flushing of the nephrostomy tube, the nephrostomy started draining well and she was discharged. One patient subsequently developed blocked nephrostomy which could not be successfully flushed therefore the old nephrostomy tube was removed and a new nephrostomy was successfully inserted during her re-admission. One patient developed blocked nephrostomy and hypotension and she was during her re-admission treated by means of intravenous fluids, intravenous antibiotics and her nephrostomy tube, was successfully flushed and she was discharged home. One patient had blocked nephrostomy tube which was flushed successfully and she was discharged after observation. One patient underwent insertion of bilateral nephrostomies who was subsequently re-admitted because one of the nephrostomy tubes was not draining and the nephrostomy could not be flushed successfully she had nephrostogram which showed obstruction of the nephrostomy tube and old

nephrostomy tube was removed and a new nephrostomy tube was successfully inserted. One patient had intermittent blockage of her nephrostomy tube which was flushed successfully initially; however, subsequently her nephrostomy tube could not be successfully flushed and she had nephrostogram which confirmed obstruction therefore the old nephrostomy tube was removed and a new nephrostomy was inserted successfully. With regard to dislodgement or falling out of nephrostomy, One patient's nephrostomy tube got dislodged at home and she was readmitted and a new nephrostomy was inserted, the nephrostomy tube of another patient was subsequently dislodged and she was also readmitted and she had a successful insertion of a new nephrostomy, the nephrostomy tube of another patient fell out at home and she developed urinary tract for which she was re-admitted and she was treated successfully with antibiotics and a new nephrostomy was inserted and she was discharged home after her recovery, the nephrostomy tube of another patient fell out at home and she was re-admitted and a new nephrostomy was successfully inserted, the nephrostomy tube of yet another patient subsequently fell out and she was readmitted and a new nephrostomy was inserted. With regard to urinary tract infection / urosepsis, one patient was successfully thrice with antibiotics for nephrostomy associated urinary tract infection, one patient was readmitted subsequently because of urinary tract infection and was successfully treated with antibiotics, one patient was admitted with a diagnosis of urinary tract infection / urosepsis and she was successfully treated with intravenous antibiotics, one patient was admitted and successfully treated with antibiotics for urinary tract infection, one pregnant lady had urinary tract infection and blockage of her nephrostomy tube who was successfully treated with antibiotics and her nephrostomy was changed. One patient was seen 10 days after she had had insertion of nephrostomy who complained of pain at the site of her nephrostomy insertion site and on examination and assessment she was found not to have an infection and she was given analgesia for her pain/discomfort in the nephrostomy site and this took away her pain and she was discharged.

**Table 2:** Observed complications, on the ward after the procedure of PCN insertions and after discharge of the patients.

| Case Number | Nephrostomy side | Complication               | Treatment + Outcome  |
|-------------|------------------|----------------------------|--|
| 1           | Unilateral       | Nephrostomy blocked twice; | Had Nephrostomy in 2013 blocked in Dec 2013 flushed successfully; Blocked nephrostomy in 2014 flushed unsuccessfully which was the indication for the new nephrostomy insertion but no further blocked nephrostomy |

|          |   |   |  |
|----------|---|---|--|
|          |   |   | (no complication during the study period therefore not included as a complication during the study period) |
| Case 3   | Unilateral left   | Blocked nephrostomy four times over 6 weeks period and flushed successfully         | Flushed successfully each time and patient discharged after observation each time                          |
| Case 5   | R Nephrostomy first<br><br>Had left nephrostomy later but no complication | Urosepsis/UTI thrice later<br><br>No complication                                   | Treated thrice for UTI recovered and was discharged  |
| Case 6   | Unilateral left   | E coli UTI later  | Treated successfully with ciprofloxacin  |
| Case 10  | Unilateral left   | Displaced nephrostomy subsequently  | New nephrostomy inserted as replacement  |
| Case 13  | Unilateral right  | UTI/Urosepsis later   | Treated with intravenous antibiotics successfully  |
| Case 14  | Unilateral nephrostomy plus ante-grade stent insertion                    | Developed urinary tract infection later   | Treated successfully with antibiotics  |
| Case 17  | Unilateral left   | Blocked nephrostomy 6 weeks later + UTI   | Treated successfully with antibiotics and nephrostomy successfully flushed                                 |
| Case 21  | Bilateral   | One nephrostomy subsequently blocked  | Nephrostomy reinserted successfully  |
| Case 22  | Unilateral left   | Nephrostomy subsequently dislodged  | New nephrostomy successfully re-inserted   |
| Case 23  | Unilateral right  | Urosepsis/UTI post-procedure (in ward during initial admission not after discharge) | Successfully treated with intravenous fluids and antibiotics   |
| ?Case 28 | Bilateral   | Left nephrostomy subsequently blocked hypotensive                                   | Intravenous fluids; antibiotics nephrostomy successfully flushed   |



|         |                                |  |  |
|---------|--------------------------------|--|--|
| Case 35 | Unilateral right               | Nephrostomy subsequently blocked   | Nephrostomy successfully flushed   |
| Case 49 | Unilateral left                | Nephrostomy subsequently fell out and patient had urinary tract infection  | New nephrostomy inserted and patient was successfully treated with antibiotics               |
| Case 52 | Bilateral left and later right | She later fell down not related to procedure; One nephrostomy fell out (Right)   | New nephrostomy was successfully inserted  |
| Case 59 | Unilateral left                | Nephrostomy subsequently fell out  | New nephrostomy successfully inserted  |
| Case 60 | Bilateral                      | Left nephrostomy subsequently not draining 4 days later (in ward after procedure before discharge)                                   | Left nephrostogram done and flushed successfully   |
| Case 63 | Unilateral right               | No complication from operation but subsequently died out of hospital of disease but cause of death not a complication of nephrostomy |  |
| Case 64 | Bilateral                      | Both nephrostomies not draining 6 days later (in the ward after procedure before discharged)   | Bilateral nephrostograms showed no obstruction; patient rehydrated and nephrostomies drained |

|         |  |   |   |
|---------|--|---|---|
|         |  | home)   |   |
| Case 65 | Bilateral nephrostomy + ante-grade stent | One nephrostomy blocked   | Nephrostomy changed (new nephrostomy inserted) successfully   |
| Case 69 | Unilateral Right                         | Reported pain at nephrostomy site 10 days later and nephrostomy draining not abnormality found                                | Analgesia prescribed and no problem after that  |
| Case 73 | Unilateral; pregnant lady                | Subsequently had pain nephrostomy site and had intermittent episodes of no drainage from nephrostomy site and E coli UTI once | Treated successfully initially by flushing and antibiotics successfully but for subsequent nephrostomy blockage and unsuccessful flushing of nephrostomy she had nephrostogram at the latter end of the third trimester of her gestation with shielding of the baby from radiation which showed obstruction therefore the old nephrostomy was removed and a new nephrostomy was inserted successfully and after delivery of baby subsequent nephrostogram showed free drainage and nephrostomy tube was successfully removed. |

The complications of the 16 patients can be summarized as follows:

- Four patients were readmitted and treated for nephrostomy tube related urinary tract infection / urosepsis alone (three of the patients were admitted once and one patient was treated on three separate occasions for urinary tract infection) and all the patients were discharged home after recovery.
- One patient was re-admitted because of urinary tract infection and non-drainage of her nephrostomy and she was treated with antibiotics and nephrostomy on flushing drained well and she was discharged home well and her nephrostomy was draining well.
- One patient developed urinary tract infection after her nephrostomy tube had fallen out at home. She was re-admitted and treated with antibiotics and a new nephrostomy was inserted. .
- One patient was re-admitted because of urinary tract infection and loin pain and intermittent non-drainage of her nephrostomy and she was successfully treated by means of antibiotics and flushing of her nephrostomy but subsequently she developed complete obstruction of her nephrostomy which required nephrostogram with protective shielding of her baby because she was pregnant and a successful removal of the old nephrostomy and insertion of a new nephrostomy.
- One patient was re-admitted because of urinary tract infection and loin pain and intermittent non-drainage of her nephrostomy and she was successfully treated by means of antibiotics and flushing of her nephrostomy but subsequently she developed complete obstruction of her nephrostomy which required nephrostogram with protective shielding of her baby because she was pregnant and a successful removal of the old nephrostomy and insertion of a new nephrostomy.
- One patient was readmitted six times because of non-drainage of (blocked) nephrostomy and on each occasion the nephrostomy started draining well and she was discharged home after observation.
- The nephrostomy tubes of two other patients stopped draining and they were re-admitted their nephrostomy tubes were flushed successfully and after observation and hydration they were discharged.
- Three patients were re-admitted because of blocked nephrostomies (each one had one nephrostomy) but after non-successful flushing of the nephrostomies and nephrostogram

confirmation of blocked nephrostomies a new nephrostomy was successfully inserted on each occasion.

- One patient had accidental dislodgement of her nephrostomy tube which stopped draining and she was re-admitted and a new nephrostomy was inserted and she was discharged.
- The nephrostomy tubes of two patients accidentally fell out at home and they were re-admitted and on each occasion a new nephrostomy was successfully inserted.
- One patient complained of pain at the nephrostomy inserted site 10 days after the procedure but on re-admission no abnormality was found upon assessment and she was discharged after she had been given analgesia.

## Discussion

Lewis and Patel [11] reported an audit of the performance of their percutaneous nephrostomy service by comparing the major complication rate with the standards which had been recommended by the Society of Cardiovascular and Interventional radiology and the American College of Radiology which recommended that major haemorrhage should occur in less than 4%, and septic shock should occur in less than 4% of patients who undergo insertion of percutaneous nephrostomies. They also undertook the audit in order to identify common sources of errors for quality improvement. They established the major complications which were associated with percutaneous nephrostomy insertions that had been sustained between January 1997 and December 2002. They indicated that their departmental protocols specified pre-procedure antibiotics for suspected infected cases and normal coagulation studies. Lewis and Patel [11] reported that out of 31 cases, 10 (3.1%) cases were associated with a major complication as follows: five of the cases were associated with sepsis alone, two of the cases were associated with haemorrhages (one with sepsis as well) and 3 of the patients had developed a major pelvic injury (1 also had sepsis). They also reported that the major sepsis and haemorrhage rates were 2.2% and 0.6%, which fell within the recommended threshold limits. Nevertheless, Lewis and Patel [11] iterated that proportionately, they observed that more complications did occur out of hours and these included six out of 105 (5.7%) versus 4 of 312 (1.%;  $p=0.07$ ). Lewis and Patel [11] further reported that:

- Sepsis constituted the most serious complication which might have played a contributory role in the death of two patients.
- The results of individual case analysis had shown that failed instrumentation and delay to definitive drainage of the obstructed renal tract was a common factor associated with sepsis; however, the following were adjudged to have been contributory factors in one or more cases: omitted antibiotics (in 3 out of 10 cases; two became septic), technical factors in four of the cases [medial renal puncture (in one case), damage due to fascial dilator (in one case) or peel-away sheath (in two cases)] and delay in establishing diagnosis / effecting treatment (of one to eight days, in six out of 10 cases of whom four out of six had become septic). There was one case of pelvic injury which required surgical correction (the adjudged contributory factor in this case was faulty use of peel-away sheath).
- Those patients who developed haemorrhages did settle with prolonged tube drainage alone.

Lewis and Patel [11] made the following conclusions:

- Percutaneous nephrostomy service which is adequately staffed can perform within published clinical standards.
- They had found out that the best practice factors include: attention to agreed protocols and algorithms; administration of pre-procedure antibiotics, undertaking of renal puncture carefully and careful use of dilators / peel-away sheaths, however, the most important finding was that sepsis was the most serious complication and this had been attributed to death (in two out of 10 cases in the study), or a significant increase in the level of care required.
- The risk of complications is greatest following failed instrumentation (insertion of retrograde ureteric stent or insertion of percutaneous nephrostomy) and particularly in the event of a further delay before the establishment of renal drainage.
- Establishment of a close working relationship between urologists and interventional radiologists is crucial.

Venyo et al. [12] reported two hundred and seventeen women patients who underwent 344 percutaneous nephrostomy insertions with 100% success. Venyo et al. [12] reported that: out of the 344 percutaneous nephrostomy insertions 19 patients developed 30 complications; no significant

haemorrhage developed with 0.9% moderate and minor haemorrhages which settled, there was no death and no severe sepsis; the ages of the patients who underwent nephrostomy insertions had ranged from 17 years to 95 years, nephrostomy tube blockage occurred in 11 (3%) of patients; the nephrostomy tubes fell out and were replaced in 7 (2%) cases, one case of urinary tract infection was encountered; the most common indications for the nephrostomy insertions were urinary tract calculi, transitional cell carcinoma of the urinary bladder, carcinoma of the cervix, urosepsis, pyonephrosis, and pregnancy. Venyo et al. [12] stated the following:

- The observation of a low rate of complications pursuant to insertion of nephrostomies in their cases could be related to strict adherence to percutaneous nephrostomy protocol of their interventional radiology unit which includes the following: (a) pre-procedure prophylactic antibiotics to be taken by all patients about half an hour preceding insertion of nephrostomy; (b) normal coagulation (the procedure would be postponed until the coagulation is normal in cases of impaired coagulation to avoid / reduce bleeding); (c) analgesia (pethidine) which is administered half an hour preceding the procedure to minimise pain during the procedure; (d) administration of anti-emetic to reduce nausea and vomiting associated with the analgesia.
- Although luckily there was no case of sepsis in their cases it is important to appreciate that despite the use of prophylactic antibiotics some patients may develop sepsis following insertion of percutaneous nephrostomy and clinicians as well as radiologists should be prepared to manage any episode of sepsis that may emanate.
- Despite the fact that none of their patients had severe bleeding following insertion of nephrostomy there is the possibility that severe haematuria in the nephrostomy tube may occur to require blood transfusion and very rarely the bleeding could be so severe that may require investigation for the cause of bleeding in the form of selective renal artery angiography and super-selective embolization of a minor branch of the renal artery to stop bleeding.
- After successful insertion of nephrostomy tubes some of the nephrostomy tubes may be blocked by debris resulting in reduction in nephrostomy tube output or no urine draining from the nephrostomy which may be associated with loin pain but most of these blockages can usually be successfully unblocked by flushing the nephrostomy tubes.
- They had found the use of 2 ml syringe and saline more easily unblocks nephrostomy tubes better than larger sized syringes. Occasionally the blocked nephrostomy tubes cannot be unblocked and would require nephrostogram and replacement of nephrostomy tube over a guide-wire.
- A number of their patients required admission to the ward for flushing of the nephrostomy tubes which were successfully done and it was felt that if the district nurses were adequately trained to flush the tubes then re-admission of the patients would be reduced.
- At times nephrostomy tubes may fall out accidentally or may be inadvertently pulled out in the process of changing the nephrostomy bag which would require change of nephrostomy.
- Furthermore nephrostomy tubes may dislodge in that the end of the nephrostomy tube may no longer be located in the renal pelvis which would require readmission and replacement of nephrostomy.
- Women with obstructed upper renal tract may be admitted under different medical specialties depending upon the cause of obstruction and the presentation and therefore such patients may be admitted in the Urology ward, the general surgical ward, the medical ward, as well as the obstetrics and gynaecology ward.
- A multi-disciplinary approach to the management of upper urinary is required and co-operation between interventional radiologists and clinicians is helpful in the management of patients. In cases where there is impairment of coagulation advice from a haematologist may be required. In cases of severe impairment of renal function an input from a nephrologist may be required. In cases where the patient's serum potassium level is high the use of insulin glucose to lower the serum potassium prior to insertion of nephrostomy would be a helpful approach in the management of the patient. When a patient with an obstructed upper urinary tract is acidotic the nephrologists tend to recommend the use of sodium bicarbonate. As part of a multi-disciplinary team approach sometimes patients who are very ill are managed in the high dependency unit prior to the insertion of nephrostomy and rarely a patient with severe renal impairment may initially undergo haemo-filtration prior to insertion of nephrostomy.

- The observation from their audit would confirm that nephrostomy insertion can be performed in patients of all age groups and old women with obstructed upper renal tract can successfully undergo nephrostomy insertions.

Venyo et al. [12] concluded as well as recommended that:

- Various non-obstetric/gynaecological and as well as gynaecological causes were responsible for upper ureteric obstruction requiring insertion of nephrostomies in their female patients.
- Nephrostomy insertion in women can be performed safely for a variety of causes of upper renal tract obstruction.
- The complication rate following insertion of percutaneous nephrostomy in women in their experience was low.
- Nephrostomy insertion can be safely undertaken in women of all ages including very old patients.
- Every radiology department should have a trained radiologist who is capable of undertaking insertion of nephrostomies and radiology departments which do not have interventional radiologists should endeavour to have some of their radiologists trained in order to undertake interventional radiological procedures, like insertion of per-cutaneous nephrostomies.

Venyo et al. [13] undertook a study: to find out the rate of insertion of nephrostomy tubes in their hospital between January 2009 and December 2013, and to identify the problems that emanated from insertion of the nephrostomies. Venyo et al. [13] reported that fifteen pregnant patients out of 24,683 deliveries (0.06%) in their catchment area underwent 17 nephrostomy insertion procedures. Venyo et al. [13] also reported that: All the insertion of nephrostomies, were successfully and safely undertaken; there was no immediate complication; the complications that were noted included subsequent blockage of nephrostomy tubes which required re-admission to flush the tubes to render them patent; two of the nephrostomy tubes subsequently fell out which replaced by insertion of new nephrostomy; one minor infection was encountered which was successfully treated with oral antibiotics; surgical causes of upper urinary tract obstruction found at post-partum nephrostogram included calculi and ureteric strictures which were managed post-partum; all the pregnancies had continued to full term with delivery of normal full-term babies. Venyo et al. [13] concluded that:

- Percutaneous nephrostomy insertion in the pregnant woman under ultra-sound scan guidance is a safe and effective procedure which is associated with minimal complications and which allows the pregnancy to continue to full term.
- The fact that the blocked nephrostomies could all be flushed to unblock the tubes would be indicative of the fact that if all district nurses are taught how to carefully flush nephrostomies, re-admission with blocked nephrostomies would be minimised.
- Strict adherence to nephrostomy protocol would partly help in the reduction of complications associated with nephrostomy insertion in pregnancy.

Negru et al. [14] undertook a retrospective study of 111 cases which were managed conservatively or by means of endoscopic urological procedures for renal colic (insertion of double J stents and per-cutaneous nephrostomy). Negru et al. [14] stated that clinical evolution was the determinant of the insertion of the double J Stent in 60 cases and the failure of insertion of double J stent had imposed insertion of per-cutaneous nephrostomy in 5 cases. Negru et al. [14] reported that urinary tract infection was associated in 56 cases and in 2 cases, despite all efforts, the patients died as a result of severe sepsis. Negru et al. [14] made the following conclusions.

- The immediate drainage of the upper urinary tract for renal colic in pregnancy is the recommended treatment, especially when the pain is associated with fever.
- Double J stents were well tolerated, even though they were replaced after three months.
- Pregnant women who have a history of urinary tract infection or stone disease should be carefully followed-up.

Doronochuk et al. [15] undertook a sociological study of quality of life of patients who had undergone nephrostomy drainage and 71 patients who had insertion of ureteric stents according to the standard international questionnaires SF-36 and EORTC QLQ-C30, version 3.0. Doronochuk et al. [15] observed that:

- Both internal and external drain significantly worsened the quality of life in the same degree.
- Younger patients of both groups (those who underwent nephrostomy insertion and the group that had insertion of ureteric stent) suffered less.

- The quality of life was higher in both groups in drainage duration of up to 1 month ( $p < 0.05$ ); in 1 to 6 month drainage duration, the quality of life was worse in both groups.
- Internal drainage (ureteric stent insertion) was worse tolerated by males who were aged 25 to 44 years and elderly women who were aged between 60 years and 75 years, particularly in cases of long-term drain (over 6 months).
- Internal drainage (ureteric stent insertion) was worse tolerated by elderly females (60 years old to 75 years old) and senile women (over 75 years old) in 6 month and longer drainage.

Doronochuk et al. [15] concluded that their study of a large number of patients did reveal significant differences in quality of life in patients with nephrostomy drain and ureteric stent.

Verdelo Pedro et al. [16] undertook a retrospective study of 162 pregnant women who had suffered symptomatic hydronephrosis over a period of 12 years in their institution. They observed that conservative treatment was effective in majority of patients, 39 patients required more aggressive therapy. Thirty five patients underwent insertion of double J catheter, 2 patients had per-cutaneous nephrostomy, and another 2 patients underwent ureteroscopy and extraction of ureteric calculi. Verdelo Pedro et al. [16] made the following conclusions:

- The most common aetiology of symptomatic hydronephrosis during pregnancy was external compression by the gravid uterus which was followed by uretero-lithiasis.
- They considered conservative treatment as the treatment of choice, leaving ureteric double J catheter (stent) insertion or percutaneous nephrostomy for the refractory cases.
- They would consider ureteroscopy as a new diagnostic and therapeutic option when other less aggressive measures fail.

Chelli et al. [17] reported a case of pyelo-ureteral malformation which had occurred on a single kidney. The malformation was diagnosed when the patient who was then 32 weeks pregnant had an ultrasound scan which revealed hydronephrosis. With regard to her initial treatment, she underwent ultrasound scan-guided drainage (Per-cutaneous nephrostomy). The woman gave birth to a live infant by means of normal vaginal delivery and she subsequently underwent resection of the pyelo-

ureteral malformation with anastomotic reconstruction of the upper urinary tract.

Kavoussi et al. [18] reported a total of 6 pregnant women who had calculi causing obstruction of the upper urinary tract which they had managed by means of ultrasound scan-guided nephrostomy insertion under local anaesthesia. Kavoussi et al. [18] stated that all the patients in the first instance had relief of acute obstruction. However, in 5 out of the 6 patients, occlusion of the per-cutaneous nephrostomy tubes with debris necessitated change of nephrostomy tubes. In 2 patients, as a result of recurrent nephrostomy tube obstruction, fever and pain percutaneous stone removal during pregnancy had to be undertaken. With regard to the remaining 4 patients, the nephrostomy tubes were left in situ during the pregnancy through delivery. During the post-partum period 3 of the patients underwent successful ureteroscopic stone extraction and one patient did pass the stone spontaneously. Each of the patients developed bacteraemia despite having had preventive antibiotics. All of the 6 patients had uncomplicated vaginal deliveries of healthy new-born babies and they were asymptomatic with no evidence of obstruction. Kavoussi et al. [18] concluded that percutaneous drainage of an acutely obstructed kidney in a pregnant woman is an effective temporary alternative to ureteric stent insertion until definitive treatment can be undertaken.

Semins and Matlaga [19] iterated that urolithiasis during pregnancy is a serious problem which is not common and that the options of the treatment of pregnant women with obstructing calculi include (a) ureteric stent insertion, (b) insertion of per-cutaneous nephrostomy, and (c) ureteroscopic stone removal. Semins and Matlaga [19] also stated that although ureteric stent insertion and insertion of percutaneous nephrostomy have been the historically standard treatment option for pregnant women with obstructing stones, emerging collection of literature exists which had reviewed the safety of ureteroscopic stone removal for pregnant women. Semins and Matlaga [19] undertook a systematic review of MEDLINE and EMBASE data base from January 1966 to April 2009 in order to identify all the literature on ureteroscopic stone removal in pregnant women. They reviewed the literature on ureteroscopic stone removal during pregnancy, with a focus on the safety of ureteroscopic stone removal. Based upon findings in their review of the literature, Semins and Matlaga [19] made the following conclusions:

- Ureteroscopic stone removal is an appropriate intervention in the pregnant population who are afflicted with urolithiasis.
- In all cases the procedure should be undertaken on a properly selected patient by a surgeon with appropriate experience and equipment.
- With such an approach, the complication rates tend to be low and the success rates tend to be high.
- A multi-Disciplinary Team approach should be emphasized as a key to a successful outcome of treatment.

Even though the long-term complications associated with nephrostomy insertion, was found to be low, it is worth noting that the complications of nephrostomy tube obstruction and non-drainage found only represent complications of obstruction / no-drainage seen in the hospital. It is highly likely that a number of patients had temporary non-drainage of their nephrostomy tubes which were successfully flushed by district nurses or perhaps the patients themselves (who were taught by the district nurses the technique of flushing of their nephrostomy tubes). It could therefore be argued that the percentage of patients who have had episodes of non-drainage of the nephrostomy tubes after they had been discharged is higher than the audit has shown and that a good way of obtaining the true rate of non-drainage of the nephrostomy tubes after discharge would should either by (a) getting all the patients to answer a postal questionnaire or (b) by undertaking a telephone survey.

It would be argued that there is no need for a patient undergoing insertion of percutaneous nephrostomy to be nil by mouth and that if a patient is not allowed anything to drink prior to the procedure this may lead to dehydration and in view of this patients awaiting nephrostomy should be allowed to drink to avoid dehydration. It could also be argued that there is no absolute need for all patients going for insertion of nephrostomy to have pre-procedure antibiotics and antibiotics should only be given to patients who have previously had instrumentations or who have clinical evidence of infection/sepsis. Percutaneous nephrostomy insertions can be undertaken positioning patients in other positions with good results and the positioning used as described in our unit is only one of them.

## Summary

- Nephrostomy is a safe procedure associated with high success rate which in our case was 100% successful.
- The complications associated with nephrostomies in our women were minimal; however, a number of patients do subsequently develop some nephrostomy related problems which clinicians, carers and patients should be aware of.
- There was no severe haemorrhage.
- Four cases of mild bleeding was encountered out of the 86 procedures (about 4.7% of cases), one case of nausea and vomiting (about 1.2% of the procedures) was observed during insertion of the 86 nephrostomies even though the patient had had pre-procedure antiemetic.
- Two episodes of non-drainage of nephrostomies were observed after the initial insertion of nephrostomies whilst on admission but flushing of the nephrostomies and nephrostogram showed no obstruction.
- One case of pyrexia / urinary tract infection (1.2% of cases) was successfully treated with antibiotics after the nephrostomy procedure during the initial admission.
- Seven cases (8.1% of the procedures) of non-drainage of nephrostomies were subsequently encountered after discharge of the patients and of these 3 (about 3.5% of cases) were truly obstructed and required insertion of new nephrostomies and the remaining were managed by successful flushing of the nephrostomies and rehydration + / - antibiotic treatment for any urinary tract infection.
- Five episodes of nephrostomy dislodgement or falling out occurred after the patients were discharged which required re-admission of the patients and successful insertion of new nephrostomy, one patient reported discomfort / pain at her nephrostomy site 10 days after the nephrostomy and after assessment which showed no evidence of infection she was given analgesia which took her pain away.
- Seven patients (9.9%) out of the 71 patients who had 86 procedures (8.1%) had antibiotic treatment for urinary tract infection alone or in association with blocked or dislodged or fallen out nephrostomy and these were mainly after their discharge from hospital after their procedures.
- There was no death related attributable to percutaneous nephrostomy insertion.
- Various non-obstetric/gynaecological as well as obstetric/gynaecological causes were responsible

for upper ureteric obstruction requiring insertion nephrostomies in our female patients.

- It could be said that a total 25 complications occurred during the procedures (5), after the procedures whilst in the ward before their discharge (3 patients had 4 complications), and after their discharge home (16). One patient at the start of the study had previously had blocked nephrostomy prior to the start of the study which was the indication for the PCN insertion and was not counted as a complication during the procedure. However, taking into consideration the fact that one patient had blocked nephrostomy six times which was flushed successfully each time and one patient had urinary tract infection thrice the overall total number of episodes of complications would be 32 (37.2%) after the 86 procedures.

### Conclusions and Recommendations

- Insertion of per-cutaneous nephrostomy in women can be carried out safely for a variety of causes of upper urinary tract obstruction.
- The complication rate following insertion of percutaneous nephrostomy in women in our experience is low.
- Nephrostomy insertion can be safely carried out in women of all ages including very old patients.
- Patients who have undergone nephrostomy insertion may subsequently after discharge develop nephrostomy related problems including blockage / non-drainage of nephrostomy tubes, urinary tract infection/urosepsis, dislodgement or accidental falling out of nephrostomy tube during change of nephrostomy bag or any other reason, nephrostomy tube related pain.
- A number of the non-draining/blocked nephrostomies can be safely and effectively managed by flushing of the nephrostomy tubes and hydration at home which would reduce readmissions for blocked nephrostomies.
- Every radiology department should have a trained radiologist who is capable of performing nephrostomy insertions and radiology departments which do not have interventional radiologists should endeavour to have some of their radiologists trained to undertake interventional radiological procedures, like insertion of per-cutaneous nephrostomies.

**Acknowledgements:** Authors would like to acknowledge the following:

- Mr Jason Howard PACS Manager of the Radiology Department of North Manchester General Hospital Manchester United Kingdom for obtaining a list of all the procedures of PCN insertions undertaken in the hospital in 2014.
- The Audit department of North Manchester General Hospital Manchester United Kingdom for registering the study.

**Conflict of interest:** None

### References

1. Goodwin W E, Casey W C, Woolf W. Percutaneous trocar (needle) nephrostomy in hydronephrosis, *JAMA* 1955; 157(11): 891 – 894 URL:<http://dx.doi.org/10.1001/jama.1955.02950280015005>
2. Chalmers N, Jones K, Drinkwater K, Uberol R, Towers J. The UK nephrostomy audit: Can a voluntary registry produce robust performance data *Clinical Radiology* 2008; 63: e888 – e894..
3. Gulmi F, Felson D, Vaughan E D. Pathophysiology of urinary tract obstruction,” *Campbell’s Urology: 8<sup>th</sup> edn.* Philadelphia P A Saunders 2002
4. Wah T M, Weston M J, Irving H C. Percutaneous nephrostomy insertion outcome data from prospective multi-operator study at a UK training centre *Clin Radiol* 2004 Mar; 59(3): 255 – 261. PMID: 15037138. <http://dx.doi.org/10.1016/j.crad.2003.10.021>
5. VanSonnenberg E, Casola G, Talner L B, Wittich G R, Varney R R, D’Agostino H B, Symptomatic renal obstruction or urosepsis during pregnancy: treatment by sonographically guided percutaneous nephrostomy *AJR Am J Roentgenol* 1992 Jan; 158(1):91 – 94. PMID: 1727366. <http://dx.doi.org/10.2214/ajr.158.1.1727366>
6. Siddiqi N H, Schwartz B F. Percutaneous Nephrostomy Technique - *Medscape Reference* 2014 Nov 11; [emedicine.medscape.com/article/1821504-technique](http://emedicine.medscape.com/article/1821504-technique) Accessed 2016 August 28
7. Shen C H, Cheng M C, Lin C T, Jou Y C, Chen P C. Innovative metal dilators for percutaneous nephrostomy tract: report of 546 cases. *Urology* 2007 Sep; 70(3): 418 – 421
8. Ozok H U, Sagnak L, Senturk A B, Karakoyunlu N, Topaloglu H, Ersoy H. A Comparison of Metal Telescopic Dilators and Amplatz Dilators for Nephrostomy Tract Dilatation in Percutaneous Nephrolithotomy *J Endourol* 2012 26(6): 630 - 634



Venyo AKG. (September 2016). Percutaneous nephrostomy in women: A retrospective review of an audit of procedures undertaken in one year with a review of the literature. *Jour of Med Sc & Tech*; 5(3); Page No: 34 – 50.

9. Williams S K, Bird V G, Maurici G, Leveillee R J. Borrowing from interventional radiology: novel technique to dilate scarred nephrostomy tract. *Urology* 2008 Nov; 72(5): 1156 – 1158
10. Pollard A J, Nicholson DA. Percutaneous nephrostomy: how to do it. *J. Intervent Radiol* 1994; 9: 129 -141
11. Lewis S I, Patel U. Major complications after percutaneous nephrostomy-lessons from a department audit. *Clin Radiol* 2004 Feb; 59(2): 171 – 179. [http://dx.doi.org/10.1016/S0009-9260\(03\)00336-2](http://dx.doi.org/10.1016/S0009-9260(03)00336-2)
12. Venyo A K G, Fatola C O, Khan A N. Percutaneous Nephrostomy in Women: An Audit of more than 300 procedures: *Journal of Biomedical Graphics and Computing* 2014; 4(4): ISSN 1925-4008 (Print) ISSN 1925-4016 DOI: 10.5430/jbgc.v4n4p31 [www.sciedupress.com/journal/index.php/jbgc/article/view/4995](http://www.sciedupress.com/journal/index.php/jbgc/article/view/4995)
13. Venyo A K G, Fatola C O, Adegbite D, Khan A N. Nephrostomy in pregnancy a district general hospital experience over five years. *Journal of Biomedical Graphics and Computing* 2015; 5(1): ISSN 1925-4008 (print) ISSN 1925-4016 (online) DOI: 10.5430/jbgc.v5n1p1 [www.sciedupress.com/journal/index.php/jbgc/article/view/5008](http://www.sciedupress.com/journal/index.php/jbgc/article/view/5008)
14. Negru I, Pricop C, Costăchnescu G H. Renal colic in pregnancy *Revisita medico-chirurgicală* 2010 Apr – Jun; 114(2): 439 – 444.
15. Dorochuk D N, Trpeznikova M F, Dutov V V. Quality of life in patients with urolithiasis depending on methods of drainage of the upper urinary tract. *Urologliza Moscow, Russia*. 2010 Mar – Apr; 1999(2): 14 – 17.
16. Navalon Verdejo P, Sanchez Ballester F, Pallas Costa Y, Cánovas Ivorra J A, Ordono Dominoquez F, Juan Escudero J, *et al*, Symptomatic hydronephrosis during pregnancy. *Archivos Españoles de urologia* 2005 Dec; 58(10): 977 – 982.
17. Chelli H, Mazlout N, Abed A, Mazouki M M, Fadhlouli A, Hendaoui L, *et al*, Drainage by echo-guided nephrostomy in hydronephrosis secondary to a pyelo-ureteral junction in a single kidney syndrome in a pregnant woman: A propos of a case. *Journal d'urologie* 1996; 102(5-6): 240 – 247.
18. Kavoussi L R, Aibala D M, Basler J W, Apte S, Clayman R V. Percutaneous management of urolithiasis during pregnancy. *The Journal of Urology* 1992 Sep; 148(3 pt. 2): 1069 – 1071. PMID: 1507334.
19. Semins M J, Matlaga B R. Ureterscopy during pregnancy *Indian Journal of Urology* 2009 Jul; 25(3): 291 – 295. PMID: 19881118. <http://dx.doi.org/10.4103/0970-1591.56173>