

Full Length Research Paper

The In Vivo Protective Effects of Soybeans on DMN-Induced Hepatotoxicity in Rats

Gihan Hosny^{1*}, Samah Mohamed¹ and Hanan Tayel²

¹Division of Environmental Health, Department of Environmental Studies, Institute of Graduate Studies and Research, University of Alexandria, P.O.Box 832, Alexandria, Egypt.

²Department of Pathology, Faculty of Medicine, University of Alexandria, Alexandria, Egypt.

Abstract

Dimethyl nitrosamine (DMN) is a very potent chemical carcinogen which occurs naturally in the environment and in a wide variety of food stuffs, and can be formed in the body by nitrosation of secondary or tertiary amines in the presence of nitrite, nitrate or nitrogen oxides. Soybeans is a powerful antioxidant and has a potent free radical scavenging activity, said to protect cells of breast, liver, brain and other cells in the body from toxins. The objective of this study is to examine the *in vivo* protective effects of soybeans on the induced oxidative damage in livers of DMN-intoxicated rats histologically and immunohistochemically. The ability of soybeans to protect and detoxify DMN toxicity was examined in rat livers. Dietary pretreatment of rats (body weight 125-135 g) with soybeans for two weeks prior to the intraperitoneal injection of DMN, reversed the hepatotoxic effects of DMN, as examined histologically. DMN in two doses of 15 or 25g/kg were injected. After DMN treatment, the animals were fed with diet with soybeans or without for 72 hours. Rats were sacrificed 72 hours after DMN injection. The immunoreactivity of cells of rats' livers was examined for antibodies of heat shock protein 70 (HSP70) (HSPs are a family of proteins that are triggered to be induced when a cell undergoes environmental stresses including oxidative stress, pathogenic conditions...etc). The histological evaluation revealed prominent changes in groups received DMN in high dose more than low dose. Treatment with soybeans reversed this effect. The immunohistochemical assay for the stress-protective proteins "HSP70" showed that treatment with soybeans triggered more expression of this protein. Soybeans can provide substantial protective effect against DMN-induced hepatic oxidative damage with favorable potential to be enhanced in use in human diet.

Keywords: DMN, Soybeans, Antioxidant activity, Immunohistochemistry.

INTRODUCTION

Chemical carcinogens now comprise a very diverse group of non-viral and nonradioactive compounds that may have organic or inorganic structures with various species and tissue selectivity (Higginson, 1993). In addition to the chemicals generally recognized as carcinogens as a result of industrial, medical, and social exposures, a number of other chemicals in the environment such as; mycotoxins and certain *N*-nitroso compounds (NOCs) are strongly suspected of causing

cancers in humans (Miller, 1978). NOCs form a large group of very potent chemical carcinogens which occur naturally in the environment and can be formed in the body by nitrosation of secondary or tertiary amines in the presence of nitrite, nitrate or nitrogen oxides. Thus, human exposure to carcinogenic NOCs may be exogenous or endogenous and can occur via several routes and certain occupations and life styles can lead to increased exposures (Magee, 1989; International Agency for Research on Cancer, 1978; Huber *et al.*, 2013). Dimethyl nitrosamine (DMN) is one member of the carcinogenic NOCs that was the first compound to be discovered from this group, as an animal carcinogen, in 1956 by Magee and Barnes (Magee, 1956). It has

*Correspondence Author Email: Gihan_hosny@yahoo.com;
Tel: (+203) 4295007 Fax: (+203)4285792.

been reported that foods collected from areas with a high incidence of oesophageal cancer in India and nasopharyngeal carcinoma in Tunisia, south China, and Greenland, contained higher levels of NOCs than expected (Siddiqi *et al.*, 1988, Poirier *et al.*, 1987). It can be concluded that it is well known and not new to have DMN as a natural contaminant in our food and environment and also can be easily formed endogenously from the components of the intake food stuffs (Huber *et al.* 2013).

Soy products have recently been increased popularity, as they are uniquely rich sources of isoflavones, antioxidant and one type of phytoestrogen. Isoflavones exhibit estrogen-like effects under certain experimental conditions and are posited to reduce risk of coronary heart disease (Messina and Lane, 2007), osteoporosis (Ma *et al.*, 2008), certain forms of cancer (Wu *et al.*, 2008), and to alleviate menopause-related hot flashes (Howes *et al.*, 2006). Epidemiological studies have found that soy protein may reduce the risk for cancers including breast, colon, and prostate (Badger *et al.*, 2005). In the current study, we have examined the histological and immunohistochemical *in vivo* protective effect of soybeans on DMN-induced oxidative damage in rat livers in order to evaluate its intracellular protective effects.

Data collection

All reagents were of highest quality available. DMN (purity \approx 98%) was purchased from Sigma Chemical Co. Soy milk of high quality product was obtained from local market.

Adult male rats having body weight of 125-135 g were obtained from animal house of Faculty of Medicine, University of Alexandria.

METHODS

Rats were acclimated for one week under lightening of 14 hr light/10 hr dark. The mixture of soy milk, was administered in food and water to rats for two weeks. DMN was dissolved in 1% absolute ethanol in saline and administered intraperitoneally (IP) in two different doses 15 g/kg (LD) and 25 g/kg (HD) (Phillips *et al.*, 1977).

Animal treatment

After one week of acclimation, the animals were divided into 6 groups of 5 animals each. Treatment with soy milk was started two weeks before sacrifice in group 2, 5 and 6. Each group received IP injections of DMN at 48 hours before sacrifice:

Group (1) Control group (C gp)

Group (2) Soybeans group (S gp)

Group (3) Low dose DMN treated group (LD gp)

Group (4) High dose DMN treated group (HD gp)

Group (5) Soybeans and low dose DMN treated group (LD + S gp)

Group (6) Soybeans and high dose DMN treated group (HD + S gp)

Group 1 and 2 received IP injections of saline. LD of DMN was injected in groups 3 and 5, and HD of DMN in groups 4 and 6. After DMN treatment, the animals received food and water with soybeans or without depending on the group type for 72 hours. Groups 1, 3 and 4 were fed without soybeans while groups 2, 5 and 6 received soybeans in order to keep constantly high soybeans levels following DMN administration. All rats were sacrificed 72 hours after DMN treatment began.

Tissue preparation

Soon after decapitation, the animal's abdomen was opened. Livers were removed and cooled on dry ice. Fresh specimens were taken from liver of all studied rats. Each specimen was fixed in 10% formal saline and processed to get 6 μ m thick paraffin sections, which were stained with H & E stain to study the structure and architecture and immunohistochemistry.

Histological examination: Samples from livers of each group were fixed in buffered formalin, processed for Haematoxylin and Eosin (H & E) stain and examined microscopically (Drury and Wallington, 1980).

Immunohistochemical examination: Samples from rat livers were examined for immunohistochemical reactivity for the stress protein HSP70 (Heat Shock Protein). Immunohistochemical staining of the formalin-fixed, paraffin-embedded tissue sections was carried out as previously described (Lee *et al.*, 1992), using ultravision Avidin-Biotin detection system. A rabbit anti-rat HSP70 ready-to-use polyclonal antibody (Neomarkers Lab Vision, USA) were used for immunodetection of HSP70 in rat livers. The tissue sections (5 micron thick) were placed on silanized glass slides and processed for immunostaining using xylene, alcohol and boiled in 10 mM citrate buffer, pH 6.0, for 10 min followed by cooling at room temperature for 20 min. All tissue sections were placed in a humidified chamber with 3% hydrogen peroxide for 20 minutes. The antibody was applied to sections in phosphate buffer, pH 7, with overnight incubation at 4°C in a humid chamber. Slides were then incubated with a biotinylated immunoglobulin (linking reagent) for 20 minutes, and an Avidin-Biotin complex (Streptavidin peroxidase labelling reagent) for another 20 minutes. Tissue sections were washed between incubations with phosphate buffered saline solution. The brown staining color reaction was developed using DAB (3-3'-diaminobenzidine). The cellular localization was nuclear and/or cytoplasmic for HSP70. Negative and positive control sections, obtained from breast carcinoma, were included in each run. The

tissue slides were finally dehydrated, counterstained and mounted. The overall intensity of staining was scored semi-quantitatively. Staining patterns were discriminated as nuclear (N), cytoplasmic (C) or both. Cases were examined by two observers.

RESULTS AND DISCUSSION

Histological examination

Control group

Normal control rat liver showed normal hepatic architecture with hepatocytes radiating from the central veins. The hepatocytes were polyhedral with large central vesicular nuclei and acidophilic cytoplasm. The hepatic sinusoids appeared in between the hepatic cords as narrow spaces lined by flattened endothelial cells and few Kupffer cells (Figure 1).

Soybeans group: The livers of rat received soybeans showed no deviation from the normal structure of hepatic lobules (Figure 2).

LD DMN group: Animals of this group showed diffuse affection of liver tissue. Most hepatocytes appeared vacuolated with pale cytoplasm and well preserved nuclei. Some central veins showed marked congestion as well as many hepatic sinusoids (Figure 3).

LD DMN + S group: Livers of rats of this group showed preservation of normal hepatocytes architecture. However, few focal areas appeared with vacuolated pale hepatocytes (Figure 4).

HD DMN group: Histological examination of livers of rats of this group revealed severe degenerative changes of hepatic tissues with evident loss of hepatic architecture. Hepatocytes affection ranged from ballooning with cytoplasmic vacuolation and peripherally pushed nuclei up to necrosis with dark shrunken nuclei (Figure 5).

HD DMN + S group: Rat livers of this group showed marked protective effect of soybeans. Most of hepatic lobules appeared nearly normal. Some focal areas showed remaining affection with damaged ballooned hepatocytes (Figure 6).

Immunohistochemical examination

All rats' livers of the control groups treated with or without soybeans showed negative staining for HSP70 in both cytoplasm and nuclei of hepatocytes (Figure 7). Livers of rats received low dose of DMN showed weak positive granular brownish cytoplasmic staining in most hepatocytes (Figure 8). This reaction was enhanced in rats received low dose of DMN with soybeans (Figure 8). While livers of rats received high dose of DMN showed marked cytoplasmic immuno-positivity for HSP70 especially in the ballooned hepatocytes (Figure 8). The

administration of soybeans with high dose of DMN resulted in positive granular brownish immune reaction in both cytoplasm and nuclei of all hepatocytes (Figure 8). The results showed that soybeans confer protection against DMN-induced liver oxidative damage. The histological and immunohistochemical examination revealed prominent changes in groups received DMN in high dose more than low dose. Treatment with soybeans reversed this effect and provided substantial protection against the hepatotoxicity of DMN. Soybeans is an antioxidant or free radical scavenger, as it contains isoflavones, that can provide protection to cells and tissues by promoting the growth of new cells (Wu *et al.*, 2008, Badger *et al.*, 2005; Chi *et al.*, 2013). It exerts a protective effect against substances potentially harmful to the body. Soy foods are good sources of protein, and many are also good sources of fiber, potassium, magnesium, copper, iron, calcium and manganese. Soy is also a good source of polyunsaturated fat, both the omega-6 (linoleic acid) and omega-3 (alpha-linolenic) types (World Cancer Research Fund, 2007). The protective action of soybeans is explicable in terms of its containing of a variety of phytochemicals and active compounds: Isoflavones: a group of phytoestrogens that includes genistein, daidzein and glycitein; Saponins: studies suggest these compounds may lower blood cholesterol, protect against cancer and affect blood glucose levels; Phenolic Acids: this group of phytochemicals is being studied for their potential as antioxidant and to stop cancer cells from spreading; Phytic Acid: commonly found in cereals and legumes, it can act as an antioxidant; Enzyme-regulating proteins: these include protease inhibitors and protein kinase inhibitors; and Sphingolipids: they seem to play a role in regulating cell growth, self-destruction of abnormal cells and progression of tumors (World Cancer Research Fund, 2007; Shike *et al.*, 2014).

In the current study, soybeans provide protective effect to liver cells which can be explained as; Being a potent antioxidant, soybeans can inhibit lipid peroxide formation in the liver cells; and possesses anti-inflammatory properties mediated by alteration of hepatic Kupffer cell function (Dehmlow *et al.*, 1996). DMN is a hepatotoxic and genotoxic agent that can produce centrilobular necrosis of fairly rapid onset with morphological and hematological events (Ellinger-Ziegelbauer *et al.*, 2004). DMN is known to induce both necrotic and apoptotic cell death and is considered as a model of persistent liver fibrosis (Magee, 1989). Lipid peroxidation is believed to play a key role in the membrane-mediated oxidative damage. However, DNA damage has been suggested to contribute to DMN-induced necrosis (Ellinger-Ziegelbauer *et al.*, 2004). The histological appearance of livers of rats injected IP with DMN (0.3 ml/100 g body weight of 0.1% DMN in 0.9% saline) after 20 hours, revealed spotty foci showing mild hemorrhage with sinusoidal dilation and by 25 to 30 hours, expanded damaged foci of hepatocytes with

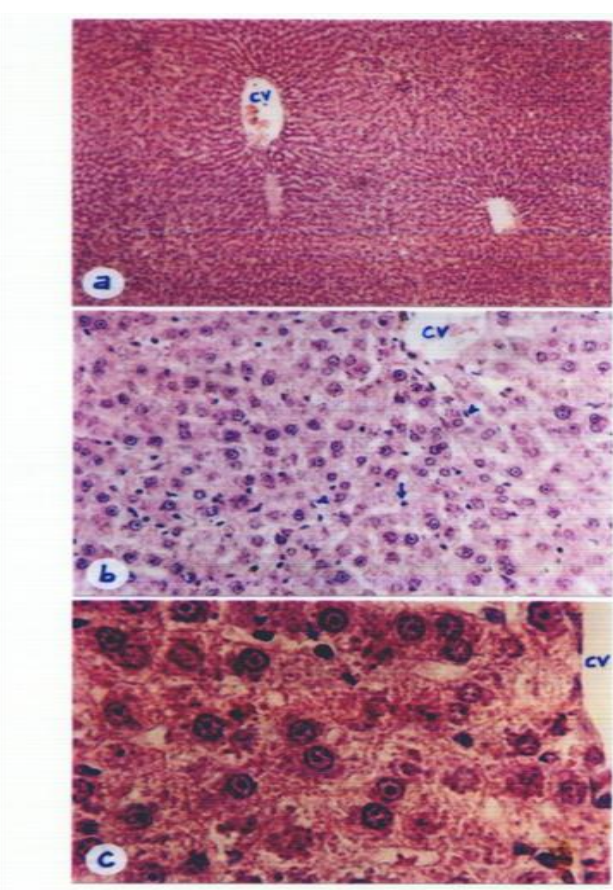


Figure 1. Photomicrographs of rat's liver of control group showing cords of polyhedral hepatocytes with central vesicular nuclei, radiating from central veins, (CV). Narrow sinusoids are seen lined by endothelial cells (arrow head) and Kupffer cells (arrow). (H & E stain: ax100; bx400; cx1000).

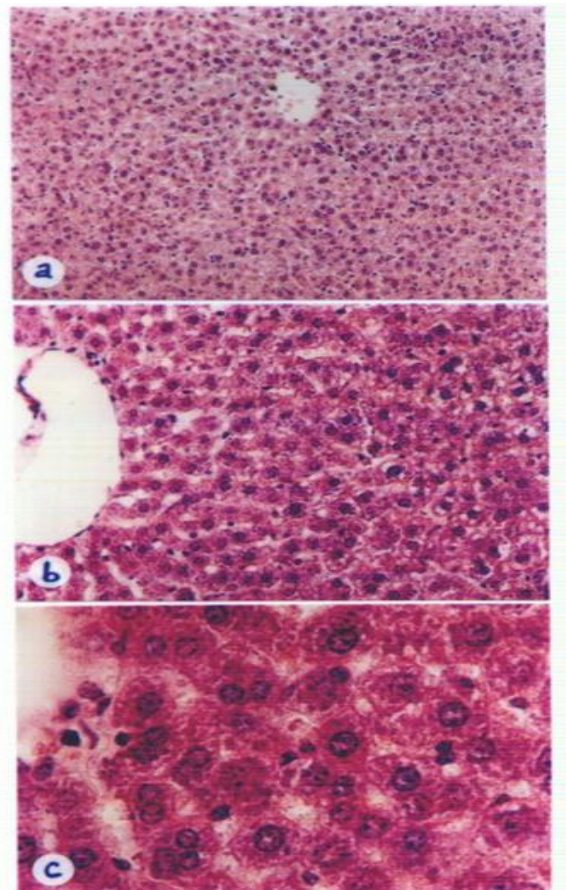


Figure 2. Photomicrographs of rat's liver of soybeans group showing no change in the normal structure of hepatocytes and sinusoids in between. (H & E stain: ax200; bx400; cx1000).

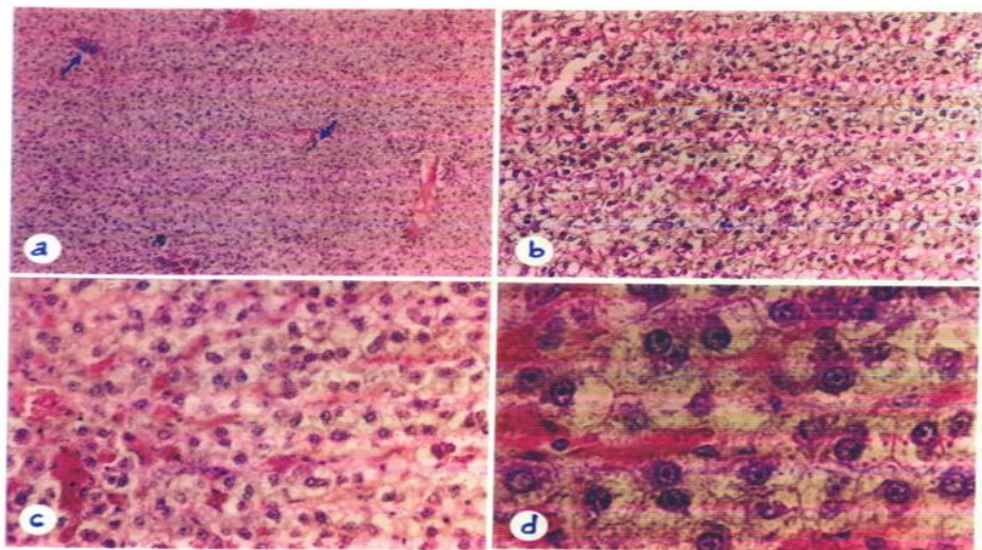


Figure 3. Photomicrographs of rat's liver of low dose DMN group showing diffuse vacuolation of hepatocytes, congestion of central veins as well as some sinusoids. Scattered enlarged hepatocytes with small dark eccentric nuclei are occasionally encountered. Note the cellular infiltration (arrow). (H & E stain: ax100; bx200; cx400; dx1000).

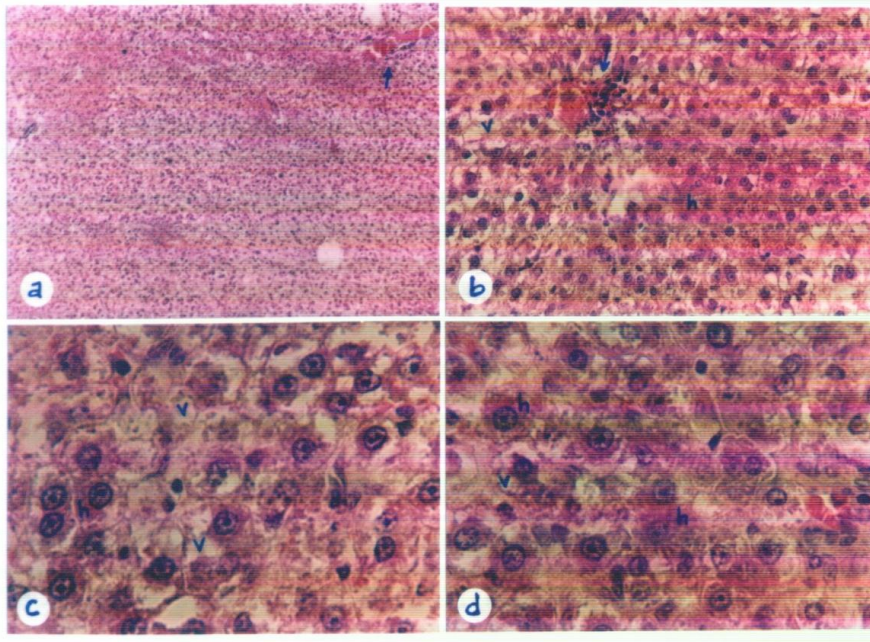


Figure 4. Photomicrographs of rat's liver of low dose DMN + soybeans group showing few focal areas of vacuolated hepatocytes (v) beside areas of apparently normal hepatocytes (h). Note few hepatic vessels depict congestion with cellular infiltration around (arrow). (H & E stain: ax100; bx400; c & dx1000).

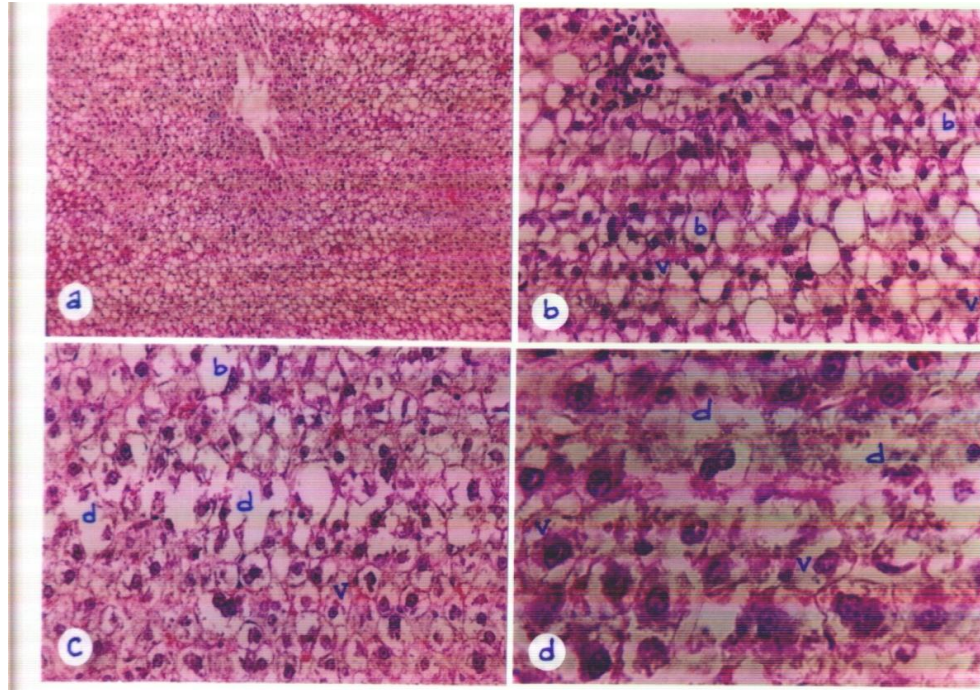


Figure 5. Photomicrographs of rat's liver of high dose DMN group showing diffuse affection of hepatocytes, many are ballooned (b), or vacuolated (v) and others are severely degenerated (d) depicting nuclear remnants or even completely lysed. (H & E stain: ax100; b & cx400; dx1000).

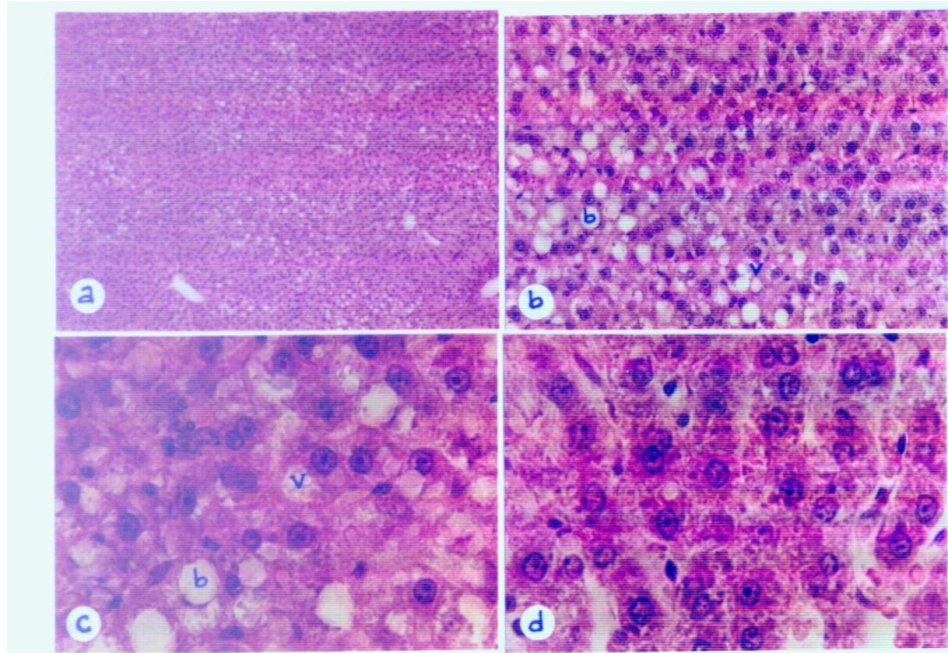


Figure 6. Photomicrographs of rat's liver of high dose DMN + soybeans group showing limited areas of affection in the form of ballooned (b) or vacuolated (v) hepatocytes. The rest of cells appear more or less normal. (H & E stain: ax100; bx400; c & dx1000).

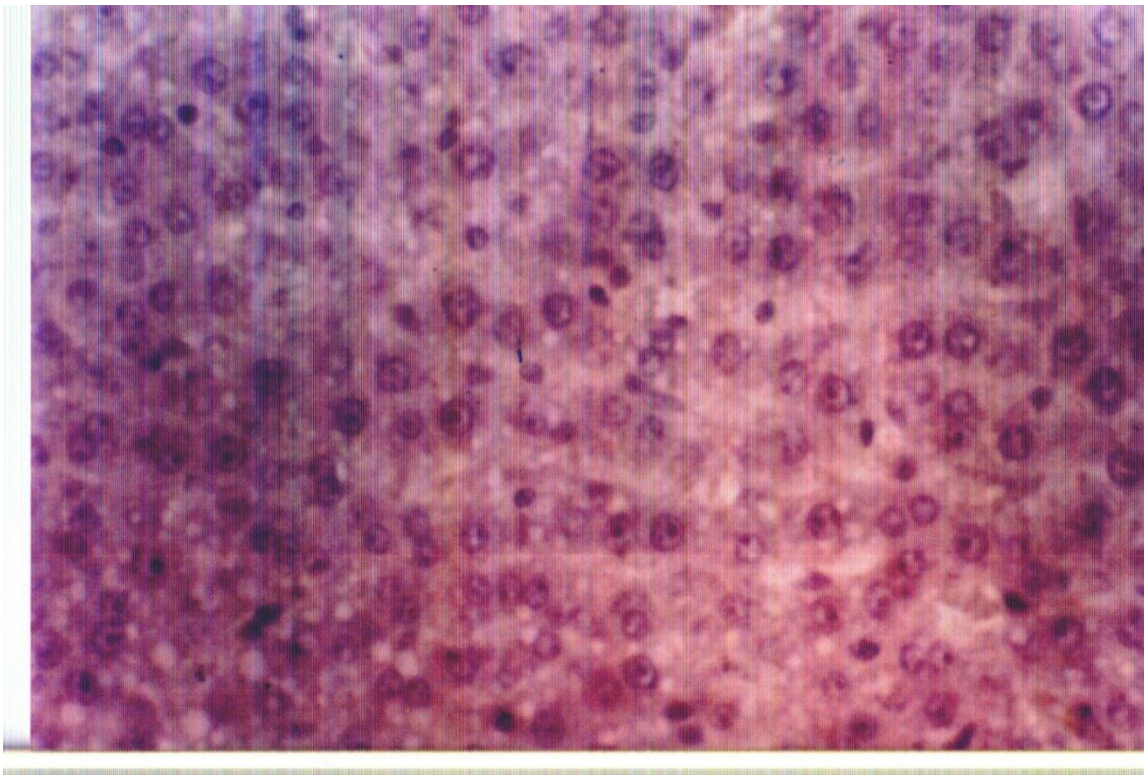


Figure 7. HSP70 immunohistochemical staining of rats' livers in control groups with or without silymarin (HSP70 x400). Control groups showing no apparent immunostaining reaction neither in the cytoplasm nor in the nuclei.

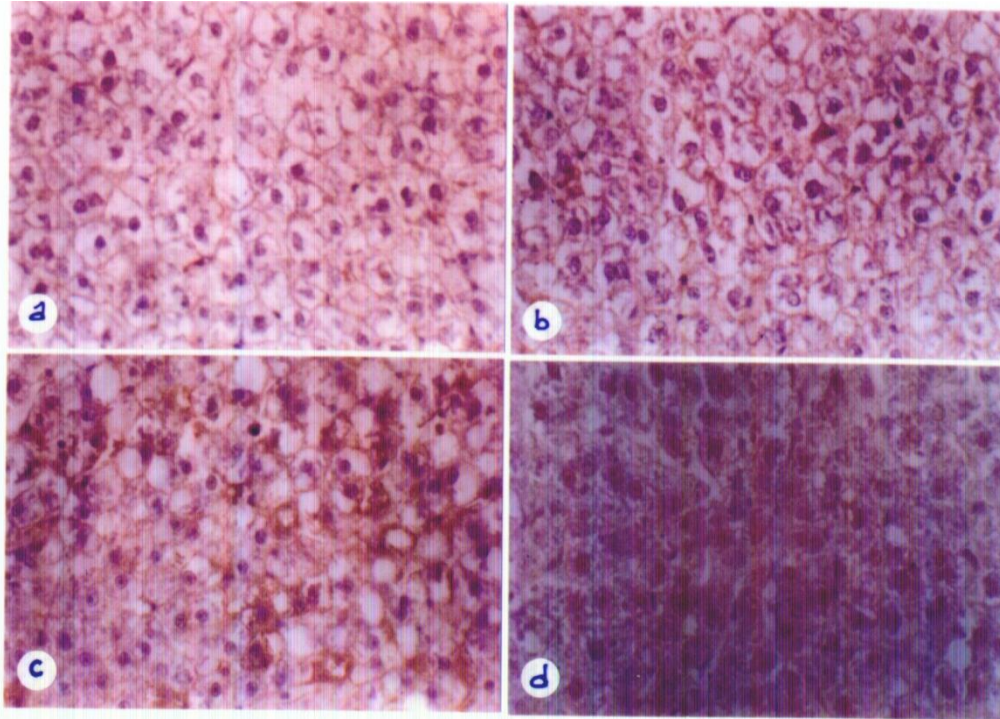


Figure 8. HSP70 immunohistochemical staining of rats' livers in different groups (HSP70 x400). (a) LD DMN group showing apparent weak positive granular brownish reaction in the cytoplasm of most hepatocytes. (b) LD DMN + S group showing evident increased immune reaction in the cytoplasm of hepatocytes. (c) HD DMN group showing marked increased granular brownish staining in the ballooned hepatocytes in comparison to the rest of hepatocytes. (d) HD DMN + S group showing evident positive granular brownish staining in both cytoplasm and nuclei of all hepatocytes.

distinct hemorrhage were reported (Yasuda *et al.*, 2000). These foci involved not only the centrilobular zone but also occasionally the intermediate zone, accompanied by mild to moderate inflammatory cell infiltration. Damaged hepatocytes developed ballooning and the nuclei were shrunken and condensed with no apparent apoptotic features. Centrilobular necrosis in rat liver was also reported with a dose level of DMN up to 25 g/kg and early histochemical changes indicative of liver injury were observed at a dose level of 15 g/kg (Yasuda *et al.*, 2000). In the current study, IP injection of rats with low dose of DMN (15 g/kg) showed diffuse affection of liver tissue, most of hepatocytes appeared vacuolated with pale cytoplasm and well preserved nuclei. Early inflammatory signs in the form of marked congestion of the central veins as well as many hepatic sinusoids were also observed, as previously reported. In contrast, injection with high dose of DMN (25 g/kg) resulted in severe degenerative changes of hepatic tissues with evident loss of hepatic architecture. The affection of hepatocytes ranged from ballooning with cytoplasmic vacuolation and peripherally pushed nuclei up to necrosis with dark shrunken nuclei; the results coincide with the previously reported results (Yasuda *et al.*,

2000). However, the administration of soybeans to animals was able to reverse such conditions probably due to its capacity for trapping free radicals, stabilizing the cytoplasmic membranes and its anti-inflammatory properties.

Heat shock proteins (HSPs), also called stress-response proteins, are a family of proteins that appear to exist in all cells in all life forms, with a presumably protective function. They are triggered to be induced when a cell undergoes environmental stresses including heat shock, oxidative stress, heavy metals, or pathogenic conditions, such as ischemia and reperfusion, inflammation, tissue damage, infection and mutant proteins associated with genetic diseases (Jolly and Morimoto, 2000). They are also present in cells under normal conditions, acting as chaperones or proteases to ensure that cells' proteins are in the right shape and in the right place at the right time, thus, help proper folding of proteins, transport them within the cell, and escort old ones to be broken down (Jolly and Morimoto, 2000). Consequently, HSPs assist in the recovery from stress either by repairing damaged proteins (protein refolding) or by degrading them, thus restoring protein homeostasis and promoting cell

survival. The inducible expression of HSPs (HSP27, HSP70, HSP60, HSP90 α , HSP90 β) under environmental and pathophysiological stressful conditions is thought to be involved in protein-protein interactions including those of the protein products of the human c-myc oncogene and the p53 tumor suppressor gene (Morimoto, 1993). In the present study, the immunohistochemical assay for the reactivity toward HSP70 polyclonal antibodies revealed weak positive granular brownish cytoplasmic immune reaction in livers of rats received low dose of DMN, which was enhanced in the group of rats received low dose of DMN and soybeans. Livers of rats received high dose of DMN showed marked cytoplasmic expression of HSP70 especially in the ballooned hepatocytes, probably due to increased stress on the liver cells. This reaction was further enhanced with the administration of soybeans and extended to involve positive immunoreactivity for HSP70 in both the cytoplasm and nuclei of all hepatocytes. The results of the immunohistochemistry further emphasize the hepatoprotective role provided by the administration of soybeans in DMN-intoxicated rats.

CONCLUSION

The current results suggest that administration of soybeans in food can provide *in vivo* protection against hepatic damage-induced by DMN and focus on the protective effects for favorable potential to be enhanced in use in human diet.

REFERENCES

- Badger TM, Ronis MJ, Simmen RC, Simmen FA (2005). Soy protein isolate and protection against cancer. *J Am Coll Nutr.* 24: 146-149.
- Chi F, Wu R, Zeng YC, Xing R, Liu Y, Xu ZG (2013). Post-diagnosis soy food intake and breast cancer survival: A meta analysis of cohort studies. *Asian Pac J Cancer Prev.* 14(4): 2407-2412.
- Dehmlow C, Erhard J, de Groot H (1996). Inhibition of Kupffer cell function as an explanation for the hepatoprotective properties of silibinin. *Hepatology.* 23: 749-754.
- Drury RAB, Wallington EA (1980). *Carlton's Histological Techniques.* Oxford University Press, Oxford, New York, Toronto, 5thed, P.139-142.
- Ellinger-Ziegelbauer H, Stuart B, Wahle B, Bomann W, Ahr H-J (2004). Characteristic expression profiles induced by genotoxic carcinogens in rat liver. *Toxicol Sci.* 77: 19-34.
- Higginson J (1993). Environmental carcinogenesis. *Cancer.* 72: 971-977.
- Howes LG, Howes JB, Knight DC (2006). Isoflavone therapy for menopausal flushes: a systematic review and meta-analysis. *Maturitas.* 55(3): 203-211.
- Huber J, Brender JD, Zheng Q, Sharkey JR, Vuong AM, Shinde MU, Griesenbeck JS, Suarez L, Langlois PH, Canfield MA, Romitti PA, Weyer PJ (2013). Maternal dietary intake of nitrates, nitrites and nitrosamines and selected birth defects in offspring: a case-control study. *Nutrition Journal* 12: 34-44.
- International Agency for Research on Cancer (1978). Monographs on the Evaluation of the carcinogens. Risk of chemicals to humans: Some N-nitroso compounds. Lyon: IARC, Vol 17.
- Jolly C, Morimoto RI (2000). Role of the heat shock response and molecular chaperones in oncogenesis and cell death: a review. *JNCI (J Natl Cancer Instit).* 92(19): 1564-1572.
- Lee SM, Rafferty JA, Elder RH, Fan C-Y, Bramley M, Harris M, Thatcher N, Potter PM, Altermatt HJ, Perinat-Frey T, Cerny T, O'Connor PJ, Margison GP (1992). Immunohistological examination of the inter and intracellular distribution of O⁶-alkylguanine DNA-alkyltransferase in human liver and melanoma. *Br. J. Cancer* 66: 355-360.
- Ma DF, Qin LQ, Wang PY, Katoh R (2008). Soy isoflavone intake increases bone mineral density in the spine of menopausal women: Meta-analysis of randomized controlled trials. *Clin Nutr.* 27(1): 57-64.
- Magee PN (1989). The experimental basis for the role of nitroso compounds in human cancer. *Cancer Surv.* 8(2): 207-239.
- Magee PN, Barnes JM (1956). The production of malignant primary hepatic tumors in the rat by feeding dimethyl-nitrosamine. *Br. J. Cancer* 10: 114-122.
- Messina M, Lane B (2007). *Soy protein, soybean isoflavones, and coronary heart disease risk: Where do we stand?* *Future Lipidology* 2: 55-74.
- Miller EC (1978). Some current perspectives on chemical carcinogenesis in humans and experimental animals. *Cancer Res.* 38: 1479-1496.
- Morimoto RI (1993). Cells in stress: transcriptional activation of heat shock genes. *Science* 259: 1409-1412.
- Phillips JC, Lake BG, Gangolli SD, Grasso P, Lloyd AG (1977). Effects of pyrazole and 3-amino-1,2,4-triazole on the metabolism and toxicity of dimethylnitrosamine in the rat. *J Natl Cancer Inst.* 58(3): 629-633.
- Poirier S, Ohshima H, De-The G, Hubert A, Bourgade MC, Bartsch H (1987). Volatile nitrosamine levels in common foods from Tunisia, South China and Greenland, high-risk areas for nasopharyngeal carcinoma (NPC). *Int. J. Cancer* 39: 293-296.
- Shike M, Doane AS, Russo L, Cabal R, Reis-Filo J, Gerald W, Cody H, Khanin R, Bromberg J, Norton L (2014). The Effects of Soy Supplementation on Gene Expression in Breast Cancer: A Randomized Placebo-Controlled Study. *J. National Cancer Institute, JNCI,* 106(9): 189-197.
- Siddiqi M, Tricker AR, Preussmann RC (1988). The occurrence of preformed N-nitroso compounds in food samples from a high-risk area of oesophageal cancer; Kashmir, India. *Cancer Lett.* 39: 37-43.
- World Cancer Research Fund / American Institute for Cancer Research (2007). *Foods That Fight Cancer, Food, Nutrition, Physical Activity and the Prevention of Cancer: a Global Perspective,* Washington, DC. Pp 82-113.
- Wu AH, Yu MC, Tseng C-C, Pike MC (2008). Epidemiology of soy exposures and cancer risk. *Br. J. Cancer.* 98(1): 9-14.
- Yasuda M, Okabe T, Itoh J, Takekoshi S, Hasegawa H, Nagata H, Osamura RY, Watanabe K (2000). Differentiation of necrotic cell death with or without lysosomal activation: application of acute liver injury models induced by carbon tetrachloride (CCl₄) and dimethylnitrosamine (DMN). *J. Histochem Cytochem.* 48: 1331-1340.

How to cite this article: Hosny G, Mohamed S, Tayel H (2015). The *in vivo* protective effects of soybeans on DMN-induced hepatotoxicity in rats. *Int. J. Environ. Sci. Toxic. Res.* Vol. 3(9):165-172