

Root Resection : Salvage to Hopeless

Dr. Mohd Rehan¹, Dr. Manish Khatri², Dr. Nisha Parveen³

Senior Lecturer¹, Professor & HOD², PG Student³, Department of Periodontology, Institute of Dental Studies & Technologies, Modinagar, Ghaziabad

Abstract

Advances in dentistry, as well as the increased desire of patients to maintain their dentition have led to treatment of teeth that once would have been removed. Root resection denotes removal or separation of root crown portion of mandibular molars. It is a suitable treatment option when the decay is restricted to one root and the other root is healthy. It is a conservative procedure to save the original tooth structure, which can act as abutment for fixed restorations. The results of this procedure are predictable and success rates are high. In this paper a case is presented in which root resection was done because the mesial root was carious. Mesial half of tooth was extracted and the remaining tooth was used as an abutment for fixed partial denture.

Keywords: Root resection, Amputation, Hemisection.

Introduction

Modern advances in all phases of dentistry have provided the opportunity for patients to maintain a functional dentition for lifetime. Therapeutic measures performed to ensure retention of teeth vary in complexity. The treatment may involve combining restorative dentistry, endodontic and periodontics so that the teeth are retained in whole or in part.¹ Such teeth can be useful as independent units of mastication or as abutments in simple fixed bridges.² Continued periodontal breakdown may lead to total loss of tooth unless these defects can be repaired or eliminated and health of the tissues restored. Thus tooth resection procedures are used to preserve as much tooth structure as possible rather than sacrificing the whole tooth.³

The term tooth resection denotes the excision and removal of any segment of the tooth or a root with or without its accompanying crown portion. Various resection procedures described are root amputation, hemisection, radisection and bisection. Root amputation refers to removal of one or more roots of multirooted tooth while other roots are retained.

Hemisection denotes removal or separation of root with its accompanying crown portion of mandibular molars.

Radisection is a newer terminology for removal of roots of maxillary molars. Bisection/bicuspidization is the separation of mesial and distal roots of mandibular molars along with its crown portion, where both segments are then retained individually.⁴ Weine has listed the following indications for tooth resection

Periodontal Indications

1. Severe vertical bone loss involving only one root of multi-rooted teeth.
2. Through and through furcation destruction.
3. Unfavorable proximity of roots of adjacent teeth, preventing adequate hygiene maintenance in proximal areas.
4. Severe root exposure due to dehiscence.⁴

Endodontic & Restorative Indications

1. Prosthetic failure of abutments within a splint: If a single or multirooted tooth is periodontally involved within a fixed bridge, instead of removing the entire

bridge, if the remaining abutment support is sufficient, the root of the involved tooth is extracted.

2. Endodontic failure: Hemisection is useful in cases in which there is perforation through the floor of the pulp chamber, or pulp canal of one of the roots of an endodontically involved tooth which cannot be instrumented.
3. Vertical fracture of one root: The prognosis of vertical fracture is hopeless. If vertical fracture traverses one root while the other roots are unaffected, the offending root may be amputated.
4. Severe destructive process: This may occur as a result of furcation or sub. gingival caries, traumatic injury, and large root perforation during endodontic therapy.⁴

Contra - Indications

1. Strong adjacent teeth available for bridge abutments as alternatives to hemisection.
2. Inoperable canals in root to be retained.
3. Root fusion-making separation impossible.⁴

Case Report

A 38 year old male patient reported to the Department of Prosthodontics for the restoration of endodontically treated mandibular posterior right tooth. Clinical examination revealed missing mandibular right first premolar and grade-I mobility of mandibular right first molar (figure 1). Radiographic examination revealed an expansive radiolucency at the apical area of the mesial root of the first molar and loss of inter-radicular bone (Figure 2) with Tarnow and Fletcher's Class-C(3) furcation involvement. It was determined to be a case of Weine's class-III type(4) of endodontic and periodontic problem. Treatment options for such furcation involvement includes: a) Scaling and root planning; b) Open flap clean out; c) Guided Tissue Regeneration and d) Resective surgery. First three options are limited by the extent of the furcation involvement and are ruled out. After reflecting a conservative flap root resection of mandibular right first molar was performed using diamond cylindrical bur. Mesial root was extracted (Figure 3). Patient did not report any post-op complication and results remained stabilized at 6 months follow up.

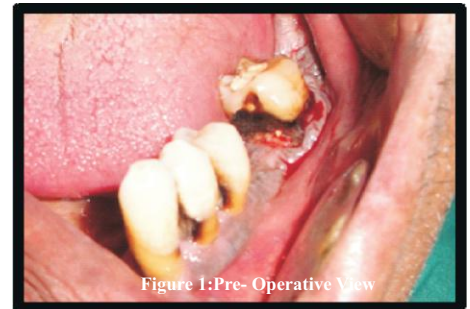

Figure 1: Pre- Operative View

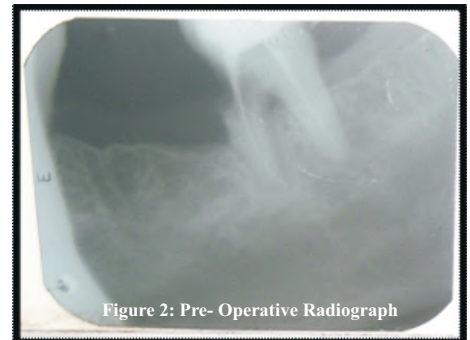


Figure 2: Pre- Operative Radiograph

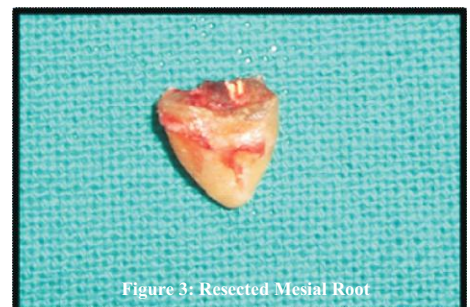


Figure 3: Resected Mesial Root

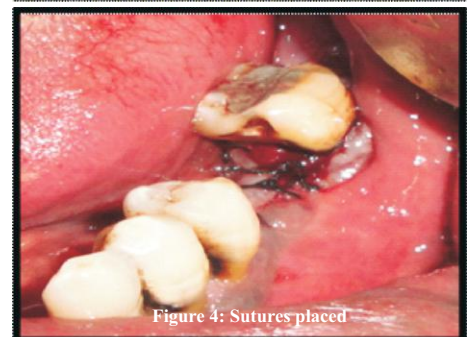


Figure 4: Sutures placed

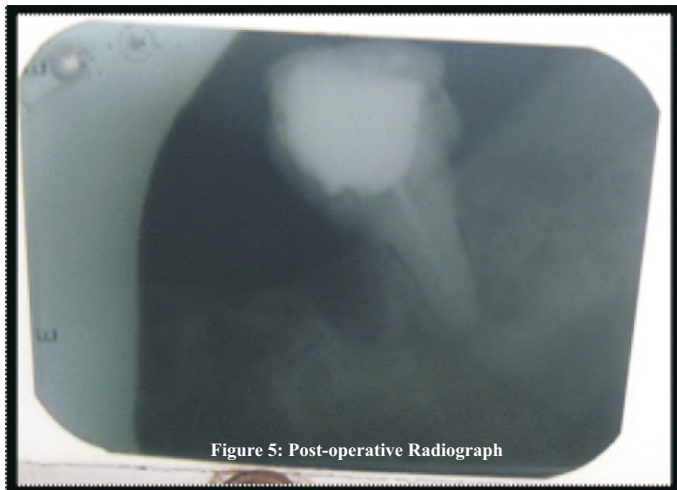


Figure 5: Post-operative Radiograph

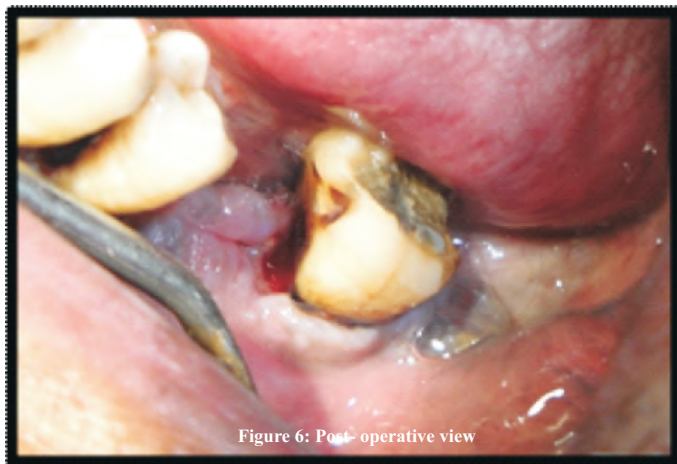


Figure 6: Post-operative view

Discussion

Root amputation is a useful alternative procedure to save those multi-rooted teeth, which have been indicated for extraction. Before selecting a tooth for root amputation, patient's oral hygiene status, caries index and medical status should be considered. Also, accessibility of root furcation for easy separation as well as good bone support for the remaining root should be assessed.⁵

For a variety of reasons, maxillary and mandibular molars are shown to be more susceptible to periodontal disease. Proper maintenance of molar teeth becomes problematic as apical migration of osseous supporting structures allows bacterial invasion of the furcation. Undeniably, untreated furcated molars will lead predictably to more bone loss.⁶⁻¹¹

Black mentions root amputations under the heading of "Radical Treatment". He felt.

That unresolved periodontal suppurations provided niduses for systemic infections.

Thus if palliative measures were ineffective, the offending tooth or root should be promptly extracted.¹¹

Messenger and Orban in 1954 reported on four cases of root amputation in order to achieve pocket elimination. All teeth had been treated with standard root canal therapy prior to root removal. The resected teeth were reported functioning well as long as 15 years postoperatively.¹⁰

Amen indicates that root amputation and hemisection are especially useful in isolated areas of extensive breakdown where adequate new attachment is unlikely, and resective techniques necessary to eliminate the

defect would compromise the periodontal support of the adjacent teeth.⁹

Although such involvement diminishes the long-term prognosis of the affected tooth, extraction is not always an option. Root resection therapy is one of the several treatment modalities that can be used in such cases.

Conclusion

Root amputation and hemisection should be considered as another weapon in the arsenal of the dental surgeon, determined to retain and not remove the natural teeth. With recent refinements in endodontics, periodontics and restorative dentistry, root amputation has received acceptance as a conservative and dependable dental treatment and teeth so treated have endured the demands of function.

Reference

1. Garg R, Manoj M, Khan MM, Babu S.P.K.K. Division for Conservation- A Case Report on Hemisection. Arch of Dent and Med Res 2015;1:91-4.
2. Parmar G, Vashi P. Hemisection: A case-report and review. Endodontology. 2003;15:26-9.
3. Basaraba N. Root Amputation and tooth hemisection. Dent Clin of N Amer 1969;13 : 121
4. Weine FS. Endodontic Therapy, 5th Edition.
5. Kurtzman GM, Silverstein LH and Shatz PC, "Hemisection as an alternative treatment for vertically fractured mandibular molars," CompendContinentEduc Dent, vol. 27, pp. 126-9, 2006.
6. Marshall-Day CD, Skourie KL. A roentgenographic survey of periodontal disease in India. J Am Dent Assoc 1949;39:572.
7. Marshall-Day CD, Septhens RG, Quigley L. Periodontal disease: Prevalence and incidence. J Periodontol 1955;26:185.
8. Ramfjord SP. The periodontal status of boys 11 to 17 years old in Bombay, India. J Periodontol 1961;32:237.
9. Becker BE. Untreated periodontal disease: A longitudinal study. J Periodontol 1979;50:234-244.
10. Payot P, Bickel M, Cimasoni G. Longitudinal quantitative radiodensitometric study of treated and untreated lower molar furcation involvements. J Clin Periodontol 1987;14:8-18.
11. Björn A, Hjort P. Bone loss of furcated mandibular molars. A longitudinal study. J Clin Periodontol 1982;9:402-408

Heal Talk Award 2019

Nomination starts....Hurry up.... Apply Till That 31st December 2018

Whatsapp Contact : 9897032872