

HISTOPATHOLOGICAL CHANGES IN MALE RABBITS THYROID GLAND FOLLOWING DRENCHING OF NICKEL CHLORIDE AND THE AMELIORATING EFFECT OF ETHANOLIC *SILYBUM MARIANUM* SEEDS EXTRACT

WASFI DHAHIR ABID ALI¹, ZAINAB WAHEED KHUDAIR² & MANHAL JABBAR ABED³

¹College of Nursing, University of Basrah, Iraq

^{2,3}College of Veterinary Medicine, University of Basrah, Iraq

ABSTRACT

Nickel chloride known as one of the heavy metals that induce damage in different body organs also silymarin act as anti oxidants and have ameliorative effects against many diseases and drugs. The histological effect of nickel chloride and *Silybum marianum* seeds ethanolic extract on thyroid gland of fifteen male rabbits (*Lepus cuniculus*) were studied for 35 days. Three groups of rabbits (n = 5 each), first group rabbits served as control and given 1 ml normal saline, second group treated orally with dosages of 1mg/100g B.W nickel chloride, the third group treated nickel chloride 1mg/100g B.W plus 0.1mg silymarin extract. The results revealed a severe damage of thyroid gland structures while *Silybum marianum* extract ameliorated the severity of damage.

KEYWORDS: Thyroid, Nickel, Silymarin

INTRODUCTION

Thyroid gland secretes hormones T3 and T4 which stimulated by TSH that secreted from pituitary gland to control the body's metabolic rate and using iodine to create thyroid hormone, this gland affected by some heavy metals [1, 2]. Nickel is the heavy metal that originates from different natural and artificial sources as air, water, soil and living organisms (ATSDR 2005), and it is most rapidly and completely absorbed in animals and human. Study showed that nickel significantly decreases iodine uptake by the thyroid (Bogdan, et al. 2011). Heavy metals affect thyroid function in different ways, some of them via affecting thyroid hormone receptors as in arsenic Ciarrocca, et al. 2012 and Jennifer et al. 2007. Hammouda, et al. (2008) stated that thyroid dysfunction induced by cadmium. Liang, et al. (2003) found that lead exposure can lead to depressed thyroid hormone levels. Study concerning the histological effects on structure of thyroid tissue were few, in rats, injection of nickel sulfate (NiSO₄) caused epithelial proliferation in the thyroid glands (Al-Mogairen, (2009)). Potassium dichromate induced structural changes in the thyroid follicular cells that were partially improved by vitamin C supplementation (Reda and Sadika, 2012).

Silymarin extracted from *Silybum marianum* known as antioxidant, Sonnenbichler et al. (1999) pointed cytoprotective effects of silymarin against both the disease and/or drugs-induced renal damage more ever silymarin minimized the incidence and severity of histopathological changes in liver Maryam et al. (2010). (Sallan et al. 2006) insure the ameliorative effects of silymarin on liver damage induced by lead toxicity in rats and in rabbits against alcohol toxicity Shallen et al. (2007).

MATERIALS AND METHODS

Fifteen male rabbits (*Lepus cuniculus*) of 8 to 10 month age weight 1.250-1.500 kg, randomly divided into three groups ten for each group treated for 35 day. Control group : 5 male rabbits was served as control group and received orally 1 ml normal saline (NaCl 0.9%) and second group orally received 1mg /100gram B.W NiCl_2 orally. Second group : received 1mg /100gram B.W NiCl_2 followed by 0.1mg/100gram B.W ethanolic extract of silymarin from *Silybum marianum* seeds (Iraq-Mosel) (Abid -Ali *et al.* 2014). Thyroid gland isolated surgically for histological examination served in containers filled with 10% formalin. Histopatological technique for microscopic examination leslie and James (2007)

RESULTS AND DISCUSSIONS

Histological changes were found in the cross sections of thyroid gland after 35 day of receiving NiCl_2 , Figure 1 and 2 showed hyperplasia of acinar cells and vaculation of epithelial cells as well as excessive amount of fluid and more acini were without secretion in addition there were mild inflammatory cells figure 3. Hyperplasia of follicular cells and nuclei appeared oval, were seen following acute exposure to hexavalent chromium. Mahmood *et al.* (2010).

C-cell hyperplasia was detected as target cells of thyroid gland for nickel Cheng *et al.* 1997 and Sonne *et al.* 2009). Subcutaneous administration of nickel chloride on rats caused mild proliferation of the thyroid follicles, the follicles became smaller in size, the amount of colloid were diminished and lined by plump cuboidal epithelium (Sultan 2009). The proliferation of the epithelial cells of thyroid gland, the nuclei were transformed suggest that nickel chloride may injure thyroid gland of the rabbits (figure 4).

In the cross section figure 5, thyroid gland tissue structures of the male rabbits that received NiCl_2 plus silymarin extract showed more active acini and less edema and thyroid follicular cells were partially improved silymarin supplementation.

Maryam *et al.*, (2010) showed the important of silymarin against Isoniazid Induced Hepatotoxicity in Rabbits. Rajiha, (2012) found therapeutic effect of *Silybum marianum* on the lead acetate induced toxicity on testes. These finding may provide a basis for the development of novel therapeutic strategies of silymarin for protection against the damages.

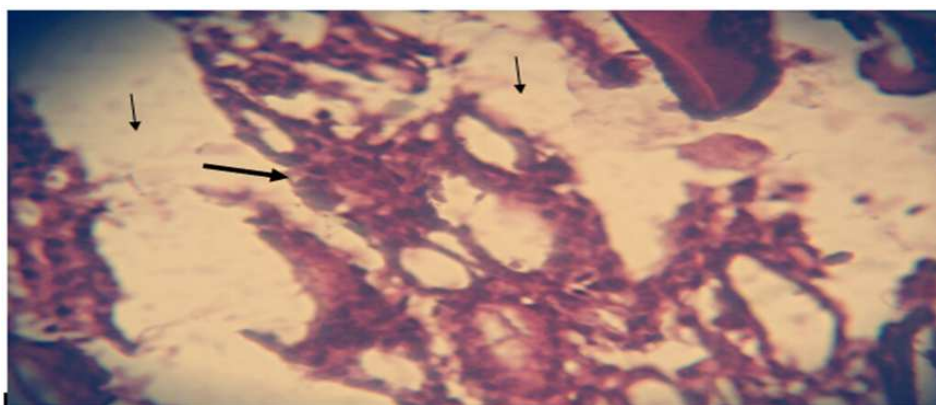


Figure 1: Cross Section in Male Thyroid Gland Treated with Nickel Chloride Showed Hyperplasia of Cells (Thick Row) and Odematous Fluid (Thin Row) (H&E) Stain X 10

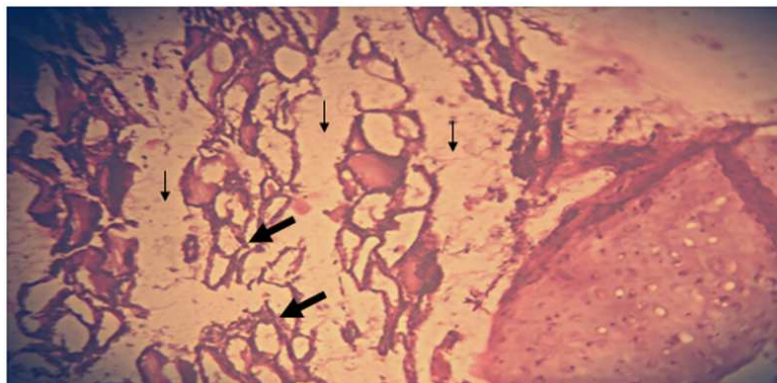


Figure 2: Cross Section in Male Thyroid Gland Treated with Nickel Chloride Showed Excessive Amount of Fluid(Thin Rew) and More Acini are Without Secretion (Thick Rew) (H&E) Stain X 10

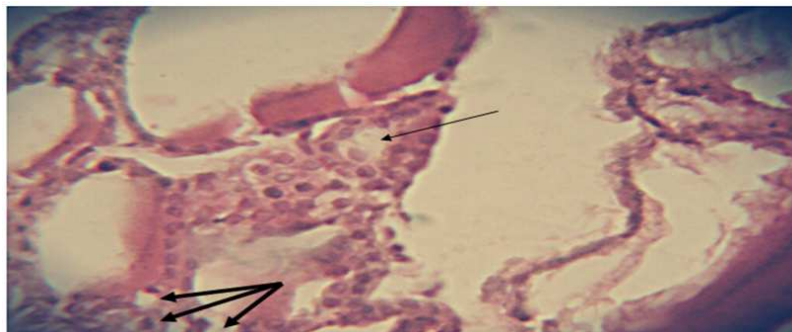


Figure 3: Cross Section in Male Thyroid Gland Treated with Nickel Chloride Showed Hyperplasia of Acinar Cells (Thin Rew) and Vacuolation of Epithelial cells (Thin row) (H&E) Stain X40

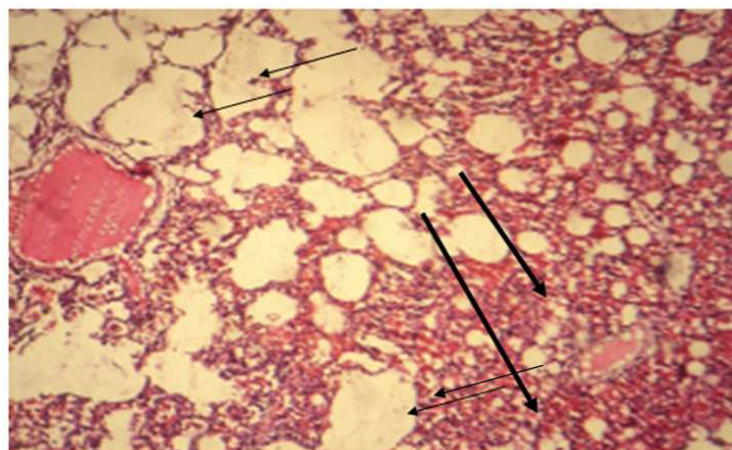


Figure 4: Cross Section in Male Thyroid Gland Treated with Nickel Chloride Showed the Amount of Colloid Diminished in Most Follicles (Thin Row) and Excessive Cells Proliferation(Thick Row) and Odematous Fluid (Thin Row) (H&E) Stain X40

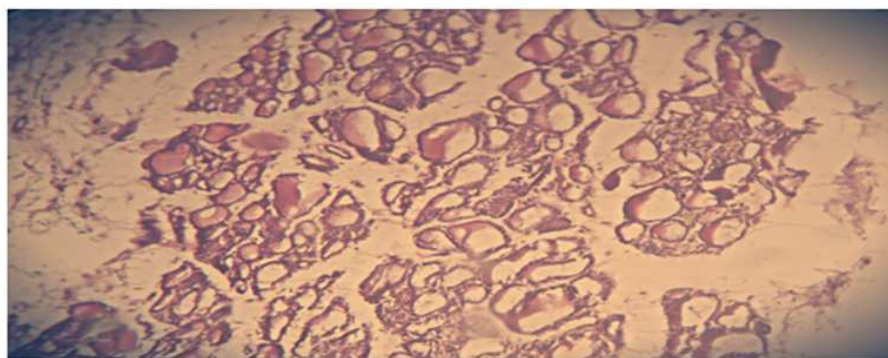


Figure 5: Cross Section in Male Thyroid Gland Tissue Treated with Nickel Chloride Plus *Stylybum marianum* Seeds Extract Showed More Normal Acinar Cells and Secretion, Less Odematous and No Inflammatory Cells (H&E) Stain X10

REFERENCES

1. Abraham G.(2008): Facts about Iodine and Autoimmune Thyroiditis. The Original Internist. Jun; 15(2): 75-6;
2. Abraham G; Flechas JD. and Hakala J.(2002): Orthoiodosupplementation: Iodine sufficiency of the whole human body. The Original Internist. 9:30-41.
3. Agency for Toxic Substances and Disease Registry (ATSDR) (2005). Toxicological Profile for Nickel. US Department of Health and Human Services. Atlanta, US.
4. Al-Mogairen,S.(2009)Induction of an Autoimmune Thyroid Disease with
5. Nickel Chloride in Brown Norway Rats .King Saud University, Medicine, Riyadh, Saudi Arabia7- 10.
6. Bogdan, G,Carmen G, Stelian D., Anca B., and Simona P.(2011): Heavy Metals Acting as Endocrine Disrupters. Animal Science and Biotechnologies, 44 (2).
7. Bullock K.; Woodson E.; Tao H.; Boerner S.; Smolkin M.;and Grosh W.(2005): Autoimmune Toxicities associated with the administration of anti-Tumorvaccines and low-dose Interleukin-2. J Immunother; 28: 412-419.
8. Cheng W.; Zhou Z.; Yang Y.;Yin C.;and Chai. (1997): Effect of nickel sulfate on the concentrations of T3, T4 and TSH in serum of rat. Wei Sheng Yan Jiu.Jan; 26(1):53-5, 59.
9. Ciarrocca, M., Tomei, F, Caciari, T., Cetica, C., Andr , J., Fiaschetti, M., Schifano, M., Scala, B., Scimitto, L., Tomei, G, Sancini, A.(2012): Exposure to arsenic in urban and rural areas and effects on thyroid hormones. Inhal Toxicol. 24(9):589-98.
10. Hammouda, F, Messaoudi, I., El Hani, J., Baati, T., Sa d, K.and Kerkeni, A.(2008) : Reversal of cadmium-induced thyroid dysfunction by selenium, zinc, or their combination in rat. Biol Trace Elem Res. 126(1-3):194-203.
11. Jennifer. C., Athena, P., Manida, W., Jenna, R.,, Sherman, L., Cavus, B., Jean, P., and Joshua, W. (2007): endocrine disruptor at low, environmentally relevant levels, alters steroid signaling at the level of receptor-mediated gene regulation for all five steroid receptors. Environ Health Perspect. 116(2): 165–172.

12. Liang, Q., Liao, R., Su, S., Huang, S., Pan, R. and Huang, J.(2003):To explore the effects of lead on the thyroid function of occupationally exposed workers. *Zhonghua Lao Dong Wei Sheng Zhi Ye Bing Za Zhi*. 21(2):111-3.
13. Nickel Chloride in Brown Norway Rats .King Saud University, Medicine, Riyadh, Saudi Arabia7- 10.
14. Sonne C, Wolers H, Leifsson PS, Iburg T, Jenssen BM,and Fuglei E, (2009):Chronic dietary exposure to environmental organo chlorine contaminants induces thyroid gland lesions in Arctic foxes (*Vulpes lagopus*).*Environ Research* ; 109: 702-711.
15. Shalan, M.; Abd Ali, W. Dh.and, Shalan, A.(2007): The protective affecacy of Vitamins(C and E), selenium and silymarin supplementation against alcohol.J. World Rabbit Sci. 2007, 15: 103 – 110.
16. Shalan, M.;Abd-Ali,W and Shalan,A.(2006):The protective role of vitamins(C&E), selenium, Silymarin supplement against alcohol intoxication. J. of world rabbit science, 15:103-110.
17. Maryam, S.; Bhatti ,A.and Shahzad, A.(2010): Protective Effects of Silymarin in Isoniazid Induced Hepatotoxicity in Rabbits .*ANNALS* .Vol. 16. NO.1.
18. Rajiha, A. (2012): The therapeutic effect of *Silybum marianum* on the Lead Acetate Induced - Reproductive Toxicity in Both Gender Laboratory Rats. *Journall for Science & Mediicine* Vol. 5 (1): (144 – 15.
19. Reda H. ElBakry, Sadika M. Tawfik (2012):Histological study of the effect of potassium dichromate on the thyroid follicular cells of adult male albino rat and the possible protective role of ascorbic acid (vitamin C) *Journal of Microscopy and Ultrastructure* Volume 2, Issue 3, September 2014, Pages 137–150.
20. Mahmood, T.; Qureshi, I. and Iqbal M.(2010):Histopathological and biochemical changes in rat thyroid following acute exposure to hexavalent chromium.*Histol.Histopathol*, 25 (11) ,pp. 1355–1370.
21. Leslie, P. and James, L. (2007): *Colored text book of histology* .by Saunders,animprint of Elsevier Inc. PP: 1-2.

