



Contents lists available at ScienceDirect

Asian Pacific Journal of Tropical Medicine

journal homepage: www.elsevier.com/locate/apjtm

Document heading doi:

Preventive effects of sevoflurane treatment on lung inflammation in rats

Shu–Ye Song, Bing Zhou, Shuang–Mei Yang, Guo–Ze Liu, Jian–Min Tian, Xiu–Qin Yue*

Department of Anesthesiology, Xinxiang Medical College First Affiliated Hospital, Weihui 453100, Henan, China

ARTICLE INFO

Article history:

Received 10 October 2012

Received in revised form 15 November 2012

Accepted 15 December 2012

Available online 20 January 2013

Keywords:

Sevoflurane

Acute lung injury

LPS

Cytokines

ABSTRACT

Objective: To observe the effects of sevoflurane treatment on lung inflammation in rats with lipopolysaccharide-induced acute lung injury (ALI). **Methods:** The rat model of ALI was established by intratracheal instillation of lipopolysaccharide (LPS). 45 infantile SD rats [body weight (272±15) g] were randomly divided into 3 groups (n=15): control group, LPS group, sevoflurane group. NS (1 mL/kg) was instilled in rats' airways of control group; LPS (5 mg/kg) was instilled in rats' airways of LPS group. Sevoflurane group rats received sevoflurane (2.4%) inhalation for a hour after LPS was instilled in rats' airways. Six hours after NS or LPS instillation, all rats were exsanguinated. Lung tissues were examined by HE staining. Expressions of TNF- α and ICAM1 mRNA were detected by semiquantitative RT-PCR techniques. The protein level of TNF- α and ICAM1 were assessed by western blot techniques. **Results:** In LPS group the permeability of lung tissues increased, organizational structure severely damaged and the alveolar wall tamed thick, with interstitial edema and Europhiles infiltrated increasingly. The LPS group had higher mRNA expressions of TNF- α and ICAM1 than control group and sevoflurane group ($P<0.05$), and LPS group had higher protein level of TNF- α and ICAM1 than control group and sevoflurane group ($P<0.05$). **Conclusions:** Sevoflurane treatment can attenuate lung inflammation in rats with lipopolysaccharide-induced acute lung injury.

1. Introduction

Acute lung injury (ALI) is acute hypoxia respiratory insufficiency or failure caused by diffused pulmonary interstitial and alveolar oedema of pulmonary capillary endothelial cells in serious infection, shock, trauma, burns and other non cardiac disease process[1].

Lipopolysaccharide (LPS), the outer membrane of composition of Gram negative bacteria can directly or indirectly damage alveolar epithelium and pulmonary vascular endothelial cells[1], induce a series of lung tissue pathological physiological change, and then development as the ALI[2]. LPS may induce excessive activation of NF- κ beta in lung tissue, participate in a variety of genes related

to early body defense reaction, such as expression and regulation of cell factors, adhesion molecules, inflammation medium, in the development process of ALI[3]. Sevoflurane is a new type of inhalation anesthetics with characteristics of induced quickly and small excitant, has good blood dynamics stability, its pretreatment[4] and reprocessing effect research become clinical research hot spots in recent years. Research shows that sevoflurane pretreatment can reduce endotoxin induced acute lung injury, protect lung function[5]. Inhalation anesthetics post-processing may be a protective scheme for viscera from reperfusion injuries[6].

2. Materials and methods

2.1. Experimental animal

Clean grade male SD rats were from Shanghai Weasleyg Experimental Animal Co., LTD.. 45 male SD rats of weight (272 ± 15) g, were randomly divided into three groups, with

*Corresponding author: Xiu–Qin Yue, MD, Chief Physician, Professor, Master Tutor, Department of Anesthesiology, Xinxiang Medical College First Affiliated Hospital, Weihui 453100, Henan, China.

Tel: 0373–4402405; +008613937338785

E-mail: xiuqinyue@163.com

Foundation project: Supported by Henan Province health science and technology creative talents innovation talents Foundation (Grant No. 20114155).

15 in each, (1) the control group: 0.9% NaCl + 0.9% NaCl; (2) the endotoxin (LPS) groups: 0.9% NaCl + LPS; (3) sevoflurane groups: 0.9% NaCl + LPS. Rats were moved to anesthesia box after 4 h since modeled, with sevoflurane inhalation (concentration 2.4%) for 1 h, during spontaneous breathing.

2.2. Animal model establishment

With reference to the Chin method^[7], 40 mg/kg of pentobarbital was injected to rats by intraperitoneal injection. After anesthesia, limbs were fixed with high cutting teeth on board. By neck shaving, the median incision skin was 1 cm long, blunt separation organization was conducted to exposure trachea, with reagent extraction by 1 mL syringe, grafted in 25-gauge needle to puncture trachea; LPS or NS to trachea was injected slowly (30 seconds) after bubble appeared, suture incisions was performed. All rats were then put back to the cage with food and water supply freely, using desk lamp to maintain the body temperature at 37.5 °C.

2.3. Tissue samples collection

The rats were sacrificed after 6 h since injection of LPS or NS. Pathology observation was performed under HE staining. Total RNA and protein were extracted for mRNA and protein detection. Protein expression was determined by Western blot method. Cracking cells was performed with cell cracking fluid (Cell Signaling Technology company, USA), supernatant fluid was exacted after centrifuging, and total protein was detected using G-250 staining (total protein 50 μg for Western blot test).

2.4. Methods

2.4.1. Histotomy

The lower lobe was processed with 10% formaldehyde solution, 70%–100% alcohol gradient dehydration, xylene processed for 2 times for embedding, Spliced the wax fixed with section at thickness of 5–8 μm, and then put sample in constant temperature box at 45 °C.

2.4.2. HE staining

The paraffin was taken off by Xylene, then alcohol from high was daaded to low concentration, and finally distilled water was added for staining.

2.4.3. Detection pf mRNA of TNF-α and ICAM1 by RT-PCR

Total RNA of three groups was extracted with Trizol

method for reverse transcription, using β-actin as internal reference. Primer sequence was: upstream: 5'-GCTCGTCGTCGACAACGGCTG-3', downstream: 5'-CAAACATGATCTGGGTCATCTTTTC-3', amplified fragment for 353 bp. Rats TNF alpha primer sequence: upstream 5'-TGAGCACAGAAAGCATGATC-3', downstream: 5'-CATCTGCTGGTACCACCAGTT-3', amplified fragment for 396 bp; ICAM1 primer: 5'-TTTTGGCTCGGAAGGTGG-3' upstream, downstream 5'-TGTCGGATTGGAAGTGGC-3', amplification product length 421 bp; Electrophoresis image was analyzed by using Gelpr04 software, the average optical density value was set as representative density, on behalf of the corresponding amount of gene expression, and then divided by β-actin average optical density value, the results stand for the amplification product relative mRNA expression quantity.

2.4.4. Detection of lung tissue TNF-α and ICAM1 by Western blot method

Western blot (5% gel) was carried out under 80 eV, using Odyssey for scan.

2.5. Statistical analysis

SPSS 13.0 statistics software was used. Measurement data was analyzed with mean ± SD, *t* test was carried out for groups comparison. *P* < 0.05 was regarded as having statistical significance.

3. Results

3.1. General and histological observation

Normal lung's appearance was pink, without obvious abnormal change. After LPS injection, lungs became dark red, volume and weight increased, with flake bleeding points in the visceral pleura, also with serious changes, like yellow or pale red liquid overflow. By light microscopy, alveolar structure in control group was clear and complete, without edema, inflammation pathological changes in alveolar, pulmonary interstitial, pulmonary vascular and bronchial (Figure 1). After LPS injection, alveolar lumen narrowed, alveolar wall blood capillary dilated, pulmonary interstitial inflammatory cell infiltrated, alveolar wall thickened, with pulmonary interstitial congestion and a small amount of bleeding in part of the alveolar cavity, as well as micro thrombus and formation of transparent membrane (Figure 2). HE staining showed that in sevoflurane group, alveolar lumen narrowed, alveolar wall thickened, but the lesions

were significantly lighter than LPS group (Figure 3).




Figure 1. HE staining of control group.

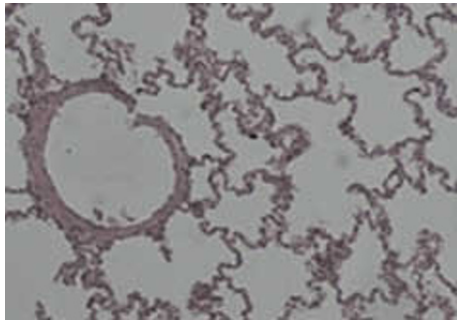


Figure 2. HE staining of LPS group.

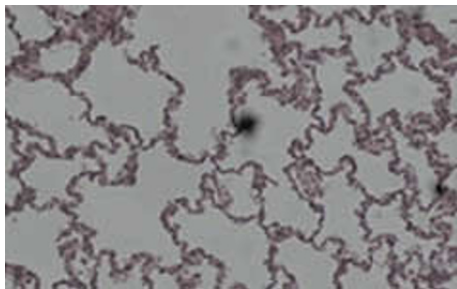


Figure 3. HE staining of sevoflurane group.

3.2. RT-PCR results

Figure 4 and Table 1 shows that mRNA of TNF alpha and ICAM1 in LPS group was significantly higher than that of the control group ($P<0.05$), and mRNA of TNF alpha and ICAM1 in sevoflurane group was significantly lower than LPS group ($P<0.05$).

Table 1 mRNA detection results of TNF- α and ICAM1.

Group	TNF- α	ICAM1
Control group	0.72 \pm 0.06	0.48 \pm 0.09
LPS group	1.53 \pm 0.18*	1.22 \pm 0.28*
Sevoflurane group	1.34 \pm 0.09**	0.94 \pm 0.03**

* $P<0.05$, compared with control group; ** $P<0.05$. compared with LPS group.

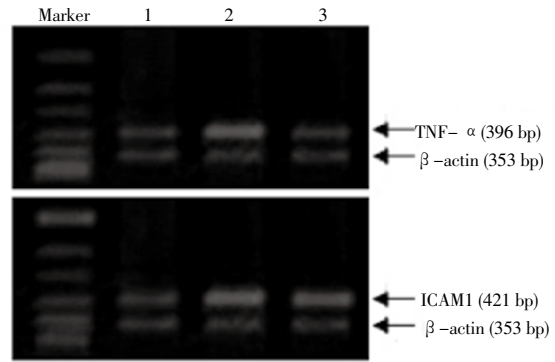


Figure 4. mRNA expression results. 1-control group; 2-LPS group; 3-sevoflurane group.

3.3. Westernblot results

Figure 5 and Table 2 shows that protein banding imprinting of TNF alpha and ICAM1 in LPS treatment group was significantly higher than that of the control group and sevoflurane group ($P<0.05$).

Table 2 Protein expression results of TNF- α and ICAM1.

Group	TNF- α	ICAM1
Control group	107.36 \pm 7.91	97.23 \pm 2.03
LPS group	155.79 \pm 8.01*	135.37 \pm 6.02*
Sevoflurane group	123.55 \pm 5.47**	118.01 \pm 5.09**

* $P<0.05$, compared with control group; ** $P<0.05$. compared with LPS group.

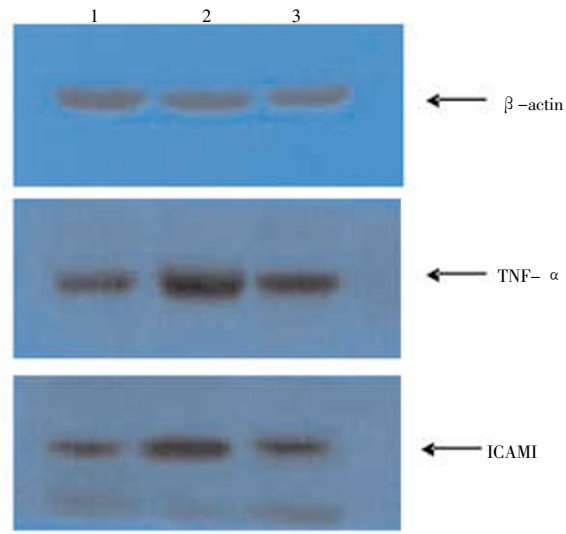


Figure 5. Protein imprinting results. 1 control group; 2 LPS group; 3 sevoflurane group.

4. Discussion

LPS is Gram negative bacteria cells outer membrane composition, main pathogenic composition is

lipopolysaccharide, can stimulate a variety of inflammatory medium to release. LPS can activate macrophages to release inflammatory medium, chemotaxis and arrest of neutrophils in the lungs, triggering local inflammatory reaction and produce lung injury, LPS itself also have direct damage effect to lung epithelial and vascular endothelial, with the exact ALI model^[8].

Neutrophils gathered together in the alveoli in LPS rats, is early signal of pneumonia disease reaction. In the lungs and/or blood circulation, inflammatory factors such as TNF alpha and ICAM1 stimulate the polymorphonuclear leukocyte (PMN) to be seized in pulmonary capillaries, then adhesive in endothelial and exit the pulmonary vascular bed with continuous activation, producing a large amount of cytokines, oxygen free radicals, hydrolytic enzyme and so on, causing diffuse alveolar damage, and ultimately lead to ALI. Migration of PMN from pulmonary vascular to the lung is a complicated process, involving adhesion molecules and chemokines^[9], inhibit any link of process may affect PMN gathering. TNF alpha generated by the monocyte/macrophage during the first release of cytokines, is an important inflammation initiation factor^[10]. It can also increase cell adhesion molecule, and finally make inflammation cells to infiltrate through the tissue, then induce cell apoptosis.

Sevoflurane is a common clinical inhalation anesthetics, pure use of sevoflurane inhalation has no effect to lung organization, but it can improve the endotoxin in lung injury. Research shows that seven halothane can relieve expression of TNF alpha in acute lung injury induced by endotoxin, mainly through reducing the release of some cell factor and chemical factor from alveolar macrophages^[11]. Suter *et al* found that sevoflurane can reduce the lung tissue edema and inflammatory cell infiltration induced by endotoxin^[12]. Voigtsberger *et al*^[13] and Yue *et al*^[14] respectively found that sevoflurane inhibited inflammatory reaction induced by LPS in acute lung injury. But the mechanism is still not clear, it may be through a variety of signaling pathways, such as PKC, myosin and phosphorylation and mitogen activated protein kinase MAPK pathway, working on the target point of pulmonary vascular endothelial cells and epithelial cell, and ultimately improve the lung tissue permeability, its specific regulatory mechanism needs to be further in-depth study.

This research shows that pneumonia disease reaction in sevoflurane treatment group was significantly lower than the LPS group, indicating sevoflurane has certain inhibition to pneumonia disease reaction. But compared with the control group, there are still certain increases, indicating that sevoflurane can decrease the inflammatory cytokines release to certain degree, but still need to coordinate with other support treatments to fully improve lung function change.

Conflict of interest statement

We declare that we have no conflict of interest.

References

- [1] Bernard GR, Artigas A, Brigham KL, Carlet J, Falke K, Hudson L, et al. The American–European consensus conference on ARDS. Definitions, mechanisms, relevant outcomes, and clinical trial coordination. *Am J Respir Crit Care Med* 1994; **149**: 818–824.
- [2] Chen J. Research progress of endotoxin induced acute lung injury. *Foreign Med* 2005; **26**(3): 137–141.
- [3] Li ZJ, Wang WX. Effects of acetylcysteine on lung injury of experimental rat with severe acute pancreatitis study. *Microcirc J* 2009; **19**(2): 17–19.
- [4] Tanaka K, Ludwig LM, Kersten JR, Pagel PS, Warltier DC. Mechanisms of cardioprotection by volatile anesthetics. *Anesthesiology* 2004; **100**(3): 707–721.
- [5] Yue T, Roth Z, Zraggen B, Blumenthal S, Neff SB, Reyes L, Booy C, et al. Postconditioning with a volatile anaesthetic in alveolar epithelial cells. *Eur Respir J* 2008; **31**(1): 118–125.
- [6] Zhao S, Wu J, Guo Q, Zhang Z, Ye Z. Effects of different concentrations of sevoflurane pretreatment on acute lung injury induced by endotoxin in rats. *Zhong Nan Da Xue Xue Bao Yi Xue Ban* 2010; **35**(9): 921–927.
- [7] Chin JY, Koh Y, Kim HS, Kim HS, Kim WS, Kim DS, et al. The effects of hypothermia on endotoxin–primed lung. *Anesth Analg* 2007; **104**(5): 1171–1178.
- [8] Dauphinee SM, Karsan A. Lipopolysaccharide signaling in endothelial cells. *Lab Invest* 2006; **86**(1): 9–22.
- [9] Kubo H, Doyle NA, Graham L, Bhagwan SD, Quinlan WM, Doerschuk CM. L- and P-selectin and CD11/CD18 in intracapillary neutrophil sequestration in rabbit lungs. *Am J Respir Crit Care Med* 1999; **159**(1): 267–274.
- [10] Cohen J. The immunopathogenesis of sepsis. *Nature* 2002; **420** (6917): 885–891.
- [11] Steurer M, Schläpfer M, Steurer M, Zraggen BR, Booy C, Reyes L, et al. The volatile anaesthetic sevoflurane attenuates lipopolysaccharide–induced lung injury in alveolar macrophages. *Clin Exp Immunol* 2009; **155**(2): 224–230.
- [12] Suter D, Spahn DR, Blumenthal S, Reyes L, Booy C, Zraggen BR, et al. The immunomodulatory effect of sevoflurane in endotoxin–injured alveolar epithelial cells. *Anesth Analg* 2007; **104**(3): 638–645.
- [13] Voigtsberger S, Lachmann RA, Leutert AC, Schläpfer M, Booy C, Reyes L, et al. Sevoflurane ameliorates gas exchange and attenuates lung damage in experimental lipopolysaccharide–induced lung injury. *Anesthesiology* 2009; **111**(6): 1238–1248.
- [14] Yue T, Roth Z, Zraggen B, Blumenthal S, Neff SB, Reyes L, Booy C, et al. Postconditioning with a volatile anaesthetic in alveolar epithelial cells. *Eur Respir J* 2008; **31**(1): 118–125.