

Successful Medical Treatment of Multiple Pulmonary Hydatid Cysts with Albendazole

Mohammad Esmaeil Hejazi¹, Sepideh Tahsini Tekantapeh²✉, Parisa Noorabadi² and Yasin Hejazi⁴

¹Tuberculosis and Lung Disease Research Center, Internal Medicine Department of Imam Reza Hospital, Associated professor in pulmonology, Tabriz University of Medical Science, Tabriz, Islamic Republic of Iran.

²Tuberculosis and Lung Disease Research Center, Internal Medicine Department of Imam Reza Hospital, Internal Medicine Resident, Tabriz University of Medical Science, Tabriz, Islamic Republic of Iran.

³Medicine student, Tabriz University of Medical Science, Tabriz, Islamic Republic of Iran.

ABSTRACT: Surgery has been the principal treatment of pulmonary hydatid cysts in recent years. Also, relapse after medical treatment with benzimidazoles has been reported. This case is about a 56-years old woman with multiple pulmonary hydatid cysts who has been successfully treated using standard medical treatment with albendazole in the form of 4 courses of 3 weeks with 2 week intervals. Successful clinical, radiological and serologic improvement in multiple pulmonary hydatid cysts treatment was obtained using medical treatment only with albendazole. In follow-up X-rays, decrease in cysts numbers and sizes and their emptying were observed and until now, after 21 month no relapse was occurred in serial follow-ups. Because of surgery ineffectiveness in patients with multiple pulmonary hydatid cysts, satisfactory therapeutic response can be obtained using albendazole, but regular follow-ups in order to detect any relapse early is recommended.

Keywords: Albendazole, Benzimidazoles, *Echinococcus granulosus*, Multi-visceral hydatid cysts

PII: S2322-47891600001-6
Received 03 Feb. 2016
Accepted 11 Mar. 2016

CASE REPORT

INTRODUCTION

The cestode "*Echinococcus granulosus*" is a small taeniid-type tapeworm (Brunetti and White, 2012). Hydatid cyst disease spectrum varies from asymptomatic infection to severe disease. The four treatments include: surgery, percutaneous techniques, medical treatment and the watch and wait approach for inactive cysts (Brunetti and Junghanss, 2009). Treatment is routinely based on cyst surgical resection. About 30% cure has been shown in hydatid cyst treatment with albendazole, while 40-50% response was obtained after short term treatment. Usually, Albendazole is prescribed in 4 weeks cycles separated by 1-2 weeks intervals (Brunetti and Filice, 2008). Present study reports noninvasive treatment method in pulmonary hydatid cysts using albendazole, without complication as well as complete response.

CASE REPORT

A 56 years-old woman who was admitted 3-years ago with pyelonephritis. Multiple round areas in Chest X Ray (CXR) were observed incidentally (Figure 1a), which were confirmed in chest CT-Scan (Figure 1b). She was asymptomatic, but multiple pulmonary metastatic lesions with unknown origin malignancy were probable diagnosis. According to multiple round cysts and positive hydatid

cyst serology IgG by ELISA: 6.2(>1.1 positive), the hydatid cyst disease was diagnosed. Because of multiple cysts of lungs, surgery was not performed and standard medical treatment with albendazole was started. This treatment was continued for 5 months (4 courses of 3 weeks with 2 weeks interval). In the next follow-ups, empty pulmonary hydatid cysts with decrease in the number of cysts were observed in X-ray and CT-Scan (Figure 2a and Figure 2b). Also the serology was negative and the patient was asymptomatic. Using medical treatment with albendazole, a significantly clinical, radiological and serologic improvement was obtained. Up to now, in the 21th month follow-up, there has been no relapse. Serologic and radiological follow-ups were continued to early detection of any pulmonary hydatid cysts relapse.

RESULTS AND DISCUSSION

Benzimidazoles have efficacy on small, uncomplicated, inoperable and multiple hydatid cysts (Brunetti et al., 2010). Albendazole dose is 10 to 15 mg/kg in two divided doses for 3 to 6 months (Stojkovic, 2009 and Ranjan, 2015). Relapse has been observed in 14 to 25% of patients, which is sensitive to re-treatment with albendazole. Surgery is the primary treatment option for

hydatid cysts (Grozavu et al., 2014). In WHO guideline for hydatid cyst treatment, surgery was recommended as the treatment of choice, followed by medical therapy for minimum of 2 years (Karaman et al., 2013).

Surgery in comparison with benzimidazoles has more complications, morbidity and mortality and also higher risk of disseminated disease because of intraoperative scolices spread by bloodstream (Stojkovic et al., 2009). Usually, albendazole is given as an adjunct to surgery in order to prevent recurrence. Some cases were reported as complete cure and disappearing of hydatid cysts with albendazole in a daily dose of 10 mg/kg three times a day for four months. The acceptable response to repeat treatment with albendazole in the relapsed hydatid cysts suggests that drug resistance is not developing. One of the major problems of cystic echinococcosis is the frequency of relapses (Brunetti et al., 2010). Increased antibody levels in follow-ups may

be suggestive of residual hydatid cyst or recurrence (Brunetti et al., 2010). If any relapse occurs in follow-ups periods, due to the no drug resistance with benzimidazoles, chemotherapy with albendazole should be started (Franchi et al., 1999). Because of the multiple pulmonary hydatid cysts, the patient was successfully treated with albendazole, together with clinical, radiological and serological improvement. The patient follow-ups were continued with physical examination, CXR and serology with 6-month intervals and until now no relapse was occurred. As our acknowledgment, medical treatment with benzimidazoles is suggested in patients with inoperable hydatid cysts. Considering the possible relapse risk in cured hydatid cyst, follow-ups should continue to detect any recurrence or relapse, which will be treated with benzimidazole.

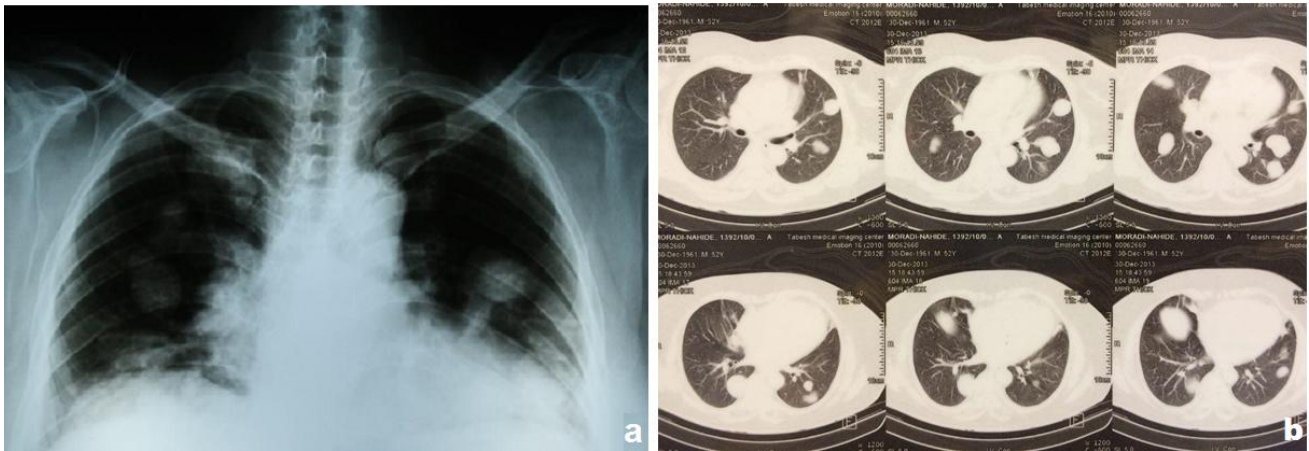


Figure 1. a: Multiple pulmonary round lesions with metastatic-like appearance in an adult woman were seen in chest X ray with high suspicious to metastatic malignancy; **b:** Bilateral multiple round cysts in favor of metastases or pulmonary hydatid cyst in an adult woman were seen in chest CT-scan.

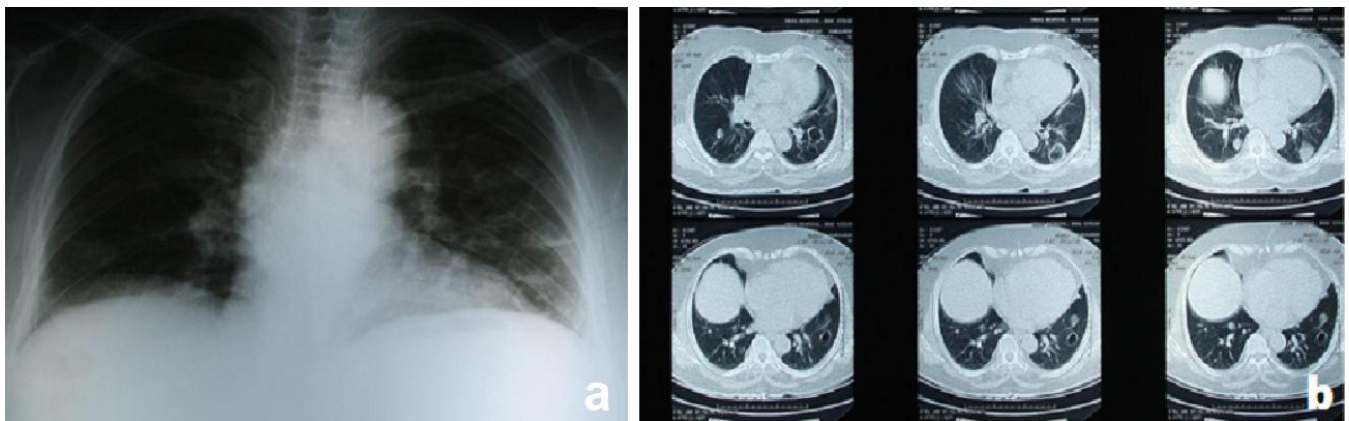


Figure 2. a: Disappeared and emptied cysts in an adult woman were seen in chest X ray after multiple hydatid cysts treatment with albendazole; **b:** Resolved cyst in chest CT-SCAN in an adult woman after medical treatment with albendazole, showing complete response to medical treatment.

Acknowledgments

We would also like to thank to our organization, Tuberculosis and Lung Disease Research Center for providing collection of the patient data and support during our research work.

Competing interests

The authors have stated explicitly that there are no conflicts of interest in connection with this article.

Interactive cardiovascular and thoracic surgery, 16(3): 411-2.

Franchi C, Di Vico B and Teggi A (1999). Long-term evaluation of patients with hydatidosis treated with benzimidazole carbamates. Clin. Infect. Dis., 29(2): 304-9.

REFERENCES

- Brunetti E and Filice C (2008). Echinococcosis hydatid cyst. Available from URL: <http://emedicine.medscape.com/article/216432-overview#showall>, Cited 2011 June 21.
- Brunetti E and Junghanss T (2009). Update on cystic hydatid disease. Curr. Opin. Infect. Dis., 22(5): 497-502.
- Brunetti E and White AC (2012). Cestode infestations: hydatid disease and cysticercosis. Infect. Dis. Clin. North Am., 26(2): 421-35.
- Brunetti E, Kern P and Vuitton DA (2010). Expert consensus for the diagnosis and treatment of cystic and alveolar echinococcosis in humans. Acta Trop., 114(1): 1-16.
- Stojkovic M, Zwahlen M, Teggi A, Vutova K, Cretu CM, Virdone R, Nicolaidou P, Cobanoglu N and Junghanss T (2009). Treatment response of cystic echinococcosis to benzimidazoles: a systematic review. PLoS Negl. Trop Dis., 3(9): 524.
- Ranjan R, Chowdhary P, Pandey A, Mishra S and Madan M (2015). Recurrent Hydatid Cyst of Liver with Asymptomatic Concomitant Hydatid Cyst of Lung: An Unusual Presentation-Case Report. Iranian journal of parasitology., 10(1):136.
- Grozavu C, Ilias M, Pantile D (2014). Multivisceral echinococcosis: concept, diagnosis, management. Chirurgia (Bucur), 109(6):758-68.
- Karaman A, Yalcin A and Alper F (2013). Lung metastasis caused by an infection with *Echinococcus alveolaris*.