



HOSTED BY



ELSEVIER

Contents lists available at ScienceDirect

Journal of Acute Disease

journal homepage: [www.jadweb.org](http://www.jadweb.org)Case report <http://dx.doi.org/10.1016/j.joad.2015.10.003>

## A case report of thyroid storm induced by acute sepsis

Chiu-Yin Yeh<sup>1</sup>, Wen-Liang Yu<sup>1,2\*</sup><sup>1</sup>Department of Intensive Care Medicine, Chi Mei Medical Center, Tainan, Taiwan<sup>2</sup>Department of Medicine, Taipei Medical University, Taipei, Taiwan

### ARTICLE INFO

#### Article history:

Received 26 Mar 2015  
 Received in revised form 20 Jun,  
 2nd revised form 23 Sep 2015  
 Accepted 22 Oct 2015  
 Available online 8 Jan 2016

#### Keywords:

Hyperthyroidism  
 Sepsis  
 Thyroid storm

### ABSTRACT

Thyroid storm is a rare but life-threatening condition, which can be induced by many critical diseases. We reported a 40-year-old woman with thyroid goiter manifesting with acute sepsis-induced hyperthyroidism. She mainly presented with abdominal bloating, diarrhea, lower limbs edema and exertional dyspnea. The lactate was 9.5 mmol/L and procalcitonin was 3.8 ng/mL, suggesting acute sepsis. The thyroid echo showed bilateral thyroid goiter. Relevant data included a thyroid-stimulating hormone level of 0.03  $\mu$ IU/mL; free tetraiodothyronine, 5.67 ng/dL; thyroid-stimulating hormone receptor antibody, 76.9% (normal range, < 14%); and antimicrosomal antibody titer, 1:102400 (normal range, < 1:100), suggesting toxic goiter with thyroid storm. Piperacillin/tazobactam, methimazole and Lugol's iodine achieved a good outcome. The symptoms of early sepsis and those of thyroid storm could be similar. Therefore, a careful history taking, a thorough physical examination and a high degree of suspicion could make early diagnosis and appropriate treatment.

## 1. Introduction

Thyroid storm is a rarely encountered clinical condition. The broad range of symptoms associated with this disease can complicate the diagnosis. Typically, it manifests itself as a state of exaggerated hyperthyroidism accompanied by systemic organ dysfunction, which could mimic severe sepsis<sup>[1]</sup>. The mortality rate was about 10%, most probably due to multiple organ failure<sup>[2]</sup>.

## 2. Case report

A 40-year-old woman has a history of hyperthyroidism diagnosed 5–6 years ago. She did not take any medication after the diagnosis was made thoroughly. Seven days ago, she developed progressive edema of lower limbs, exercise intolerance and exertional dyspnea. Besides, she had abdominal

bloating and diarrhea. Progressive fatigue was noted in recent three days. At our Emergency Department, ascites was noticed and the chest X-ray pattern showed right-sided consolidation with massive pleural effusion (Figure 1A). The cardiac echo showed heart failure. The electrocardiogram showed atrial fibrillation. The C-reactive protein was 14 mg/dL. The serum lactate was 9.5 mmol/L and procalcitonin was 3.8 ng/mL. Severe sepsis was suspected, which was complicated with multiple organ dysfunction, including lung edema, bilateral massive pleural effusions, congestive liver, ascites, and acute respiratory failure. Thus piperacillin-tazobactam was given. The thyroid echo showed bilateral thyroid goiter (Figure 1B). According to the history of patient and the blood thyroid-stimulating hormone of 0.03  $\mu$ IU/mL (normal range, 0.35–5.50  $\mu$ IU/mL), toxic goiter with thyroid storm was suspected. Thus methimazole and Lugol's iodine solution were given to the patient at the intensive care unit. Later, laboratory results included an elevated free tetraiodothyronine of 5.67 ng/dL; thyroid-stimulating hormone receptor antibody, 76.9% (normal range, < 14%); anti-microsomal antibody titer, 1:102400 (normal range, < 1:100) and anti-thyroglobulin titer, 1:100 (normal range < 1:100). The blood and sputum cultures were negative. Diuretic was given for bilateral massive pleural effusions with ascites. As the chest X-ray pattern showed remarkable improvement (Figure 1C), she was then discharged.

\*Corresponding author: Wen-Liang Yu, Department of Intensive Care Medicine, Chi Mei Medical Center, Tainan, Taiwan.

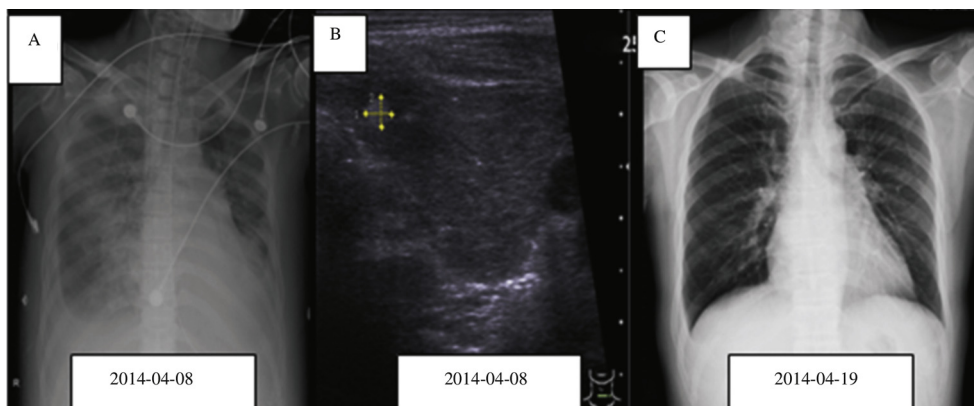
Tel: +886 6 281 2811x52606

Fax: +886 6 283 3351

E-mail: [yuleon\\_md@yahoo.com.tw](mailto:yuleon_md@yahoo.com.tw)

Peer review under responsibility of Hainan Medical College.

Foundation Project: Supported by the Institutional Review Board of Chi-Mei Medical Center (application No. 10402-E05).



**Figure 1.** A: Chest X-ray showed massive pleural effusion; B: Thyroid echo showed bilateral thyroid goiter; C: Chest X-ray showed complete resolution after therapy.

### 3. Discussion

Thyroid storm is a life-threatening condition, which should be part of the differential diagnosis in patients with multiple organ dysfunction of unknown etiology. The diagnosis of thyroid storm has been standardized based on several scoring systems for symptomatic severity<sup>[2]</sup>. Thyroid storm is usually precipitated by an acute illness, such as stroke, surgery, infection, or trauma<sup>[3]</sup>. These critically ill patients require emergent resuscitation to reverse the severe dehydration and adrenal crisis as well as to control the common clinical symptoms such as arrhythmias and congestive heart failure<sup>[4]</sup>. Our patient was most likely precipitated by acute sepsis.

To recognize and differentiate thyroid storm from the non-critical thyrotoxicosis is important as the case fatality rate is currently reported at 10%–25%<sup>[2,4,5]</sup>. The complicated manifestations with multiple apparently unrelated symptoms can confuse the patients and pose a profound challenge to the diagnostic process of the physicians. Moreover, there is no clear cut-off value in the laboratory diagnosis. Thyroid storm is typically associated with Graves' disease, but it may occur in patients with toxic nodular goiter<sup>[6,7]</sup>. The current case highlights the challenges and reminds the clinicians that early diagnosis and therapy through a highly suspicion, careful physical examination and laboratory testing are important. In conclusion, we reported a woman of toxic goiter with severe sepsis-induced

thyroid storm. Early diagnosis and emergent antithyroid therapy achieved a good clinical outcome.

### Conflict of interest statement

The authors report no conflict of interest.

### References

- [1] Rayner SG, Hosseini F, Adedipe AA. Sepsis mimicking thyroid storm in a patient with methimazole-induced agranulocytosis. *BMJ Case Rep* 2013; <http://dx.doi.org/10.1136/bcr-2013-200145>.
- [2] Akamizu T, Satoh T, Isozaki O, Suzuki A, Wakino S, Iburi T, et al. Diagnostic criteria, clinical features, and incidence of thyroid storm based on nationwide surveys. *Thyroid* 2012; **22**(7): 661-79.
- [3] Karanikolas M, Velissaris D, Karamouzou V, Filos KS. Thyroid storm presenting as intra-abdominal sepsis with multi-organ failure requiring intensive care. *Anaesth Intensive Care* 2009; **37**(6): 1005-7.
- [4] Chiha M, Samarasinghe S, Kabaker AS. Thyroid storm: an updated review. *J Intensive Care Med* 2015; **30**(3): 131-40.
- [5] Swee du S, Chng CL, Lim A. Clinical characteristics and outcome of thyroid storm: a case series and review of neuropsychiatric derangements in thyrotoxicosis. *Endocr Pract* 2015; **21**(2): 182-9.
- [6] Lynch MJ, Woodford NW. Sudden unexpected death in the setting of undiagnosed Graves' disease. *Forensic Sci Med Pathol* 2014; **10**(3): 452-6.
- [7] Shahid M, Mahar SA, Asghar A, Alam M. Thyroid storm associated with multinodular goiter: a difficult problem to treat. *J Coll Physicians Surg Pak* 2015; **25**(3): 225-6.