



Contents lists available at ScienceDirect

Journal of Acute Disease

journal homepage: www.jadweb.org



Document heading doi: 10.1016/S2221-6189(13)60093-1

Tension free femoral hernia repair with plug

Milivoje Vuković¹, Nebojša Moljević¹, Siniša Crnogorac²

¹Clinical Center of Vojvodina, Clinic for Abdominal, Endocrine and Transplantation Surgery, Novi Sad, Serbia

²Clinical Center of Vojvodina, Emergency Center, Novi Sad, Serbia

ARTICLE INFO

Article history:

Received 10 January 2012

Received in revised form 15 March 2012

Accepted 15 May 2012

Available online 20 November 2012

Keywords:

Femoral hernia

Mesh+plug

Hernioplasty

ABSTRACT

Objective: To investigate the conventional technique involves treatment of femoral hernia an approximation inguinal ligament to pectineal ligament. In technique which uses mesh closure for femoral canal without tissue tension. **Method:** A prospective study from January 01. 2007–May 30. 2009. We analyzed 1 042 patients with inguinal hernia, of which there were 83 patients with 86 femoral hernia. **Result:** Femoral hernias were present in 7.96% of cases. Males were 13 (15.66%) and 70 women (84.34%). The gender distribution of men: women is 1:5.38. Urgent underwent 69 (83%), and the 14 election (17%) patients. Average age was 63 years, the youngest patient was a 24 and the oldest 86 years. Ratio of right: left hernias was 3.4:1. With bilateral femoral hernias was 3.61% of cases. In 7 patients (8.43%) underwent femoral hernia repair with 9 Prolene plug. **Conclusions:** The technique of closing the femoral canal with plug a simple. The plug is made from monofilament material and is easily formed. This technique allows the reduction of recurrence and can be used safely, quickly and easily in elective and emergency situations.

1. Introduction

Surgical treatment of femoral hernia has a long history. In the 19th century Bassini and Marcy are simply closing the femoral ring, while Cushing published approach for solving the femoral hernia. However, a high percentage of relapse with conventional techniques, require a different approach in dealing with femoral hernia.

It is assumed that the femoral hernia occurs in 7% of all abdominal wall hernias. It occurs most often in middle-aged and older women. Rare in children^[1]. Femoral hernia is represented 4%–7% of the inguinal hernia^[2]. Has a feature that is often complicated by the incarceration, and a tendency to relapses (6.5%)^[3]. Femoral hernias are more common in women^[4–6]. Also, frequently appearing on the right side, due to the anatomical position of the sigmoid colon, which allows the femoral canal tamponade^[5,7]. Femoral canal in women tends to increase and to be oval in shape, creating the conditions for the occurrence of hernia. Pregnancy increases the risk of femoral hernia in women. Femoral hernias have a 40% higher risk compared to the

occurrence of inguinal strangulation, because of the rigid walls of the femoral canal^[5,7]. Increased intra-abdominal pressure during pregnancy, obstructive lung disease or constipation can be a cause of the emergence of femoral hernia.

Femoral hernias can be divided into^[8]:

1. Femoral canal hernia is the most common form of femoral hernia. The hernial sac extends to the upper thigh to the medial side of the femoral canal.
2. Prevascular femoral hernia (Narath) – hernial sac extending through the femoral canal, but there is anterior to the femoral artery and vein.
3. External femoral hernia (Hasselbach and Cloquet) – When the doors hernial bag is lateral to the femoral vessels.
4. Transpectineal femoral hernia (Laugier) – when the hernial sac passes through the lacunar ligament or pectineal (Cooper).
5. Callisen and Cloquets hernia – when the hernial sac in the upper leg goes deeper than the femoral vessels and pectineal fascia.

The most common type of femoral hernia is hernia femoral canal in 98.5% of cases and is the easiest to repair^[8] (Figure 1). Prevascular and retrovascular femoral hernia is extremely difficult to repair.

There are three classical approaches to treatment femoral

*Corresponding author: Milivoje Vuković, MD, PhD: Clinical Centre of Vojvodina, Clinic for Abdominal, Endocrine and Transplantation Surgery, St. Hajduk Veljka 1, 21000 Novi Sad, Republic of Serbia.

E-mail: vukoviens@sbb.rs; micolakatis@gmail.com

hernia: the lower (Lockwood), transinguinal (Lotheissen) and upper (McEvedy). The concept of compliance “with the femoral canal nonresorptive material is an alternative solution to conventional femoral hernia repair. This approach is simple, a technique used since 1974. when he first published a Lichtenstein and Shore^[9,10].

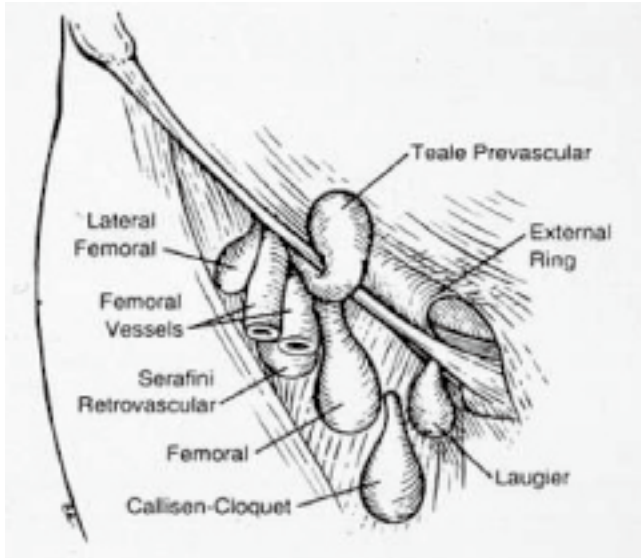


Figure 1. Classification of femoral hernia.

The boundaries of the femoral canal are inguinal ligament superiorly, lacunar ligament medially, caudally pectineal ligament and femoral vein laterally. The femoral canal is funnel shape that is formed from the anteromedial continuing transverse fascia, posterior to the fascia covering the psoas and pectineal muscle, and the sides of the iliac fascia. In the area of the thigh about 3 cm below the inguinal ligament peritoneal lining of the femoral canal fuses with the adventitia of the femoral vessels. Femoral region is divided into three parts:

1. Lateral part with femoral artery,
2. Middle part with femoral vein,
3. Medial part is femoral canal.

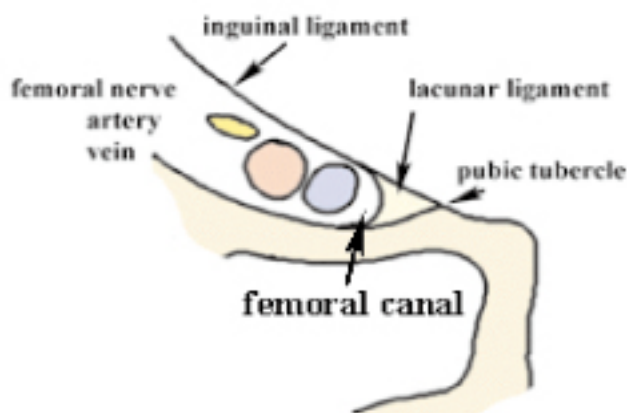


Figure 2. Anatomy of the femoral canal.

Femoral canal has a length of 1–2 cm, and the tip is in communication with the retroperitoneal space through ring then called the femoral. The femoral canal is medial structure thigh, extending from the subcutaneous femoral ring, approximate dimensions are 1.25 cm×1.25 cm and contains fatty tissue, lymph nodes (Cloquet).

The nerves in the inguofemoral region are ilioinguinal, iliohipogastric and genitofemoral. Frequently, during the surgical operation, damage to ilioinguinal nerve. This nerve is located near the external inguinal ring and provides sensory innervation to the branches of the pubic region and the upper part of the scrotum or labia. Iliohipogastric nerve passes over the internal inguinal ring and provides sensory innervation to the skin above the pubis. Genital branch genitofemoral nerve passes from the ductus deferens in the scrotum and gives branches to innervation scrotum and inner thigh. A femoral branch of the lateral femoral provides innervation to the lateral part of the thigh skin^[11,12].

2. Material and methods

The study was conducted prospectively at the Department of Abdominal, Endocrine and Transplantation Surgery in Novi Sad in the period from January 2007–May 2009. We analyzed 1 042 patients with inguinal hernia and 83 pts with 86 complicated femoral hernia. Preoperative preparation included the treatment of comorbid conditions, intravenous administration of antibiotics (cephalosporins) before the operation. The patients were operated under general anesthesia, the possible expansion of surgery and possible laparotomy.

Techniques: Incision of skin and subcutaneous tissue over the hernia, followed by preparation of femoral bag, hernia neck, review contents of the hernial sac, excision and closure of hernial sac. Then return hernial sac thrust into the femoral canal.

Plug prosthesis made of Prolene mesh (Ethicon Ltd.). The list Prolene mesh is cut down to about 8 cm×6 cm. Thus, the net gain of which is folded and securely into a compact plug roll in size 2 cm×0.75 cm. Tightness and shape preservation roll in plug is held with two nonresorptive sutures, which is placed at each end (Figure 3).

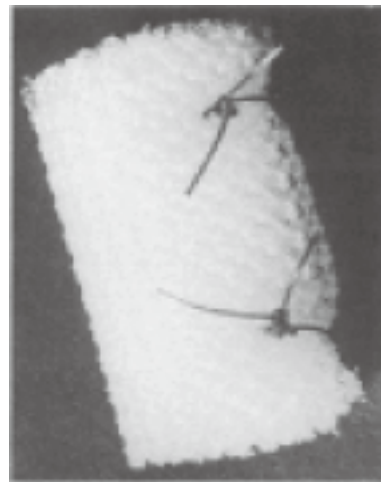

Figure 3. The formation of Prolene mesh plug.

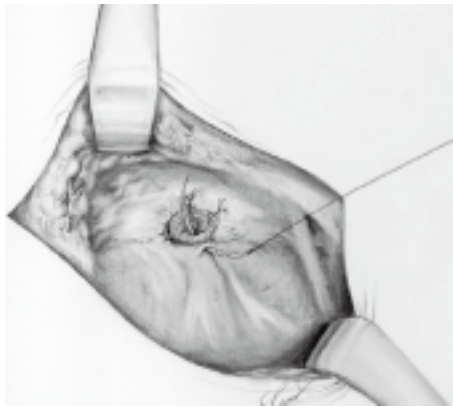


Figure 4. Fixation plug in the femoral canal.

Prolene plug is inserted directly into the defect, closing the femoral canal space. Position the plug in the channel is maintained with two nonresorptive suture between the plug and the inguinal and pectineal ligament. We are secure in our study used three fixation suture (Figure 4). The following routine hemostasis, suture subcutaneous tissue and skin.

3. Results

From January 2007. to May 2009. The operation was performed in 83 patients with 86 femoral hernia. Of the total number of inguinal hernia, femoral makes up 7.96% (83/1042). Over emergency services were operated 69 patients (83%) and 14 patients undergoing elective (17%).

Males were 3 (15.66%) and 70 women (84.34%). The gender distribution of male: female was 1:5.38. Average age of treated patients was 63 years, the youngest patient was a 24 and the oldest 86 years. All patients who underwent surgery over emergency services were complication–incarceration.

There were three cases with bilateral femoral hernia (3.61%). Four femoral hernias were recurrences (4.81%). In 14 (16.86%) cases due to bowel incarceration and consequent gangrene underwent resection. In 24 patients (28.91%) underwent resection of the great omentum. Ratio of right: left hernia was 3,4:1 and 62 right and 18 left hernia. There were three cases with bilateral femoral hernia (3.61%). In 7 patients (8.43%) underwent femoral hernia repair with 9 Prolene plug.

Postoperative follow–up of patients was 6–36 months. In 7 patients with a femoral hernia repair with 9 Prolene plug was not recorded recurrence. There has not been any wound infections, and one patient had a seroma. Postoperative pain was identified in 1 patient, who was successfully treated with medication. There were no other complications during the postoperative period (deep vein thrombosis, migration Prolene plug).

Table 1

Patients characteristics (between Januar 2007 and May 2009, $n=83$).

Characteristics	<i>n</i>
Age	63 (24–86)
Male/female	13/70 (1:5,38)
Treatments	Emergency 69 (83%) Elective 14 (17%)
Surgery	Conventionale 76 (91.56%) Mesh–plug 7 (8.44%)

Table 2

Characteristics of the femoral hernia.

Characteristics	<i>n</i>
Right/Left	62:18 (3.4:1)
Bilateral	3 (3.61%)
Recidive	4 (4.81%)
Resection	38 (45.78%)
Small intestine	14 (16.86%)
Great omentum	24 (28.91%)
Surgery	Conventionale 76 (91.56%) Mesh–plug 7 (8.44%) Follow up (months) 6–36
Postoperative morbidity	Seroma 1 Postoperative pain 1

4. Discussion

Over 30 years various forms of polypropylene mesh have become an accepted method for resolving primary and recurrent hernia. Simple implantation in combination with low complication and recurrence enabled mesh widely used in hernia surgery.

The mesh technique era began in the late 1950s when he experimented with Usher polyethylene, and later adapted for the same reaction in fibroblasts and rapid incorporation into the body^[13,14]. In 1970. Stoppa in France described concept preperitoneal tension free placement of prosthetic mesh for treatment inguinal hernia repair^[4]. Since that time, the use of prosthetic materials in herniology rapidly increased. There is evidence that in adult patients with inguinal hernia, a metabolic defect in the synthesis of collagen. Macroporous mesh allows infiltration of macrophages, fibroblasts, collagen fibers, and angiogenic factors. The pore size must be less than 75 microns in order to allow the infiltration. The smaller pore diameter allows the passage of bacteria, only right before the word it modifies, and macrophages and neutrophils can not penetrate mesh.

It is a common surgical practice to conduct a preoperative dose of intravenous antibiotics (cephalosporin)^[5]. Monofilament biomaterial such as polypropylene do not increase the percentage of infectious complications^[15]. Prolene (polypropylene) is used most often, is hydrophobic, resistant to biological degradation, biological reactivity induced by different depending on the breed, size or, pore size, architecture and denture patient immune response. To decrease the inflammatory response are used more porous and easier to net.

Ideal mesh there today's data suggest that the absorptive mats do not stay long enough to allow for proper formation of collagen^[16]. Multifilament netting can be a barrier to

bacteria, but also the physical mechanisms that eliminate them, so there is no good growth of collagen which does not lead to the strengthening of the inguinal wall^[17,18]. The monofilament polypropylene mesh is currently the most popular and most commonly used^[17].

Lichtenstein and Shore have published the first guide stopper for the treatment of femoral hernia 1968th, and their results show only the 1974 year^[19]. Since then, the treatment of femoral hernia using shad become a standard technique. This approach was developed by Gilbert and Rutkow^[20].

The paper analyzed 83 patients with 86 femoral hernia repair. Femoral hernias accounted for 6.91% of all inguinal hernias in three years, which corresponds to the literature data^[21]. Femoral hernia occurs in all age groups, the most common in older women, so that the oldest patient was 86 years old, and the average age is 63, which corresponds to the literature data^[20].

In cases of gangrene, bowel resection and anastomosis, and therefore contamination of the operative field, we placed Prolene plug. The same approach was also Lichtenstein^[16].

Closure of the defect is performed without tissue tension that exists over the use of conventional techniques^[15]. The conventional technique involves solving femoral hernias approximation of tissue between the inguinal ligament and pectineal. Plug can be done easily and quickly. In addition, this plugin is inexpensive, and it consists of a monofilament material. Monofilament mesh with a low incidence of infection or the implant rejection. Satisfactory closure of the femoral canal to reduce recidive. Techniques of femoral hernia with Prolene plug can be used safely, quickly and easily in elective and emergency situations^[1,15].

The analysis of our results of males and females was 5.3:1 in favor of women, which is slightly higher frequency of females compared to published literature data^[1,20]. Right Hand are more common femoral hernias, and such results in this paper. Right femoral hernias are more common than the dextral relative 3.4:1.

After the surgery is expected to recover completely. Only 1.5%–3% of all hernia relapses. Chance of recurrence depends on the size of the hernia, previous data on the surgical treatment of hernia, the presence of risk factors and surgical techniques. Most recurrent hernias are in fact indirect hernias overlooked during the original surgery. Using nets to strengthen areas of the femoral canal defect can reduce the risk of recurrence. The risk of recurrence may be reduced effect on risk factors for hernia (obesity, chronic constipation, smoking, chronic cough...).

Factors influencing postoperative length of work disability were: type of hernia, surgical techniques, the presence of postoperative complications in the workplace.

The technique of closure of the femoral canal nonresorptive plug is applicable in practical surgical work. Closure of the defect is performed without tissue tension that occurs after the use of conventional techniques. The plug is easily formed. It consists of a monofilament material that has a low incidence of development of infection or rejection of the implant. Satisfactory closure of the femoral canal to reduce recidivism. Solving techniques of femoral hernia with Prolene plug can be used safely, quickly and easily in elective and emergency situations.

Conflict of interest statement

The authors declare that there are no conflicts of interest.

Reference

- [1] Allan S, Heddle R. Prolene plug repair for femoral hernia. *Ann R Coll Surg Engl* 1989; **71**: 220–221.
- [2] Ponka JL, Brush BE. The problem of femoral hernia. *Arch Surg* 1971; **102**: 417–423.
- [3] Welsh DRJ. Inguinal hernia repair. *Mod Med* 1974; **42**: 49–54.
- [4] Manthey D, Nicks BA. Hernias. eMedicine Web site. www.emedicine.com. Updated January 3, 2007. Accessed May 13, 2008.
- [5] Wantz GE. Abdominal wall hernias. In: Schwartz SI, ed. *Principles of Surgery*. 7th ed. New York: McGraw–Hill; 1999, p. 1585–1611.
- [6] Bax T, Sheppard BC, Crass RA. Surgical options in the management of groin hernias. *Am Fam Physician* 1999; **59**(1). <http://www.aafp.org/afp/990101ap/143.html>. Accessed May 13, 2008.
- [7] Gardner RM, Boyd CR. Examining modern approaches to inguinal and femoral herniorrhaphy The newest hernia repair techniques, including the various laparoscopic approaches, require continued learning and practice by the surgeon to develop and maintain proficiency. www.jaapa.com; 2008; **21**(6): 35–41.
- [8] Odula PO, Kakande I. Femoral Hernia At Mulago Hospital. *East Cent Afr J Surg* 2004; **9**(2): 74–77.
- [9] Bendavid R. Femoral “umbrell” for femoral hernia repair. *Surg Gynecol Obstet* 1987; **165**: 153–156.
- [10] Usher FC. Hernia repair with knitted polypropylene mesh. *Surg Gynecol Obstet* 1963; **117**: 239–240.
- [11] Condon RE. The anatomy of the inguinal region and its relation to groin hernia. In: Nyhus LM, Condon RE, eds. *Hernia*. 3d ed. Philadelphia: Lippincott; 1989, p. 18–64.
- [12] Rab M, Ebmer J, Dellon AL. Anatomic Variability of the Iliioinguinal and Genitofemoral Nerve: Implications for the Treatment of Groin Pain. *Plast Reconstructive Surg* 2001; **108**(6): 1618–1623.
- [13] Wantz GE. Abdominal wall hernias. In: Schwartz SI, ED. *Principles of Surgery*. 7th ed. New York: McGraw–Hill; 1999, p. 1585–1611.
- [14] Read RC. The contributions of Usher and others to the elimination of tension from groin herniorrhaphy. *Hernia* 2005; **9**(3): 208–219.
- [15] Shulman AG, Amid PK, Lichtenstein IL. Prosthetic mesh plug repair of femoral and recurrent inguinal hernias: the American experience. *Ann R Coll Surg Engl* 1992; **74**: 97–99.
- [16] Goldstein HS. Selecting the right mesh. *Hernia* 1999; **3**: 23–26.
- [17] Sakorafas GH, Nissiotakis C, Chalikiaris I, Kotsifopoulos N, Stavrou A, Kassaras GA. Open Preperitoneal Mesh Repair of Recurrent Inguinal and Femoral Hernias. *Mount Sinai J Med* 2005; **72**(3): 342–345.
- [18] Sanchez–Bustos F, Ramia JM and Ferrero FF. Prosthetic Repair of Femoral Hernia: Audit of Long Term Follow–up. *Eur J Surg* 1998; **164**: 191–193.
- [19] Lichtenstein IL, Shore JM. Simplified repair of femoral and recurrent inguinal hernia by a “plug” technic. *Am J Surg* 1974; **128**: 439–444.
- [20] Hachisuka T. Femoral hernia repair. *Surg Clin N Am* 2003; **83**: 1189–1205.
- [21] Hair A, Paterson C and O’Dwyer PJ. Diagnosis of a femoral hernia in the elective setting. *J R Coll Surg Edinb* 2001; **46**: 117–118.