



Contents lists available at ScienceDirect

Asian Pacific Journal of Tropical Biomedicine

journal homepage: www.elsevier.com/locate/apjtb



Document heading

doi:

©2012 by the Asian Pacific Journal of Tropical Biomedicine. All rights reserved.

Amaranthus spinosus L. (Amaranthaceae) leaf extract attenuates streptozotocin–nicotinamide induced diabetes and oxidative stress in albino rats: A histopathological analysis

Shanti Bhushan Mishra^{1*}, Amita Verma², Alok Mukerjee¹, Madhavan Vijayakumar³¹ Department of Pharmacognosy, United Institute of Pharmacy, UCER, Allahabad, India² Department of Pharmaceutical Science, Faculty of Health, Medical Sciences, Indigenous & Alternative Systems of Medicine, SHIATS, Allahabad, India³ Ethnopharmacology Division, National Botanical Research Institute, Lucknow, India

ARTICLE INFO

Article history:

Received 15 September 2012

Received in revised form 25 September 2012

Accepted 28 October 2012

Available online 28 December 2012

Keywords:

Amaranthus spinosus

Diabetes

Streptozotocin

Ethanol extract

Biochemical

Histopathology

ABSTRACT

Objective: The aim of the present study was to evaluate the possible antidiabetic effects of *Amaranthus spinosus* leaf extract (ASEt) against streptozotocin–nicotinamide induced diabetes & oxidative stress in albino rats. **Methods:** Experimental diabetes was induced by a single dose of STZ (60 mg/kg) administered by intraperitoneal way after the administration of nicotinamide (120mg/kg). The oxidative stress was measured by reduced glutathione (GSH) content and by enzymatic activities of superoxide dismutase (SOD), catalase (CAT), and glutathione peroxidase (GPx) in liver and kidney. Biochemical observations were further substantiated with histological examination of pancreas, kidney and liver. **Results:** The increase in blood glucose with the decrease in GSH content and in enzymatic activities were the salient features observed in diabetic rats. Administration of ASEt (250 & 500 mg/kg bw/day, i.p) for 21 days caused a significant reduction in blood glucose in STZ–nicotinamide treated rats when compared with diabetic rats. Furthermore, diabetic rats treated with ASEt leaf extract showed a significant increase in the activities of both enzymatic and non–enzymatic antioxidants when compared to those of diabetic rats. Degenerative changes of pancreatic cells in STZ treated rats were minimized to near normal morphology by administration of ASEt leaf extract as evidenced by histopathological examination. **Conclusion:** Results clearly indicate that *Amaranthus spinosus* treatment attenuate hyperglycemia by decreasing oxidative stress and pancreatic cells damage which may be attributed to its antioxidative potential.

1. Introduction

Hyperglycemia evoked oxidative stress plays a crucial role in the development of diabetic complications, including nephropathy, neuropathy, retinopathy and hepatopathy, which is considered to result from augmented reactive oxygen species generation and decreased antioxidant defenses [1]. NIDDM is often associated with the most commonly occurring metabolic and physiologic problems, including elevated blood pressure, cardiovascular diseases, dyslipidemia and high cholesterol levels. Together with visceral obesity, this clustering of risk factors is known as the metabolic syndrome [2–3]. Plants are recognized as a

wonderful source for medicines. It is estimated that 1200 species of plants are used as folk medicines for diabetes. *Amaranthus spinosus* (Amaranthaceae) is widely distributed throughout the tropics and warm temperate regions of Asia from Japan to Indonesia to India, the Pacific islands and Australia as a weed in cultivated as well as fallow lands. In Indian traditional system of medicine (Ayurveda) the plant is used as digestible, laxative, diuretic, stomachic, antipyretic, improves the appetite, biliousness, blood diseases, burning sensation, leprosy, bronchitis, piles and leucorrhoea.[4] Previous reports of this plant showed that its extract was used for its anti–inflammatory properties,[5] effect on hematology,[6] immunomodulatory activity,[7] anthelmintic properties,[8] antidiabetic, antihyperlipidemic and spermatogenic [9–10]. Chemically, it contains 7–p–coumaroyl apigenin 4–O–beta–D–glucopyranoside, a new coumaroyl flavone glycoside called spinoside, xylofuranosyl uracil, beta–D–ribofuranosyl adenine,

*Corresponding author: Shanti Bhushan Mishra, Department of Pharmacognosy, United Institute of Pharmacy, Allahabad –211010
Tel.: +918004279457
Fax: 91(0532) 2687142
E–mail: shantipharmat15@gmail.com

betasitosterol glucoside, hydroxycinnamates, quercetin and kaempferol glycosides, betalains; betaxanthin, betacyanin amaranthine and isoamaranthine, gomphrenin, betanin, b-sitosterol, stigmasterol, linoleic acid, 0.15% rutin and beta-carotene.[11–12] The whole plants of *A. spinosus* are used for the treatment of diabetes in traditional system of medicine. Hence the present investigation is an endeavor to validate the scientific use of 50% ethanolic extract of leaves of *A. spinosus* (ASEt), against streptozotocin–nicotinamide induced diabetes in experimental animals.

2. Materials and methods

2.1. Plant material and extract preparation

The leaves of *A. spinosus* were collected from their natural habitat in and around Lucknow and authenticated by Taxonomist Dr. A. K. S. Rawat. The voucher specimen CIF–RB–2–126–1 was deposited in the departmental herbarium of National Botanical Research Institute Lucknow, India for future reference.

The freshly collected leaves (3 kg) were first air-dried and then dried in tray drier under control conditions and powdered. The powdered leaves (1200g) were macerated with petroleum ether to remove fatty substances; the marc was further exhaustively extracted with of 50% ethanol for 3 days (3 X 3L) by cold percolation method and centrifugation at 10,000 rev/min. The extract was separated by filtration and concentrated on rotavapour (Buchi, USA) and then dried in lyophilizer (Labconco, USA) under reduced pressure and thus 125.0 g of solid residue (yield 12.5 % w/w) was obtained.

2.2. Preliminary phytochemical screening

The extract was subjected to preliminary phytochemical screening for the identification of various active constituents by using standard procedure [13]

2.3. Drugs and chemicals

Streptozotocin (STZ) was purchased from Calbiochem USA. Nicotinamide was obtained from Ranbaxy Chemicals Ltd, India. All other chemicals and reagents used were of analytical grade.

2.4. Experimental animals

Healthy adult Wistar albino rats of both sex, aged between 2 and 3 months of age, weighing 200–250 g were used for the pharmacological studies. The animals were housed in polypropylene cages, maintained under standard conditions (12/12 h light and dark) at 25 ± 3 °C and 35–60% humidity. They were fed with standard rat pellet diet (Amrut, India) and water ad libitum. The Institutional Animal Ethical

Committee, United Institute of Pharmacy, Allahabad, India (No. 1451/PO/a/11/CPCSEA) has approved the study.

2.5. Acute oral toxicity study

The lethal median dose (LD50) determination was done in mice by OECD guidelines 423 [14]. A single dose of the extracts (5 mg/kg, 50 mg/kg, 300 mg/kg and 2000 mg/kg) in appropriate quantity of water was given orally by gavage to different group of mice (three each). The animals were allowed free access to water and food. However, all the animals were deprived of food for 2 hr before and 4 hr after dosing. The animals were continuously monitored during first 4 hrs and every one-hour during the first 12 hrs for any adverse effects. Later they were monitored (daily twice) for any abnormal changes throughout the study period (14 days). The extract was devoid of any toxicity in animals when given in dose up to 2000mg/kg. Hence for further study 250 & 500 mg/kg doses of extract were selected.

2.6. Experimental induction of diabetes

Streptozotocin (STZ) was freshly dissolved in (0.1M, pH 4.5) citrate buffer and Nicotinamide was dissolved in normal physiological saline and maintained on ice prior to use. All animals were allowed to adapt to cages for 3 days, after which they were fasted overnight. Non–insulin–dependent diabetes mellitus was induced in overnight fasted rats by a single intraperitoneal injection of Streptozotocin (60 mg/kg b.w), 15 min after the intraperitoneal administration of nicotinamide (120 mg/kg b.w) all animals were given free access to food and water. Blood glucose levels were measured 2 days after STZ injection and used as parameters to obtain matching pairs of rats with diabetes of similar level of severity. Only rats with fasting blood glucose levels greater than 220 mg/dl were considered to be diabetic and were used in the experiment. The animals were randomly assigned to five different groups i.e. group I to V. Group I served as control containing 6 normal rats. All treatments started 3 days after STZ injection [15].

2.7. Experimental Design

Five groups of rats were used to study the effect of 50% ethanolic extract of *A. spinosus*.

Each group consists of six rats.

Group I – Control rats received vehicle normal saline solution

Group II – Diabetic control rats received vehicle normal saline solution

Group III and IV – Diabetic rats treated with extract 250 & 500 mg/kg body weight in respectively.

Group V– Diabetic rats treated with standard drug Glibenclamide 600 μ g/kg body weight

The vehicles and the drugs were administered orally using

oral gavage tube daily for three weeks. Blood samples were collected for the measurement of blood glucose level from the tail vein on 0 day, 7th, 14th and 21st day. The blood glucose level was determined by glucometer (sugar scan). The values of sample treated were compared with that of the standard group which was treated with Glibenclamide. Then the animals were sacrificed by cervical dislocation. The liver, kidney and pancreas were exposed and perfused with cold saline phosphate buffer of pH 7.4 for histopathological examination. Blood free liver and kidney were taken out and homogenized in a glass Teflon homogenizer separately (10% w/v). Incubation was done at 37°C under controlled conditions for biochemical estimation. The collected blood samples were immediately centrifuged at 2500 rpm for 15 min. The serum separated was collected in fresh serum tubes and stored in refrigerator (2–4°C) after tightly capped. Effect of test extracts on serum glucose, antioxidant enzymes and lipid profile were assessed.

2.8. In-vivo antioxidant activity in diabetic rats

Measurement of Catalase (CAT), Superoxide dismutase (SOD), Glutathione γ -S-transferase (GST), Reduced glutathione (GSH) and Glutathione peroxidase (GPx) were determined for ascertain its antioxidant activity by standard procedure of Pari [16]

2.9. Histopathology

At the end of the treatment period the control as well as treated rats were sacrificed by using cervical dislocation and the pancreas was dissected out and part of pancreatic tissue was immediately fixed in bouin's fluid for 24 hr and washed in running tap water to remove colour of bouin's fluid and dehydrated in alcohol in ascending and descending order, embedded in paraffin and cut at 5 μ m in a rotary microtome.

These sections were then deparaffinized in xylene and stained with hematoxylin–eosin and mounted with canada balsam. The histopathological slides were examined and photographs were captured with a digital stereomicroscope (Olympus, B061) [17].

2.10. Statistical analysis

The statistical analysis of all the pharmacological analysis was carried out using GraphPad Prim version 3.03 for windows. The values are represented as mean \pm S. D. for six rats data were analyzed by Student t test and ANOVA with post-hoc difference was analysed using Newman–keuls method.

3. Results

3.1. Preliminary phytochemical screening

Preliminary phytochemical screening revealed the presence of carbohydrate, phenolic compounds, phytosterols, alkaloids and flavonoids in 50% ethanolic extract of leaves.

3.2. Antihyperglycemic activity

Table 1 shows the effect of oral administration of 250 mg/kg & 500 mg/kg of ASEt on serum glucose level in 21 days, at the end of the treatment, reduction in serum glucose level in treated rats with dose 500 mg/kg was 57.93% and 250mg/kg was 50.49%. The difference in percentage reduction of serum glucose level of different groups are significantly ($p < 0.001$). Table 2 shows that ASEt (500 mg/kg) again had potent effect on the lipid profile of the diabetic rats by significant decreasing the total lipid (90.83 \pm 4.21 mg/dl as compared to diabetic control 148.83 \pm 4.29 mg/dl) ($P < 0.001$), cholesterol

Table 1.

Effect of 50% ethanolic extract of *A. spinosus* on serum glucose level in STZ – Nicotinamide induced diabetic rats

Groups	Treatment/Dose	0 day (mg/dl)	After 7 days (mg/dl)	After 14 days (mg/dl)	After 21 days (mg/dl)
I	Normal control	78.3 \pm 11.97	77.13 \pm 11.32	76.03 \pm 11.27	74.93 \pm 10.77
II	Diabetic control	236.35 \pm 29.05 z	231.33 \pm 29.61 z	227.81 \pm 31.59z	222.35 \pm 22.92z
III	ASEt (250 mg/kg)	219.88 \pm 13.36	191.18 \pm 15.32	164.66 \pm 19.65a	117.01 \pm 19.37c
IV	ASEt (500 mg/kg)	235.5 \pm 18.26	191.06 \pm 17.02	131.56 \pm 18.88b	99.41 \pm 10.66c
V	Glibenclamide(600 μ g/kg)	233.56 \pm 13.40	186.06 \pm 12.76	134.51 \pm 8.21b	94.68 \pm 5.37c

The value represents the means \pm S.D. for 6 rats per group. a $P < 0.05$, b $P < 0.01$ and c $P < 0.001$ compared to diabetic control group. z $P < 0.001$ as compared to normal group.

Table 2.

Effects of 50% ethanolic extract of *A. spinosus* (ASEt) on the total cholesterol, triglyceride and lipid level in blood serum after 21 days

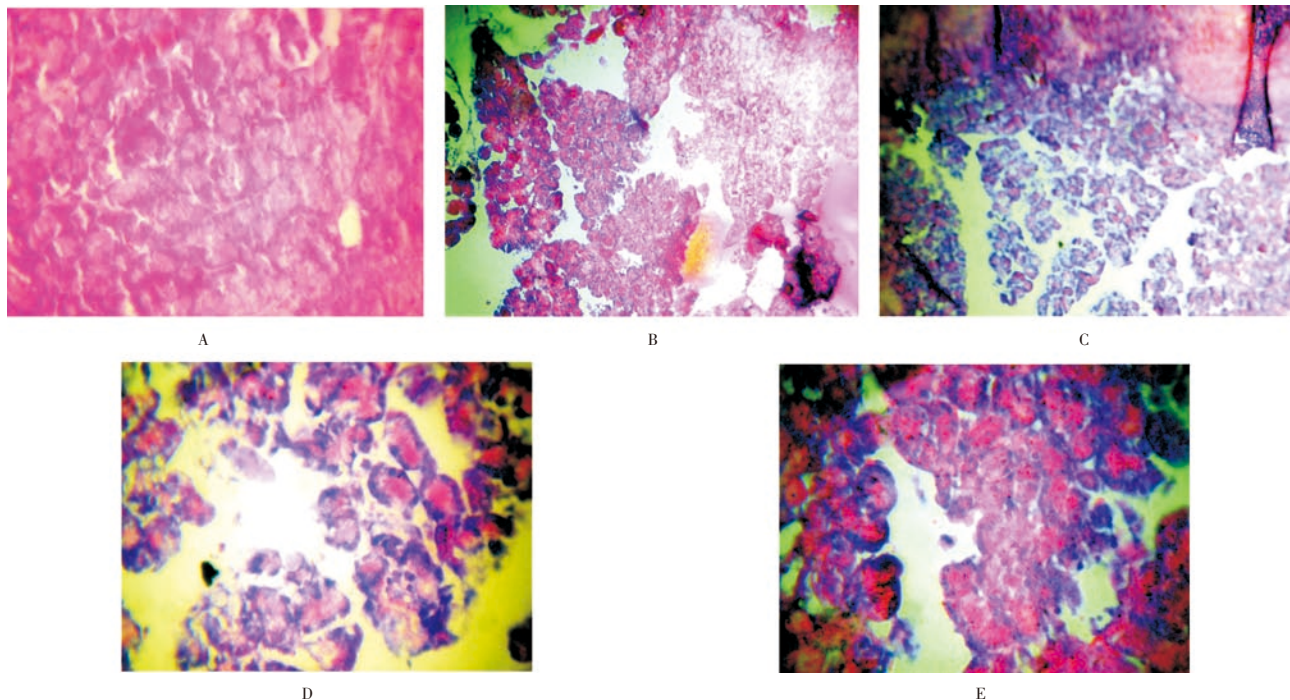
Groups	Treatment/ Dose	Triglyceride(mg/dl)	Total cholesterol(mg/dl)	Total lipids (mg/dl)
I	Normal control	70.16 \pm 4.81	72.83 \pm 4.74	84.83 \pm 5.14
II	Diabetic control	115.66 \pm 3.94z	153.66 \pm 5.24 z	148.83 \pm 4.29 z
III	ASEt (250 mg/kg)	72.33 \pm 4.74 c	77.33 \pm 6.34 c	113.5 \pm 3.98c
IV	ASEt (500 mg/kg)	67.83 \pm 3.67 c	72.16 \pm 2.96 c	90.83 \pm 4.21 c
V	Glibenclamide(600 μ g/kg)	75.66 \pm 4.92 c	81.83 \pm 7.77 c	93.33 \pm 5.73 c

The value represents the means \pm S.D. for 6 rats per group. c $P < 0.001$ compared to diabetic control group. z $P < 0.001$ as compared to normal group.

Table 3.Effect of *A. spinosus* extract on antioxidant enzyme activities in STZ–nicotinamide diabetic rats

Parameters	GSH (nM of DTNB conjugated / mg protein)	GST (μ mol of CDNB–GSH conjugate formed/ min/ mg protein)	GPx (μ g glutathione consumed/ min/ mg protein)	CAT (μ mol of H ₂ O ₂ consumed/ min/ mg protein)	SOD (U min/ mg/ Hb) Erythrocytes
Normal control					
Liver	132.12 \pm 2.24	6.89 \pm 0.84	8.98 \pm 0.57	72.36 \pm 1.87	6.52 \pm 0.24
Kidney	120.54 \pm 3.18	6.75 \pm 0.34	7.54 \pm 0.48	39.56 \pm 1.35	
Diabetic control					
Liver	77.28 \pm 3.54z	3.52 \pm 0.14 z	5.32 \pm 0.48y	39.64 \pm 2.12z	3.32 \pm 0.62y
Kidney	45.32 \pm 2.58	2.42 \pm 0.28 z	5.12 \pm 1.25	21.81 \pm 1.42z	
ASEt treated (250mg/ kg)					
Liver	112.45 \pm 3.87a	5.54 \pm 0.84b	6.08 \pm 0.54b	62.56 \pm 3.12b	5.25 \pm 0.84b
Kidney	94.12 \pm 3.59	4.42 \pm 0.46a	6.12 \pm 0.42	28.42 \pm 1.26a	
ASEt treated (500mg/ kg)					
Liver	129.42 \pm 2.36c	6.42 \pm 0.48c	8.72 \pm 0.65c	71.22 \pm 2.15c	6.36 \pm 0.43c
Kidney	102.84 \pm 2.54	6.02 \pm 0.38b	7.32 \pm 0.58c	37.20 \pm 1.52c	
Glibenclamide treated (600 μ g/kg)					
Liver	124.78 \pm 2.42c	5.28 \pm 0.56b	7.10 \pm 0.21b	64.24 \pm 2.45c	4.28 \pm 0.24b
Kidney	88.18 \pm 3.45	4.08 \pm 0.84b	5.58 \pm 0.25a	36.32 \pm 1.54c	

The values represent the means \pm S. D. for six rats per group. *aP*<0.05, *bP*<0.01 and *cP*<0.001 compared to diabetic control group. *yP*<0.01, *zP*<0.001 as compared to normal; SOD: superoxide dismutase; GSH: Glutathione; GPx: glutathione peroxidase; GST: glutathione–S–transferase; CAT: Catalase.

**Figure 1.** Histopathology of pancreas

(72.16 – 2.96 mg/ dl as compared to diabetic control 153.66 – 5.24 mg/ dl) (*P*< 0.001) and triglycerides level (67.83 –3.67 mg/ dl as compared to diabetic control 115.66 –3.94) (*P*< 0.001).

3.3 In vivo antioxidant activity

The activities of GPx and GST were observed to decrease significantly in diabetic rats. The activities of enzymatic and levels of non–enzymatic antioxidant were significantly decreased in diabetic rats. After 21 days treatment with 500mg/kg of ASEt significantly increased GPx level (8.72 –0.65 in liver (*P*<0.001) and 7.32 –0.58 in kidney (*P*<0.01)) than diabetic control (5.32 –0.14 in liver and 5.12 –1.25 in kidney). After oral administration of ASEt significantly increase the

level of SOD in erythrocytes, CAT & GSH in both liver and kidney at higher doses 500 mg/kg (*P*<0.001) as compared to diabetic control rats. (Table 3).

3.4. Histopathological studies

Microscopically examined pancreas section of control group (Figure 1A) showed Islets are normal. The architecture is preserved. The acini are lined by round to oval cells with moderate cytoplasm and small round to oval nuclei where as in diabetic control group (Figure 1B) Islets shows depletion of cells. The architecture is preserved. The acini are lined

by round to oval cells with moderate cytoplasm and small round to oval nuclei. In case of extract 250 mg/kg treated group (Figure 1C) the architecture is partially effaced. The islets are normal. The acinar cells are normal. There is a mild and diffuse infiltrate of lymphocytes within the stroma. 50% ethanolic extract 500 mg/kg treated group (Figure 1D), the architecture is normal. The islets show depletion of the acinar cell. The acinar cells show moderate cytoplasm and round to oval nuclei. There is no evidence of inflammation while in standard treated group (Figure 1E), there is mild infiltrate of lymphocytes at some foci. The acini are lined by round to oval cells with moderate cytoplasm and small round to oval nuclei.

4. Discussion

Type II diabetes is characterized by a progressive loss of β -cell function and oxidative stress that results in deterioration of glucose control, which increases the incidence of diabetes related complications. More than 60% of the world's population with diabetes will come from Asia, because it remains the world's most populous region [18]. The oxidative stress, a key factor in the progression and development of diabetes and its late-complications, is mediated through the diabetogenic action of streptozotocin as well as chronic hyperglycemia. Administration of the diabetogenic dose of STZ to rats causes a decrease in body weight; however, this is attenuated by pretreatment of animals with nicotinamide [19–20]. Numerous studies have also demonstrated that the STZ-induced increase in blood glucose is significantly blunted when nicotinamide is administered prior to STZ. The advantageous effect of NA on blood glucose is due to the protection of B-cells against STZ-induced injury and is accompanied by increased blood insulin [21–22]. Secondary metabolites like alkaloid, flavonoid and saponins suppressed the glucose level, reduced plasma cholesterol and triglycerides significantly and increased their hepatic glucokinase activity probably by enhancing the insulin release from pancreatic islets [23]. The 50% ethanolic extracts have been chosen because of its expected flavonoid, alkaloid contents that were reported to have antidiabetic activity. In the present study, STZ treatment caused a significant depletion of both non-enzymatic and enzymatic antioxidants of liver and kidney tissues [24]. SOD is an enzymatic antioxidant which reduces superoxide radical to hydrogen peroxide, CAT in turn involved in the reduction of hydrogen peroxide. A decrease in the activities of these antioxidant enzymes in tissues can lead to the formation of superoxide anion and hydrogen peroxide which can later form hydroxyl radical. GSH-metabolizing enzymes, GPx and GST work in concert with glutathione in the decomposition of hydrogen peroxide and other organic hydroperoxides to non-toxic products, respectively, at the expense of reduced glutathione. Reduced activities of GPx and GST observed

were due to inactivation of these enzymes by reactive oxygen species. Treatment with *A. spinosus* showed increased activities of enzymatic antioxidants, which might be due to the presence of flavonoids. Flavonoids present in the leaf-extract scavenge the free radicals generated during diabetes, as they are well known for their antioxidant properties.[25] GSH, a major endogenous antioxidative agent, involve in the conjugation of several types of compounds, protect cells from toxic effects and maintain the cellular redox status. In the present study, the decrease in GSH level in tissues is due to increased utilization by tissues or due to decreased synthesis and increased degradation of GSH by oxidative stress. The observed decrease in the concentration of GSH in the diabetic liver and kidney is consistent with earlier report [26]. Oral administration of *A. spinosus* increased the GSH levels in diabetic rats, might be due to inhibition of lipid peroxidation process. The structure of diabetic pancreas showed considerable reduction in the islets langerhans and depleted islets. After the administration of extract, the pancreatic cells showed average appearance same as normal control group. All the above observations suggest that *A. spinosus* can be a promising antidiabetic and antioxidant drug.

As a conclusion, it could be cogitated that the observed antihyperglycemic activity of *Amaranthus spinosus* leaves might be related to the presence of flavonoids, sterols and alkaloids as active constituents. The current analysis has also opened a path for further research especially with reference to the development of potent herbal formulation for diabetes mellitus from *Amaranthus spinosus* leaves.

Conflict of interest statement

We declare that we have no conflict of interest.

Acknowledgement

The authors sincerely thank United Institute of Pharmacy, Allahabad, for providing all the animal house facilities to carryout clinical studies and acknowledge funding support from the Department of Pharmacognosy UIP, 6103-11-P-003, UCER Fund Support.

References

- [1] Jin L, Xue HY, Jin LJ, Li SY, Xu YP: Antioxidant and pancreas-protective effect of aucubin on rats with streptozotocin-induced diabetes. *Eur J Pharmacol* 2008; **582**: 162–167.
- [2] Levine JH: Managing multiple cardiovascular risk factors: state of the science. *J Clin Hypertens (Greenwich)* 2006; **8**: 12–22.
- [3] Araki T, Emoto M, Konishi T, Ikuno Y, Lee E, Teramura M, et al. Glimepiride increases high-density lipoprotein cholesterol

- via increasing adiponectin levels in type 2 diabetes mellitus. *Metabolism* 2009; **58**: 143–148.
- [4] Kirtikar KR, Basu BD. Indian Medicinal Plants, vol. 9, 2nd ed. Oriental Enterprises, Rajpur, Dehradun, Uttaranchal, India, 2001, p. 2832–2836
- [5] Hussain Z, Amresh G, Rao ChV, Singh S. Antinociceptive activity of *Amaranthus spinosus* in experimental animals. *J Ethnopharmacol* 2009; **122**:492–496
- [6] Olufemi BE, Assiak IE, Ayoade GO, Onigemo MA. Studies on the effects of *Amaranthus spinosus* leaf extract on the hematology of growing pigs. *Afr J Biomed Res* 2003; **6**: 149–150.
- [7] Tatiya AU, Surana SJ, Khope SD, Gokhale SB, Sutar MP. Phytochemical investigation and immunomodulatory activity of *Amaranthus spinosus* Linn. *Indian J Pharm Edu Res* 2007; **44**: 337–341.
- [8] Assiak IE, Olufemi BE, Ayonde GO, Onigemo MA. Preliminary studies on the effects of *Amaranthus spinosus* leaf extract as an Anthelmintic in growing pigs. *Trop Vet* 2002; **20**: 126–129.
- [9] Sangameswaran B, Jayakar B. Anti-diabetic, anti-hyperlipidemic and spermatogenic effects of *Amaranthus spinosus* Linn. On streptozotocin-induced diabetic rats. *J Nat Med* 2008; **62**:79–82
- [10] Girija K, Lakshman K. Anti-hyperlipidemic activity of methanol extracts of three plants of Amaranthus in triton-WR 1339 induced hyperlipidemic rats. *Asian Pac J Trop Biomed* 2011; **1**: s62–s65
- [11] Odhava B, Beekrumb S, Akulaa U, Baijnath H. Preliminary assessment of nutritional value of traditional leafy vegetables in KwaZulu-Natal, South Africa. *J Food Compos Anal* 2007; **20**: 430–435
- [12] Barminas T, Charles M, Emmanuel D. Mineral composition of nonconventional leafy vegetables. *Plant Foods Hum Nutri* 1998; **53**: 29–36
- [13] Kokate CK, Purohit AP, Gokhale SB. Pharmacognosy. Nirali prakashan, Fortieth edition, 2008, p. 607–611
- [14] OECD. Guidelines number 423 for the testing of chemicals revised draft guideline 423 (acute oral toxicity). Paris: OECD; 2000.
- [15] Shirwaikar A, Rajendran K, Punitha ISR. Antidiabetic activity of alcoholic stem extract of *Coscinium fenestratum* in streptozotocin–nicotinamide induced type 2 diabetic rats. *J Ethnopharmacol* 2005; **97**: 369–374
- [16] Pari L, Murugan P. Antioxidant effect of tetrahydrocurcumin in streptozotocin–nicotinamide induced diabetic rats. *Life Sci* 2006; **79**: 1720–1728
- [17] Culling C.F.A. Handbook of histopathological and histochemical techniques. 3rd ed., Butterworth & Co. (Publishers) Ltd. London, 1974; p. 194–196
- [18] Chan JC. Diabetes in Asia, Epidemiology, risk factors, and pathophysiology. *JAMA* 2009; **301**: 2129–2140
- [19] Li F, Chong ZZ, Maiese K. Cell life versus cell longevity: the mysteries surrounding the NADP precursor nicotinamide. *Curr Med Chem* 2006;**13**:883–95
- [20] Maiese K, Chong ZZ, Hou J, Shang YC. The vitamin nicotinamide: translating nutrition into clinical care. *Molecules* 2009; **14**: 3446–85
- [21] Su HC, Hung LM, Chen JK. Resveratrol, a red wine antioxidant, possesses an insulin-like effect in streptozotocin-induced diabetic rats. *Am J Physiol Endocrinol Metab* 2006; **290**: 1339–46
- [22] Chi TC, Chen WP, Chi TL, Kuo TF, Lee SS, Cheng JT, Su MJ. Phosphatidylinositol-3-kinase is involved in the antihyperglycemic effect induced by resveratrol in streptozotocin-induced diabetic rats. *Life Sci* 2007; **80**: 1713–20
- [23] Mishra SB, Rao Ch V, Ojha SK, Vijayakumar M, Verma A. An analytical review of plants for anti diabetic activity with their phytoconstituent & mechanism of action. *Int J Pharm Sci Res* 2010; **1**: 29–46
- [24] Ramesh B, Pugalendi KV. Antioxidant role of umbelliferone in STZ diabetic rats. *Life Sci* 2006; **79**: 306–310.
- [25] Coskum O, Kanter M, Oter S. Quercetin, a flavonoid antioxidant, prevents and protects the streptozotocin-induced oxidative stress and b-cell damage in rat pancreas. *Pharmacol Res* 2005; **51**: 117–123.
- [26] Darlin Quine S, Pamakanthan SR. Effects of (–)-epicatechin, a flavonoid on lipid peroxidation and antioxidants in streptozotocin-induced diabetic liver, kidney and heart. *Pharmacol Reports* 2005; **57**: 610–615