




Contents lists available at ScienceDirect

## Asian Pacific Journal of Tropical Biomedicine

journal homepage: [www.elsevier.com/locate/apjtb](http://www.elsevier.com/locate/apjtb)

Document heading doi:10.1016/S2221-1691(12)60102-6 © 2012 by the Asian Pacific Journal of Tropical Biomedicine. All rights reserved.

# Bilateral atypical optic neuritis associated with tuberculosis in an immunocompromised patient

Juanarita Jaafar, Wan Hazabbah Wan Hitam\*, Raja Azmi Mohd Noor

Department of Ophthalmology, School of Medical Sciences, Health Campus, Universiti Sains Malaysia, Kota Bharu, Kelantan, Malaysia

## ARTICLE INFO

*Article history:*

Received 15 November 2011

Received in revised form 2 December 2011

Accepted 23 February 2011

Available online 28 July 2012

*Keywords:*

Tuberculosis

Optic neuritis

Funduscopy

## ABSTRACT

A 27 year-old lady, presented with sudden loss of vision in the right eye for a week. It was followed by poor vision in the left eye after 3 days. It involved the whole entire visual field and was associated with pain on eye movement. She was diagnosed to have miliary tuberculosis and retroviral disease 4 months ago. She was started on anti-TB since then but defaulted highly active anti-retroviral therapy (HAART). On examination, her visual acuity was no perception of light in the right eye and 6/120 (pinhole 3/60) in the left eye. Anterior segment in both eyes was unremarkable. Funduscopy showed bilateral optic disc swelling with presence of multiple foci of choroiditis in the peripheral retina. The vitreous and retinal vessels were normal. Chest radiography was normal. CT scan of orbit and brain revealed bilateral enhancement of the optic nerve sheath that suggest the diagnosis of bilateral atypical optic neuritis. This patient was managed with infectious disease team. She was started on HAART and anti-TB treatment was continued. She completed anti-TB treatment after 9 months without any serious side effects. During follow up the visual acuity in both eyes was not improved. However, funduscopy showed resolving of disc swelling and choroiditis following treatment.

## 1. Introduction

Tuberculosis (TB) is now considered the most important opportunistic infection in HIV[1,2]. It primarily affects the lungs but the proportion of cases with extrapulmonary tuberculosis has increased in recent years in immunocompromised individuals especially in children and females[3]. Extrapulmonary involvement is seen in more than 50% of the patients who have both AIDS and tuberculosis. The risk of extrapulmonary tuberculosis was higher in patients with low CD4+ counts: 70% of the patients with CD4+ counts of less than 100 develop extrapulmonary disease compared to 28% with CD4+ counts of more than 300[3].

Tuberculosis may affect all ocular tissues; choroiditis[4] and retinal periphlebitis[5] being the most common ocular manifestations. Loss of vision is well documented as sequelae of TB[6]. This occurs in cases of involvement of the optic nerve and optic chiasma by tuberculomas in miliary TB and opticochiasmatic arachnoiditis[6]. We report a rare

case of bilateral atypical optic neuritis associated with TB in an immunocompromised patient.

## 2. Case report

A 27 year-old lady, presented with sudden onset profound loss of vision for one week in the right eye. It was followed by similar presentation in the left eye after 3 days. It involved the whole entire visual field and was associated with pain on eye movement.

The patient was diagnosed to have miliary tuberculosis and retroviral disease 4 months ago. She was unemployed and had history of sexual promiscuity at the age of 17 years old. She was previously well until four months ago when she experienced shortness of breath and lethargy. She was admitted to medical ward and worked up for atypical pneumonia. Chest x-ray was suggestive of miliary TB. Mantoux test was positive. She was started on an initial high-intensity phase anti-TB regimes. She was also screened for her immune status and found to be retroviral positive with CD4+ count of 10. She was referred to infectious unit for supportive management of HAART. However, she was defaulted the appointment and only continued taking anti-TB from the nearest clinic.

\*Corresponding author: Wan Hazabbah Wan Hitam, Associate Professor & Head, Department of Ophthalmology, School of Medical Sciences, Health Campus, Universiti Sains Malaysia, 16150 Kubang Kerian, Kelantan, Malaysia.

Tel: +609-767 6363/6361

Fax: +609-765 3370

E-mail: [hazabbah@kb.usm.my](mailto:hazabbah@kb.usm.my)

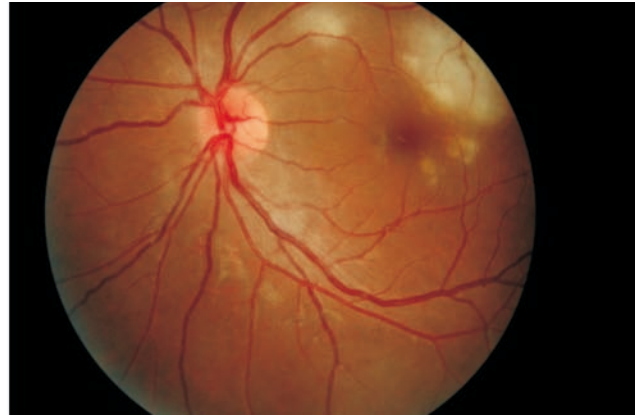
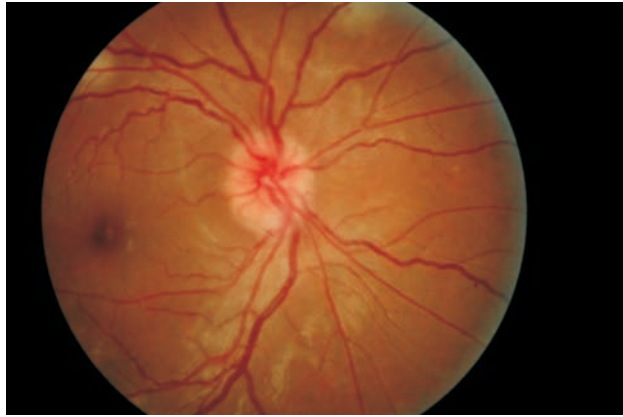
She was given high-intensity phase anti-TB drugs for 2 months. Later, she was given maintenance regimes. She presented with eye symptoms about 2 months after the maintenance regimes were started.

On presentation, her visual acuity was no light perception in the right eye and 6/120 (pinhole 3/60) in the left eye. Anterior segment in both eyes was unremarkable. Funduscopy showed bilateral optic disc swelling (Figure 1) and presence of multiple foci of choroiditis at peripheral retina (Figure 2). The vitreous and retinal vessels appeared normal. The patient looked lethargic, not tachypneic. There was no lymphadenopathy and organomegaly.

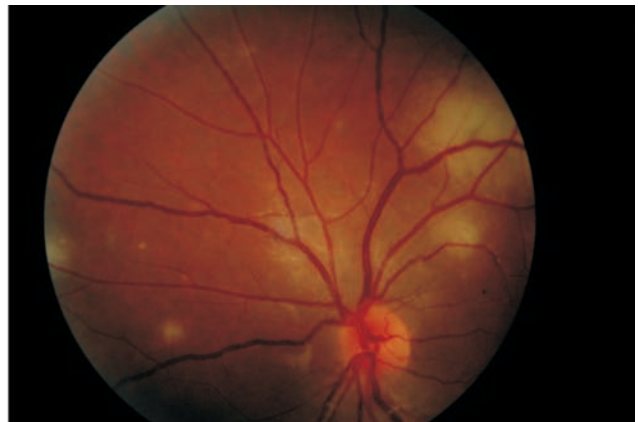
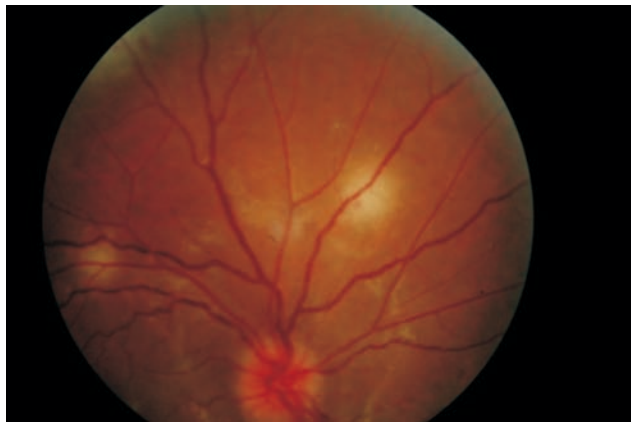
The laboratory results revealed very low white cells 2.33g/dL and normal haemoglobin of 11.8g/dl. Her erythrocyte sedimentation rate (ESR) was slightly elevated of 42 mm/h. Rheumatoid factor (RhF) and antinuclear antibody (ANA) was

negative. VDRL was negative. CMV, toxoplasma and herpes serology were negative. Blood and urine cultures showed no growth. Renal and liver function tests were normal. CT scan of orbit showed bilateral enhancement of the optic nerve sheath that confirm the diagnosis of bilateral atypical perineuritis (Figure 3). The brain parenchymal was normal.

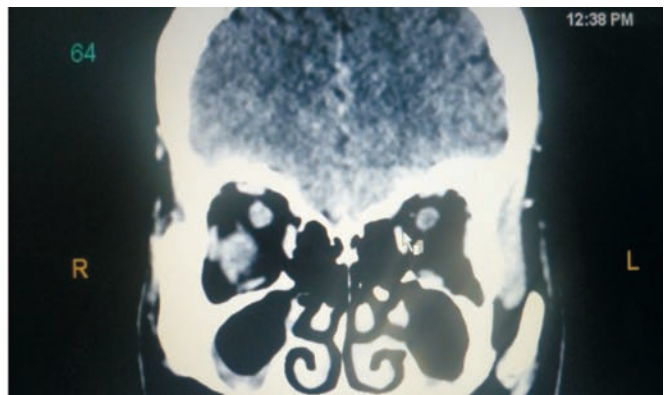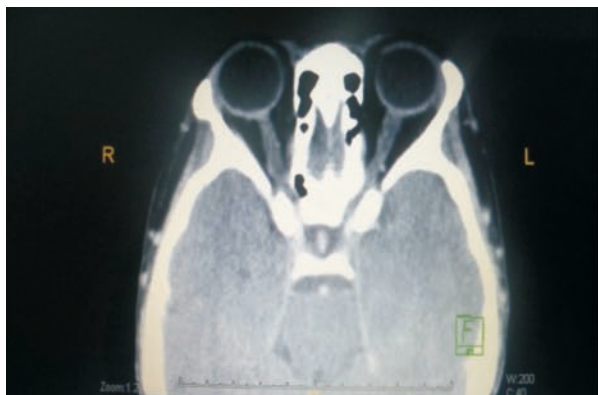
She was referred to infectious disease unit again for initiation of HAART and also continuing anti-TB treatment (Isoniazid, Ethambutol, Rifampicin, Pyrazinamide and Pyridoxine) for another 2 months. No steroid was started. Patient showed significant improvement with the treatment given. Funduscopy examination showed resolving of disc swelling and choroiditis changes following treatment. However, visual acuity in both eyes showed no improvement.



**Figure 1.** Fundus photographs showed bilateral eye disc swelling.



**Figure 2.** Fundus photographs showed multiple foci of choroiditis in the peripheral retina in both eyes.



**Figure 3.** CT scan of orbit and brain bilateral enhancement of the optic nerve sheath.

### 3. Discussion

Optic neuritis (ON) is an inflammation of optic nerve. It can be divided into two forms: 'typical' and 'atypical'. Typical optic neuritis is unfortunately not treatable, but fortunately it is usually benign. By contrast, atypical optic neuritis is often treatable and is usually not benign. This is why, it is so important to distinguish between the two<sup>[4]</sup>.

Acute idiopathic ON is the most common cause of optic neuropathy in young patients<sup>[7]</sup>, with a peak of incidence in the third and fourth decade<sup>[7,8]</sup>. In ONTT, the mean age was 32<sup>[8]</sup>. It is an isolated inflammatory optic neuropathy secondary to demyelination. It represents typical form of ON. Atypical optic neuritis warrants for other cause of ON such as infection, malignancy, immunosuppression, autoimmune or inflammatory conditions<sup>[7]</sup>.

The diagnosis of demyelinating ON is usually made clinically, although imaging of the optic nerves, preferably by magnetic resonance imaging (MRI), is mandatory for atypical cases<sup>[7]</sup>. MRI of the brain can also yield prognostic information in terms of the patient's future risk of multiple sclerosis (MS) and it may be repeated over time because the most recent criteria for diagnosis of MS incorporate the presence of MRI findings<sup>[8]</sup>.

The classic triad of ON consists of loss of vision, periocular pain and dyschromatopsia, and is unilateral in 70% of adults. The typical clinical course is that of retro-orbital pain usually exacerbated by eye movement, and loss of central vision. Visual loss varies from mild reduction to no perception of light and progresses over 7–10 days before reaching a nadir. Periocular pain occurs in more than 90% of cases, may precede or coincide with the visual symptoms and usually resolves over days. All patients show reduced contrast sensitivity and dyschromatopsia, which are often out of proportion to the visual acuity deficit<sup>[9]</sup>.

Atypical ON presents with bilateral reduction in vision. Vision loss is continuing to progress more than 2 weeks after onset and no recovery by 5 weeks after onset. Pain is usually absent, or severe enough to disturb sleep or restrict eye movements, or pain persisting more than 2 weeks after onset, or pain following onset of vision loss<sup>[7]</sup>. As for our patient, she presented with bilateral loss of vision associated with pain on eye movement and showed no recovery of vision despite marked improvement of posterior segment findings.

In typical ON, central scotoma is a common field defect. Purvin et al reported that in their patients with atypical ON, most of the visual field loss involved the paracentral and the arcuate area and are more likely to show sparing of central vision<sup>[9]</sup>. Response to corticosteroids is more dramatic than in patients with typical optic neuritis. Purvin et al found that, out of 14 patients with atypical ON, 12 were treated with corticosteroids, and all demonstrated dramatic relief of pain on initiating treatment, typically within hours and all within a day. Visual loss also showed prompt recovery. Relapse following discontinuation of treatment, however, was common<sup>[9]</sup>.

A patient with bilateral atypical ON, described by Margo et al, did not experience a beneficial response to corticosteroids<sup>[10]</sup>. Whereas, Maria et al found that high-dose steroid therapy may be effective for atypical ON in patients without optic nerve atrophy, even if initial treatment has failed or initiation of therapy was delayed<sup>[11]</sup>. As for our patient, she had underlying TB infection and in

immunocompromised state with right eye vision of NPL, we did not start her on corticosteroid but continue anti-TB and HAART. Masaud et al were inhibited from using corticosteroid in patient with possibility of an atypical mycobacterium with multiple drug resistance and in patient already immunocompromised<sup>[12]</sup>.

The prognosis for visual outcome in patients with atypical ON is generally excellent. This is greatly influenced, however, by the interval between the onset of visual loss and the initiation of treatment. Purvin et al found in their series, in 2 patients with a poor visual outcome, treatment was delayed by a month or more<sup>[9]</sup>. The other factor that influences prognosis is the frequency of recurrent attacks. Initiating treatment with higher doses of corticosteroids (eg, prednisone, 80 mg/d) and more prolonged treatment at this level appear to lessen the likelihood of recurrent attacks<sup>[8,9]</sup>. Patients with atypical ON, in contrast, are not at increased risk for demyelinating disease but are likely to experience a recurrence of visual loss in the future<sup>[9]</sup>.

Bilateral atypical optic neuritis secondary to tuberculosis is a rare presentation and should be considered in an immunocompromised patient.

### Conflict of interest statement

We declare that we have no conflict of interest.

### References

- [1] Oathokwa N, Dintle T. Ocular Complications of HIV Infection in Sub-Saharan Africa. *Current HIV/AIDS Reports* 2008; **5**:120–125.
- [2] Al-Fraikh H, Al-Dahmash S. Rare presentation of definitive ocular tuberculosis in an immunocompetent young patient. *Saudi J Ophthalmol* 2010; **24**: 31–33.
- [3] Gupta V, Gupta A and Rao NA. Intraocular tuberculosis – An Update. *Surv Ophthalmol* 2007; **52**: 561–587.
- [4] Biswas J. Ocular Tuberculosis – An update. *Kerala J Ophthalmol* 2009; **21**(4): 351–357.
- [5] Suzuki J, Oh-I K, Kezuka T, Sakai JI, Goto H. Comparison of Patients with Ocular Tuberculosis in the 1990s and the 2000s. *Jpn J Ophthalmol* 2010; **54**:19–23.
- [6] Souvik M, Moumita S, Mihir S, Sukanta C. Isolated demyelinating optic neuritis in neurotuberculosis [Online]. Available from: <http://www.paediatricconcall.com/fordocor/casereports/neuritis.asp> [Accessed on 11th December 2011].
- [7] Shams PN, Plant GT. Optic neuritis: A review. *The Int MS J* 2009; **16**: 82–89.
- [8] Murphy MA. Clinical update on optic neuritis and multiple sclerosis. *Med and Health J* 2008; **91**(2): 57–59.
- [9] Valerie Purvin, Aki Kawasaki, Daniel M Jacobson. Optic perineuritis: clinical and radiographic features. *Arch Ophthalmol* 2001; **119**: 1299–1306.
- [10] Margo CE, Levy MH, Beck RW. Bilateral idiopathic inflammation of the optic nerve sheaths: Light and electron microscopic findings. *Ophthalmology* 1989; **96**(2): 200–206.
- [11] Maria Tatsugawa, Hidetaka Noma, Tatsuya Mimura, Hideharu Funatsu. High-dose steroid therapy for idiopathic optic perineuritis: a case series. *J Med Case Report* 2010; **4**:404.
- [12] Masaud T, Kerp E. Corticosteroids in Treatment of Disseminated Tuberculosis in a Patient with HIV Infection. *BMJ* 1988; **296**: 464–465.