

## A STUDY OF THE BIFURCATION OF SCIATIC NERVE AND ITS CLINICAL IMPORTANCE

S.Dhivya \*, Kalai Anbusudar.

Assistant Professor of Anatomy, Government Mohan Kumaramangalam Medical College, Salem, Tamil Nadu, India.

### ABSTRACT

**Background:** The sciatic nerve, the principal nerve of the posterior compartment of the lower limb normally divides at the superior angle of popliteal fossa. Sometimes there could be higher division, the knowledge of which is important in avoiding inadvertent injury during surgeries in the gluteal region.

**Materials and Method:** The study was conducted in 64 lower limbs at Government Stanley Medical College, Chennai and Government Mohan Kumaramangalam Medical College, Salem.

**Results:** In 60 limbs, the sciatic nerve divided at superior angle of popliteal fossa. In 3 limbs, there was higher division at the level of upper part of the thigh. In 1 limb, there was intrapelvic division of nerve with split piriformis.

**Conclusion:** Knowledge of these variations help during popliteal nerve blocks and in the management of nondiscogenic causes of sciatica.

**KEY WORDS:** Tibial Nerve, Common Peroneal Nerve, Sciatica, Piriformis syndrome, Popliteal block

**Address for Correspondence:** Dr.S.Dhivya. M.D., Assistant Professor of Anatomy, Government Mohan Kumaramangalam Medical College, Salem-636 030, Tamil Nadu, India.

Mobile No: 9003558900. **E-Mail:** drsdhivya@yahoo.co.in

### Access this Article online

#### Quick Response code



DOI: 10.16965/ijar.2015.345

**Web site:** International Journal of Anatomy and Research  
ISSN 2321-4287  
[www.ijmhr.org/ijar.htm](http://www.ijmhr.org/ijar.htm)

Received: 21 Dec 2015      Accepted: 12 Jan 2016  
Peer Review: 21 Dec 2015      Published (O): 31 Jan 2016  
Revised: None      Published (P): 31 Jan 2016

### INTRODUCTION

Sciatic nerve (SN) is the thickest nerve of body, arising from sacral plexus. Normally it emerges through the greater sciatic foramen, leaves pelvis and enters into gluteal region by passing below piriformis as a single nerve encompassed by a single epineural sheath. It divides subsequently into two terminal nerves i.e., tibial nerve and common fibular nerve (common peroneal nerve, ), usually at superior angle of popliteal fossa. But sometimes it divides high, while still in pelvis into its terminal branches that leave pelvis in a number of ways. Accordingly they are classified into different types in relation to piriformis muscle. The

piriformis is a flat muscle, pyramidal in shape, lying almost parallel to the posterior margin of the gluteus medius. It arises from the front of the sacrum by three fleshy digitations. A few fibers also arise from the margin of the greater sciatic foramen and from the anterior surface of the sacrotuberous ligament. The muscle comes out of the pelvis through the greater sciatic foramen and is inserted by a rounded tendon to the upper border of the greater trochanter [1].

The clinical manifestations of unilateral high division of sciatic nerve ranges from sciatica, injury during deep intramuscular injections, entrapment neuropathy called piriformis

syndrome and failed sciatic nerve block. Knowledge regarding point of bifurcation of sciatic nerve plays a novel role in clinical practice by neurologists, surgeons, anaesthetists and radiologists. The aim of this study is to find the level of division of sciatic nerve and its clinical importance.

**MATERIALS AND METHODS**

The study was a cross sectional one conducted in 32 cadavers (totally 64 lower limbs) in the department of anatomy at Government Stanley medical college, chennai and Government mohankumar amangalam medical college, salem. The cadavers were dissected from the gluteal region to the transverse popliteal crease to expose the nerve and the piriformis muscle to determine the route of exit of the sciatic nerve.

**RESULTS**

The sciatic nerve exited under the piriformis as an undivided nerve and divided at the upper angle of popliteal fossa in 60 lower limbs. (93.75 %)- (Fig. 1) The sciatic nerve divided at the level of upper part of the thigh in 3 lower limbs (4.6%)- (Fig. 2). This high division was observed bilaterally in one cadaver and unilaterally in one cadaver.

In one lower limb (1.5%), Two separate piriformis muscles were present- one superior and the other inferior in position. After proper dissection it was found that the sciatic nerve was divided into common peroneal and tibial nerves within the pelvis. The common peroneal nerve came out between the superior and inferior piriformis muscles but the tibial nerve appeared in the gluteal region below the inferior piriformis muscle (Fig. 3). Those two nerves joined with each other in the lower part of the gluteal region and formed the main trunk of the sciatic nerve again. soon after its

formation, the sciatic nerve divided into common peroneal and tibial nerves (Fig. 4). In the gluteal region two completed separated tendons of the superior and inferior piriformis muscles were visible. A narrow tendon was formed by the lower muscle and was inserted to the posterior-superior angle of greater trochanter of femur. The tendon of the upper muscle was inserted to the posterior part of the upper border of greater trochanter.

Out of four lower limbs with higher division, there were two cadavers with unilateral high division and one cadaver with bilateral high division (Table 1), The cadaver with bilateral high division was a male cadaver. The two cadavers with unilateral high division were both females.

**Table 1:** Showing the variations of sciatic nerve.

Lower limbs with the division of sciatic nerve at the superior angle of popliteal fossa	60
Lower limbs with the division of sciatic nerve at the level of mid thigh Unilaterally-1 Bilaterally-1	3
Lower limb with intrapelvic division of sciatic nerve-unilateral	1
Total lower limbs studied	64

Based on the above observations, we can classify the bifurcation of sciatic nerve into three types:

Type 1: Sciatic nerve emerges as a single trunk below piriformis and divides at the superior angle of popliteal fossa (Fig. 1).

Type 2: Sciatic nerve emerging as a single trunk divides at the level of upper part of the thigh into tibial and common peroneal nerves (Fig. 2).

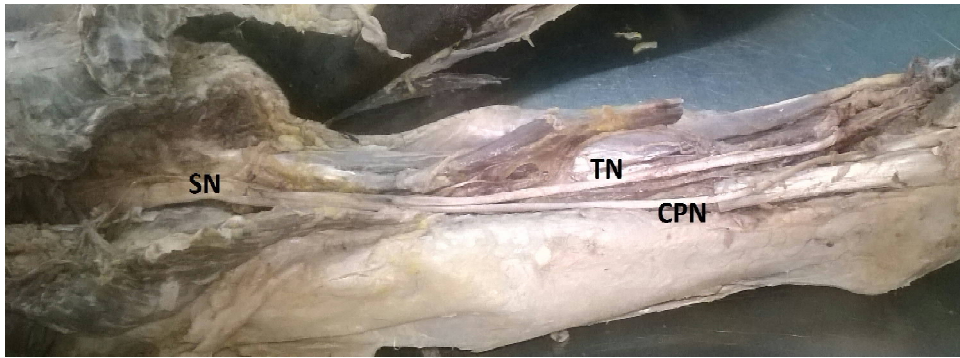
Type 3: intrapelvic division of sciatic nerve with split piriformis ,common peroneal nerve emerging between the two parts of piriformis and tibial nerve below inferior piriformis (Fig. 3).

**Fig. 1:** Showing Sciatic Nerve dividing at superior angle if popliteal fossa.



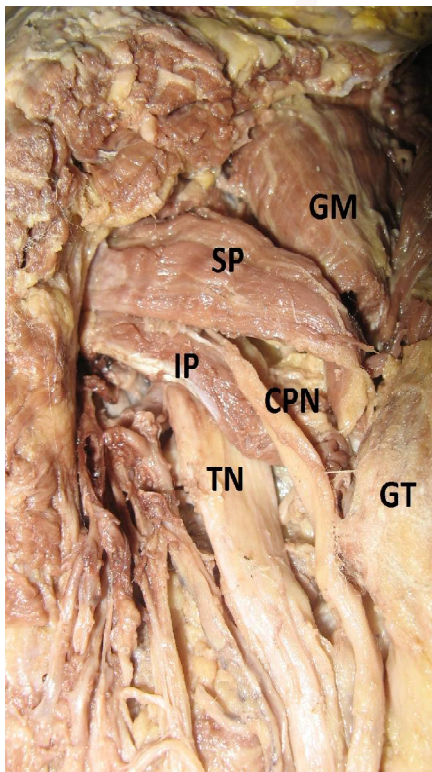
GM- Gluteus Minimus,  
P- Piriformis,  
GT- Greater Trochanter,  
SN- Sciatic Nerve,  
BF- Biceps Femoris,  
TN- Tibial Nerve  
CPN- Common Peroneal Nerve.

**Fig. 2:** Showing Sciatic Nerve division in upper thigh.



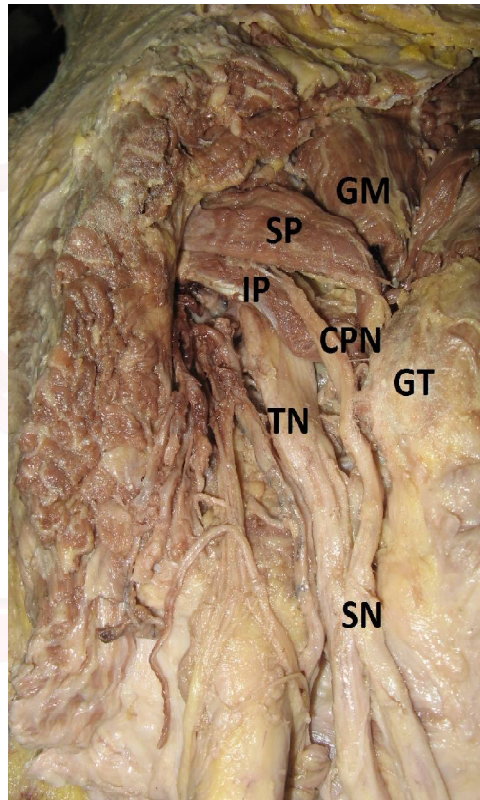
SN- Sciatic Nerve,  
BF- Biceps Femoris,  
TN- Tibial Nerve C  
PN- Common Peroneal Nerve.

**Fig. 3:** Showing split Piriformis, Common Peroneal nerve emerging between the two parts, Tibial nerve below the inferior piriformis.



GM- Gluteus Minimus, SP- Superior Piriformis,  
IP- Inferior Piriformis, GT- Greater Trochanter,  
TN- Tibial Nerve CPN- Common Peroneal Nerve.

**Fig. 4:** Showing the divided nerves uniting to form the main trunk and re dividing again soon.



GM- Gluteus Minimus, SP- Superior Piriformis,  
IP- Inferior Piriformis, GT- Greater Trochanter,  
TN- Tibial Nerve CPN- Common Peroneal Nerve.

## DISCUSSION

During embryological development at the base of the limb bud, the nerves contributing to the lower limb form two plexuses (lumbar and sacral). Later, as the elements from each of these plexuses grow out into the limb, they are subdivided into dorsal and ventral components, for the dorsal and ventral musculatures. The sciatic nerve is formed when the large dorsal component of the sacral plexus (common peroneal nerve) and the ventral component (tibial nerve) move downward close together [2]. Hence, based on their previously mentioned

developmental formation, it is possible that the common peroneal and the tibial divisions of the sciatic nerve separate from each other at different levels from their origins: within pelvis, in the gluteal region, the posterior compartment of the thigh or the popliteal fossa.

Beaton & Anson [3,4] classified variations of the piriformis and SN in 120 specimens in 1937, and in 240 specimens in 1938. Their classification, known as the Beaton & Anson classification, is as follows:

**Type 1:** Undivided nerve below undivided muscle

**Type 2:** Divisions of nerve between and below undivided muscle

**Type 3:** Divisions above and below undivided muscle

**Type 4:** Undivided nerve between heads

**Type 5:** Divisions between and above heads

**Type 6:** Undivided nerve above undivided muscle

In our study, type 1 of the above author was observed in 93.75%. But we encountered split piriformis which was not mentioned by Beaton. Our types 2 and 3 did not fit under any category of Beaton.

Mengistu Desalegn and Amanuel Tesfay [5] in their study in Ethiopia have observed three types of variation in the division of sciatic nerve:

1. Undivided sciatic nerve passes below Piriformis muscle (92 %)
2. Divided sciatic nerve passes above and below Piriformis muscle (5.5%)
3. Divided Sciatic nerve emerges below Piriformis muscle (2.8%). Our observation of type I (93.75%) was similar to type I of their study.

Saritha et al [6] did a study on sciatic nerve. In their study there was a limb with the division of sciatic nerve at the level of ischial tuberosity. Chiranjib Bapuli et al. [7] have come across sciatic nerve dividing in the gluteal region itself. This high division was similar to the observation of ours (type 2). This high division could be the cause for popliteal block failure.

Mustafa Guvencer et al. [8] in their study had encountered in 16% of the limbs, the common peroneal nerve piercing piriformis and tibial nerve running below the muscle. We had in one of the limbs studied a similar finding but the muscle was split in our case.

Machado et al. [9] (100 cases) and Ugrenovic et al., [10] (200 cases) failed to find even a single divided piriformis. Incidentally, Jawish et al., [11] found only one case of divided piriformis among 26 cases selected from 3550 cases complaining of sciatica. Demiryurek et al. [12] also mentioned a case of bilaterally divided piriformis. In our study, we have got a single case of divided piriformis (Type 3).

Ogengo et al. [13] have mentioned the reunion

of tibial and common peroneal nerves in 4.9% of the limbs studied. Our type 3 variant had similar reunion.

These anatomical variations of sciatic nerve can contribute to Piriformis Syndrome and sciatica. In addition to the position of the piriformis muscle there are other causes for sciatica such as a posterior dislocation of the hip joint, herniated disc or pressure from the uterus during pregnancy may damage the nerve roots [14].

Piriformis syndrome is an uncommon and often undiagnosed cause of buttock and leg pain. It may be caused by anatomic abnormalities of the Piriformis muscle and resulting in irritation of the sciatic nerve by the Piriformis muscle [15,16]. The abnormal passage of the sciatic nerve has been attributed to entrapment of sciatic nerve as it exits the greater sciatic notch in the gluteal region. Knowledge of such patterns is also important for surgeons dealing with Piriformis syndrome which affects 5-6% of patients referred for the treatment of back and leg pain [17].

## CONCLUSION

In cases of lower extremity weakness and pain, the possibility of split piriformis causing piriformis syndrome should be taken into account besides sciatica. Imaging methods like CT and MRI can lead to an accurate diagnosis and proper treatment. Persons administering popliteal block should consider in mind the possibility of high division of nerve and possibility of block failure due to that. Hence to avoid that, routine imaging of the limb before the procedure could be done.

**Conflicts of Interests: None**

## REFERENCES

- [1]. Standring S, Mahadevan V, Collins P, Healy JC, Lee J, Niranjana NS, eds. Gray's Anatomy, The Anatomical Basis of Clinical Practice. 40th Ed., Spain, Philadelphia, Churchill Livingstone Elsevier. 2008;1336-1338,1368-1371.
- [2]. Moore KL, Persaud TVN. The Developing Human. 8th ed. Elsevier:2008;368-371
- [3]. Beaton LE, Anson BJ: The relation of the sciatic nerve and its subdivisions to the piriformis muscle. Anat Rec. 1937;70:1-5.

- [4]. Beaton LE: The sciatic nerve and piriform muscle: Their interrelation possible cause of coccygodynia. *J Bone Joint Surgery Am* 1938;20:686-688.
- [5]. Mengistu Desalegn, Amanuel Tesfay .Variations of Sciatic Nerve Its Exit in Relation to Piriformis Muscle in the Northern Ethiopia. *International Journal of Pharma Sciences and Research*.2014;5(12):953-956
- [6]. Saritha S, Praveen Kumar M, Supriya G . Anatomical Variations in the Bifurcation of the Sciatic Nerve, A Cadaveric Study and its Clinical Implications. *Anat Physiol* 2:111.
- [7]. Chiranjib Bapuli et al . *Indian Journal of Basic and Applied Medical Research*; December 2013;3(1):16-20
- [8]. Mustafa Guvencer ,Cihan Yem,nar Akyer,Suleyman Tet,Sait Nader.Variations in the High Division of the Sciatic Nerve and Relationship Between the Sciatic Nerve and the Piriformis. *Turkish Neurosurgery* 2009;19(2):139-144.
- [9]. Machado FA, Babinski MA, Brasil FB, Favorito LA, Abidu-Figueiredo M, Costa MG. Anatomical variations between sciatic nerve and piriform muscle during fetal period in human. *Int J Morphol*. 2003;21:29-35
- [10]. Ugrenoviæ S, Jovanoviæ I, Krstiaæ V, et al. The level of the sciatic nerve division and its relations to the piriform muscle. *Vojnosanit Pregl*. 2005;62:45-9.
- [11]. Jawish RM, Assoum HA, Khamis CF. Anatomical, clinical and electrical observations in piriformis syndrome. *J Orthop Surg Res*. 2010;5:3.
- [12]. Demiryurek D, Bayramoglu A, Erbil M, Aldur MM, Mustafa ES. Bilateral divided piriformis muscle together with the high division of the sciatic nerve. *Gazi Med J*. 2002;13:41-4.
- [13]. J.A.Ogengo,H.El Busaidy et al.Variant anatomy of Sciatic nerve in a black Kenyan population. *Folia Morphol*.2011;70(3):175-179
- [14]. Shailesh P, Mitesh S, Rakesh V, Ankur Z, S P R. A variation in the high division of the sciatic nerve and its relation with piriformis muscle. *National journal of Medical Research*. 2011;1(2).
- [15]. Benzon H.T., Katz J.A., Benzon H.A., Iqbal M.S. Piriformis syndrome: anatomic considerations, a new injection technique, and a review of the literature. *Anesthesiology*. 2003;98(6):1442-8.
- [16]. Moura T.C,Rangelde J.O., Alves M.M. et al. Endoscopic Tenotomy of Piriformis Muscle. *Anatomic Study in Cadaver* 1998.
- [17]. Sharma T., Singla R.K,Lalit M. Bilateral eventration of sciatic nerve. *JNMA, Journal of the Nepal Medical Association*. 2010;50(180):30: 9-12.

**How to cite this article:**

S.Dhivya, Kalai Anbusudar. A STUDY OF THE BIFURCATION OF SCIATIC NERVE AND ITS CLINICAL IMPORTANCE. *Int J Anat Res* 2016;4(1):1828-1832. **DOI:** 10.16965/ijar.2015.345