

Case Report

RIGHT INFERIOR PHRENIC ARTERY AS A BRANCH OF THE RIGHT RENAL ARTERY

Faria L.A.M ¹, Ferreira W.S.M ¹, Almeida D. L ¹, Moraes L.O.C ^{*1,2}.

¹ Department of Morphology, Medical School, Universidade Cidade de São Paulo-São Paulo- Brazil.

² Descriptive and Topographic Anatomy's Discipline, Department of Morphology and Genetic-Universidade Federal de São Paulo-São Paulo-Brazil.

ABSTRACT

The inferior phrenic arteries are involved in many diseases, such as hepatocellular carcinoma, where they are the main vessels responsible for the collateral arterial supply of this type of tumor of hepatic cells which is highly malignant. During a routine dissection a vascular variant was found in the abdominal cavity of a 34-year-old black cadaver whose right inferior phrenic artery (RIPA) derived from the right renal artery. This finding is clinically important since the transcatheter embolization of hepatocellular carcinoma and other hepatic neoplasms, such as hepatoblastoma and capsular adenoma frequently involve studying the root of the RIPA. This way, angiography can be potentially beneficial for knowing how the origins of these vessels vary.

KEY WORDS: Right inferior phrenic artery, Right renal artery, Hepatocellular carcinoma.

Address for Correspondence: Prof. Dr. Luis Otavio Carvalho de Moraes, Descriptive and Topographic Anatomy's Discipline, Department of Morphology and Genetic, Universidade Federal de São Paulo-Escola Paulista de Medicina, Rua Botucatu, 740-Edifício Leitão da Cunha, Vila Clementino-São Paulo-SP-Brazil-04023-900, Phone: (55-11) 5576-4261 extension 25, Fax: (55-11) 5571-7597 **E-Mail:** luisotavio27@yahoo.com.br

Access this Article online

Quick Response code



DOI: 10.16965/ijar.2015.317

Web site: International Journal of Anatomy and Research
ISSN 2321-4287
www.ijmhr.org/ijar.htm

Received: 17 Nov 2015 Accepted: 11 Dec 2015
Peer Review: 17 Nov 2015 Published (O): 31 Jan 2016
Revised: None Published (P): 31 Jan 2016

INTRODUCTION

Most of the textbooks on anatomy offer little information regarding the anatomy and distribution of the inferior phrenic arteries. However, in the last decade, the number of works regarding the inferior phrenic arteries rose substantially because these arteries are involved in many diseases, such as hepatocellular carcinoma. The inferior phrenic arteries are the main vessels responsible for the collateral arterial supply of this type of tumor of the hepatic cells, which is highly malignant [1].

The right inferior phrenic artery (RIPA) and the left inferior phrenic artery (LIPA) irrigate the lower

face of the diaphragm (as seen on figure 1A), and in 40% of the cases, the phrenic arteries derive from the same trunk: 20% derive directly from the aorta; 18% derive from the celiac trunk; 2% derive from the left gastric artery [2,4,6]. In the remainder 60%, the phrenic arteries have different origins and the unusual origins of the RIPA, among them the right renal artery, are included in these 60%, as shown in figure 1B [2,3].

The right inferior phrenic artery, which is close to the dorsal area of the tendinous center of the diaphragm, has two branches, a rising branch and a descending branch. The rising branch divides

divides into a branch that continues laterally (lateral part of the rising branch) supplying the inferior surface of the diaphragm (as shown in figure 3) and a branch that continues ventrally (anterior part of the rising branch) that forms anastomoses with similar vessels in the left side and with the musculophrenic and pericardiophrenic arteries [1]. The descending branch irrigates the diaphragm and passes near the right pillar of this muscle; it forms anastomoses with the posterior inferior intercostal arteries and with the musculophrenic artery; it also has some branches that supply blood to the lower wall of the vena cava.

It was believed that hepatocellular carcinoma was exclusively irrigated by the hepatic arteries [1]. However, collateral arterial supply by the phrenic arteries may start as a consequence of injecting antitumor drugs inside the hepatic arteries, transcatheter embolism or surgical ligation of the hepatic arteries [1,4]. This observation may strongly influence treatment success since most of the blood supply of this tumor is arterial, so it is essential to identify, before clinical intervention, all the arteries feeding this tumor as well as the origin of such arteries [4].

Fig. 1A: Right inferior phrenic artery (RIPA) deriving from the right renal artery to the diaphragm muscle.

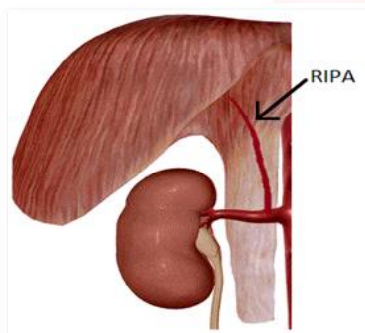
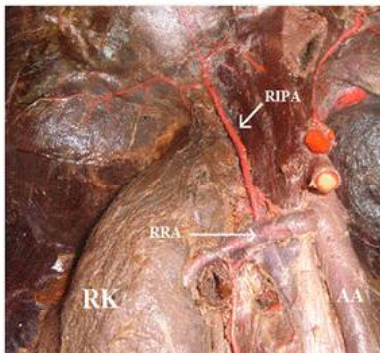


Fig. 1C: Right inferior phrenic artery (RIPA) deriving from the right renal artery on corpse.



CASE REPORT

During a routine dissection in the discipline of Descriptive and Topographic Anatomy of Federal University of São Paulo a vascular variant in the abdominal cavity of a 34-year-old black male was found. His right inferior phrenic artery derived from the right renal artery (RRA) as shown in figure 1C.

This cadaver was fixed in a 10% formaldehyde (formol) solution and conserved in glycerin after fixation. Latex was injected using the Giacomini method to better identify the arteries.

DISCUSSION

An “extra-hepatic” collateral arterial supply to the hepatocellular carcinoma may appear after a successful embolism or may exist simultaneously with the hepatic arterial supply [4,5]. The RIPA potentially communicates with the intrahepatic arteries. Among the various collateral pathways, one of the most common sources of extrahepatic blood supply to the liver is the RIPA [6,7]. All liver segments have the potential for such communication, but it typically occurs with the caudate lobe and posterior

Fig. 1B: Right inferior phrenic artery (RIPA) deriving from the right renal artery.

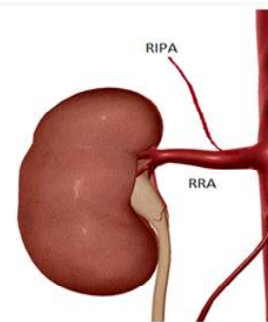
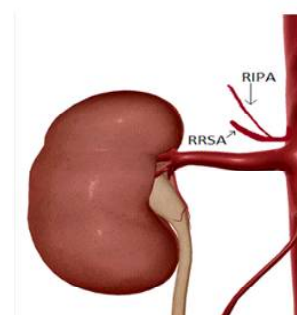


Fig. 1D: Right inferior phrenic artery (RIPA) deriving from the right suprarenal artery.



segment, whereas the frequency of communication with the other segments is lower [7]. In cases of occlusion or severe stenosis of hepatic arteries after repeated TACE, the hepatic arteries are mainly reconstituted through the RIPA.

Thus, it is important to have this information because hepatocellular carcinoma can be treated by transcatheter embolization not only of the typical blood supply (right and left hepatic arteries) but also of the right inferior phrenic artery [1,4].

The importance of the RIPA is not limited to the treatment of HCC. Practically any hepatic neoplasm (including metastatic disease to the liver) may receive blood supply from the RIPA [8].

The diameter of the RIPA is larger than that of the LIPA in patients with HCCs fed by the RIPA. A RIPA dilated to more than 2.5 mm is predictive of a parasitic supply [9,10]. However, previous studies indicated that the normal diameter of the RIPA and LIPA is 2.2 mm (range, 1.4–3.2 mm) and 2.0 mm (range, 1.4–2.8 mm), respectively. Therefore, more predominance of the RIPA is not a certain predictor of extrahepatic collateral supply because the RIPA can also be predominant in the normal population [10].

Chung et al. (1997) reported that in almost all studied patients with hepatocellular carcinoma (47 of 50 patients), the RIPA fed this tumor [1]. Tanabe et al. (1998) stated that in 14 of 126 patients, treatment of hepatocellular carcinoma could not have been successful if they had not considered the right inferior phrenic artery [1,4]. This finding is clinically important because normally, embolization for this type of tumor is done to the hepatic artery without taking into account that part of the blood supply may be coming from the RIPA.

In our laboratory, only this cadaver presented the right inferior phrenic artery deriving from the right renal artery in approximately 30 years, according to a Professor (José Carlos Prates) who had worked in the laboratory during this time. Similarly, Deepthinath et al. (2006), Bakheit & Motabagani (2004) also found only one male cadaver who presented multiple variations, among them the origin of RIPA in the right renal artery [11]. Gokan et al. observed the RIPA arising

from the RRA in 9% of cases studied [5]. Piao et al. (1998) verified that in 4.3% of 68 Japanese cadavers, RIPA originated in the RRA, which represents a slightly higher number but still small [11]. However, it must be emphasized that even if RIPA does not frequently originate in the right renal artery, this likelihood cannot be ignored. There is possibility right inferior phrenic artery deriving from the half right adrenal artery [13] as can be seen in Figure 1D.

These variations can be demonstrated in the preoperative period by selective angiography, supplying guidelines to endovascular procedures, such as therapeutic embolization and angioplasty [14].

Since transcatheter embolization of hepatocellular carcinoma and other hepatic neoplasms such as hepatoblastoma and capsular adenoma, often involve studying the root of RIPA, angiography can be potentially beneficial to determine the variations of the origins of these vessels [11]. Furthermore, this data can promote discussions about other hepatic lesions and even lesions of the diaphragm.

CONCLUSION

The anatomical knowledge of possible variations of right phrenic inferior artery's origin are essential to gastroenterologists and oncologists. Abdominal surgeries without proper knowledge of possible variations of this artery can lead to iatrogenic dissection and rebound the irrigated area by it. Their possible involvement in hepatic neoplasms also justifies its importance for post-surgical prognosis.

ABBREVIATIONS

HCC – Hepatocellular carcinoma

LIPA – Left inferior phrenic artery

RIPA – Right inferior phrenic artery

RRA – Right inferior artery

TACE – Transcatheter arterial chemoembolization

ACKNOWLEDGEMENTS

All authors are thankful to the Department of Descriptive and Topographic Anatomy of the Federal University of São Paulo for providing us the corpse with variation on right inferior phrenic artery's origin. Authors of this study also ackno-

wledged to authors, editors and publishers of all those articles, journals and books from where literature for this article has been discussed.

Conflicts of Interests: None

REFERENCES

- [1]. Chung JW, Park JH, Han JK, Choi BI, Kim TK, Han MC. Transcatheter oily chemoembolization of the inferior phrenic artery in hepatocellular carcinoma: the safety and potential therapeutic role. *J Vasc Interv Radiol* 1998;9:495-500.
- [2]. Michels N. Blood supply and anatomy of the abdominal organs. London: Pitman Medical Publishing; 1955. p. 35-36.
- [3]. Hiwatashi A, Yoshida K. The origin of right inferior phrenic artery on multidetector row helical CT. *Clin Imaging* 2003;27(5):298-303.
- [4]. Tanabe N, Iwasaki T, Chida N, Suzuki S, Akahane T, Kobayashi N, Ishii M, Toyota T. Hepatocellular carcinomas supplied by inferior phrenic arteries. *Acta Radiol* 1998;39:443-7.
- [5]. Gokan T, Hashimoto T, Matsui S, Kushihashi T, Nobusawa H, Munechika H. Helical CT demonstration of dilated right inferior phrenic arteries as extrahepatic collateral arteries of hepatocellular carcinomas. *J Comput Assist Tomogr* 2001;25(1):68-73.
- [6]. Takeuchi Y, Arai Y, Inaba Y, Ohno K, Maeda T, Itai Y. Extrahepatic arterial supply to the liver: observation with a unified CT and angiography system during temporary balloon occlusion of the proper hepatic artery. *Radiology* 1998;209:121-128.
- [7]. Yamagami T, Kato T, Tanaka O, Hirota T, Nishimura T. Influence of extrahepatic arterial inflow into the posterior segment or caudate lobe of the liver on repeated hepatic arterial infusion chemotherapy. *J Vasc Interv Radiol* 2005;16(4):457-463.
- [8]. Northrop CH, Studley MA, Smith GR. Hemorrhage from the gastroesophageal junction. A cryptic angiographic diagnosis. *Radiology*. 1975;117(3 Pt 1):531-2.
- [9]. Loukas M, Hullett J, Wagner T. Clinical anatomy of the inferior phrenic artery. *Clin Anat* 2005;18(5):357-365.
- [10]. Okino Y, Kiyosue H, Matsumoto S, Takaji R, Yamada Y, Mori H. Hepatocellular carcinoma: prediction of blood supply from right inferior phrenic artery by multiphase CT. *J Comput Assist Tomogr* 2003;27(3): 341-346. CrossRef, Medline
- [11]. Bakheit M, Motabagani M. Anomalies of the renal, phrenic, suprarenal arteries. *Saudi Med J* 2004;25(3):376-8.
- [12]. Piao DX, Ohtsuka A, Murakami T. Typology of abdominal arteries, with special reference to inferior phrenic arteries and their esophageal branches. *Acta Med Okayama* 1998;52(4):189-96.
- [13]. Lin PH, Chalk EL. Embryology, anatomy and surgical exposure of the abdominal blood vessels. *Surg Clin N Am*. 2000;80:417-33.
- [14]. Deepthinath R, Satheesha Nayak B, Mehta RB, Setharama B, Rodrigues V, Samuel VP, Venkataramana V, Prasad A. Multiple variations in the paired arteries of the abdominal aorta. *Clin Anat* 2006;19:566-8.

How to cite this article:

Faria L.A.M, Ferreira W.S.M, Almeidinha D. L, Moraes L.O.C. RIGHT INFERIOR PHRENIC ARTERY AS A BRANCH OF THE RIGHT RENAL ARTERY: A CASE REPORT. *Int J Anat Res* 2016;4(1):1754-1757. **DOI:** 10.16965/ijar.2015.317