

A STUDY OF TIBIAL NERVE BIFURCATION AND BRANCHING PATTERN OF CALCANEAL NERVE IN THE TARSAL TUNNEL

D.Malar

Assistant Professor, JSS Medical College, JSS University, Mysore, Karnataka, India.

ABSTRACT

Background: Tibial nerve in the distal part of the leg branches into the calcaneal branch, medial plantar nerve and lateral plantar nerve. These branches innervate calcaneal, the medial plantar and the lateral plantar areas of the foot, respectively and carry sensory information from these areas. Tibial nerve and its branches show variation in branching pattern, and level of bifurcation. Detail knowledge of the anatomical variation of tibial nerve and its branches is essential for diagnosis and therapy tarsal tunnel syndrome, fractures requiring external nailing and nerve blocks.

Materials and Methods: Tibial nerve and its branches in the tarsal tunnel were dissected and studied in twenty adult cadavers. Bifurcation levels of tibial nerve in relation to the Medio-malleolar-calcaneal axis were noted. The ramification pattern of medial calcaneal nerve was observed and studied.

Results: In the present study tibial nerve bifurcation occurred within the tunnel in 100% cases. According to the level of bifurcation, 85% cases was type I, 10% cases was type II and 5% cases was type III. Medial calcaneal branches showed variations in number and origin, one medial calcaneal nerve was observed in 50% case, two in 20% cases and three in 10% of cases. The medial calcaneal nerve originated from the tibial nerve in 85% cases.

Conclusion: The knowledge of these variations may help in diagnosis and therapy of tarsal tunnel syndrome and prevent damage to the structures in the tarsal tunnel during various surgical procedures in the tarsal region.

KEY WORDS: Tibial nerve, branches, variations, tarsal tunnel syndrome,

Address for Correspondence: Dr. D. Malar, Assistant professor, JSS Medical College, JSS University, Mysore, Karnataka, India. Phone Number: 91-9448434067, 08212410142

E-MAIL: janavi.rk@gmail.com, malarjan2519@gmail.com

Access this Article online

Quick Response code



DOI: 10.16965/ijar.2016.139

Web site: International Journal of Anatomy and Research
ISSN 2321-4287
www.ijmhr.org/ijar.htm

Received: 08 Feb 2016 Accepted: 20 Feb 2016
Peer Review: 08 Feb 2016 Published (O): 29 Feb 2016
Revised: None Published (P): 29 Feb 2016

INTRODUCTION

The tibial nerve is the larger branch of the sciatic nerve. In the leg the tibial nerve descends with posterior tibial vessels and lies in a fibro-osseous tunnel called tarsal tunnel. The tunnel is bounded by the flexor retinaculum medially, the posterior aspect of talus and calcaneum laterally, and the medial malleolus anteriorly. The tibial nerve divides into medial and lateral plantar nerves under the flexor retinaculum [1]. The tarsal tunnel or porta pedis

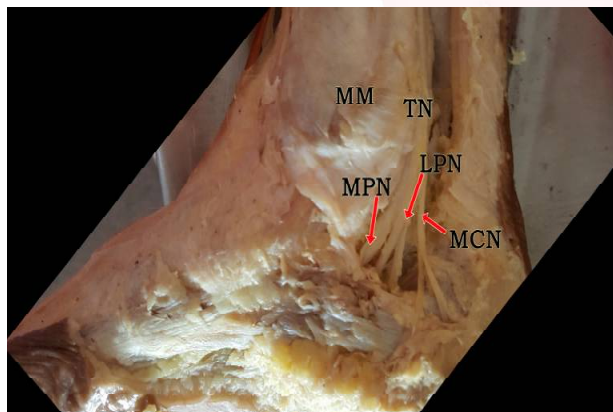
also transmits the tendon of tibialis posterior, flexor hallucis longus, flexor digitorum longus and posterior tibial vessels. The nerve, blood vessels and the tendons lie in separate compartments deep to the flexor retinaculum [2,3]. Medial calcaneal nerves arise at the ankle, pierce the flexor retinaculum, and supply the posterior and lower surface of the heel. Compression of tibial nerve due to compromise of space in the tarsal tunnel can lead to tarsal tunnel syndrome [4]. A thorough knowledge of anatomical variations of tibial nerve and its

branches in the tarsal tunnel is essential for diagnosis and treatment of tarsal tunnel syndrome and various other surgical procedures in the medial tarsal region. The present work was undertaken to study the tibial nerve bifurcation and branching patterns of calcaneal branches.

MATERIALS AND METHODS

Twenty lower limbs of adult cadavers were dissected and studied. These embalmed cadavers were given for dissection to the undergraduate medical students in the department of anatomy. The osseo-fibrous compartment deep to the flexor retinaculum was dissected and contents were exposed. The point of bifurcation of tibial nerve, number and origin of the medial calcaneal branches were noted. Medio-malleolar-calcaneal axis was used as grid to note the point of bifurcation of the tibial nerve. Medio-malleolar-calcaneal axis extended from the tip of medial malleolus to the medial tubercle of calcaneus. The tarsal tunnel was defined by extending two centimeters proximal and distal to the axis [5].

Fig. 1: right limb; tibial nerve (TN) bifurcation, Medial plantar nerve (MPN), Lateral plantar nerve (LPN) and Medial calcaneal nerves (MCN) and Medial malleolus (MM).



RESULTS AND DISCUSSION

In the present study it was observed that the flexor retinaculum was not clearly demarcated at its superior and inferior borders [6,7]. There was also no clear demarcation between the borders of flexor retinaculum and the deep fascia of the leg [7,1]. A distinct flattening of the tibial nerve was observed at its bifurcation in 55% of specimens and this could be due to nerve compression by adjacent structures [7].

The tibial nerve bifurcation occurred within the tarsal tunnel (within 2cm of medio-malleolar-calcaneal axis) in all the 20 limbs (100%) [6-11]. In 85 % of cases Tibial nerve bifurcation was noted proximal to the medio-malleolar-calcaneal axis (type I), 10% at the axis(type II) and in 5% cases bifurcation of tibial nerve was noted distal to the axis (type III) Similar observation was noted by other authors [7,11]. One medial calcaneal nerve was observed in 50% cases, two medial calcaneal nerve in 30% cases, and three medial calcaneal nerve in 20% cases [6, 7,9]. The medial calcaneal nerve arising from the tibial nerve was in 85%cases and 25% originated from tibial and lateral planter nerve [6].

The knowledge of bifurcation level of the tibial nerve is essential for diagnosis and treatment of tarsal tunnel syndrome, performance of tibial nerve block, external nailing of the tarsal bones and various surgical procedures [11]. The distal tibial nerve and its branches is of special interest for functional electrical stimulation such as the correction of foot drop and for standing and walking of spinal cord injured patients [12].

CONCLUSION

In the present anatomical study tibial bifurcation occurred within the tarsal tunnel. In most cases the terminal part of the tibial nerve showed flattening. Medial calcaneal nerve showed variations in number and origin. Awareness of these variations observed in the medial tarsal region is important for clinicians.

ACKNOWLEDGEMENTS

I am grateful to Mr. Vegadesan for his help in photographing the specimens for preparation of this article. I also thank the staff members of department of anatomy for assisting in the study.

Conflicts of Interests: None

REFERENCES

- [1]. Williams PL, Bannister LH, Martin, Berry, et al. Nervous system. Grey's Anatomy. 38th edn. London: Churchill living stone, 1996;1284-1286.
- [2]. Data AK. Posterior crural region. Essentials of human anatomy part III, 3rd edn. Kolkata: Current books international, 2004;204.

- [3]. Kohno M, Takahashi H, Segawa H, Sano K. Neurovascular decompression for idiopathic tarsal tunnel syndrome : technical note. *J Neurol Neurosurg Psychiatry*, 2000;69:87-90.
- [4]. Standing S, Ellis H, Healy JC, Jhonson D, William A et al. *The Anatomical basis of clinical practice. Gray's Anatomy*, 39th edn London: Churchill Livingstone, 2005;1502-1504.
- [5]. Torres ALG, Ferreira MC. Study of anatomy of tibial nerve and its branches in the distal medial leg. *Acta Ortopedica Brasileria*. 2012;20(3):157- 164.
- [6]. Nagaoka M. An anatomical study of tarsal tunnel. *Nippon seikeigeka Gakkai Zasshi*, 1910;64(4):208-216.
- [7]. Joshi SS, Joshi SD, Athavale SA. Anatomy of Tarsal tunnel and its applied significance. *J.Anat.Soc. India*, 2006;55(1):52-56.
- [8]. Davis TJ, Schon LC. Branches of the tibial nerve: anatomic variations. *Foot Ankle Int*.1995; 41(6):645-646.
- [9]. Ndiaye A, Dia A, Konate I, Diop M, Sow ML. Topographic anatomy of the tibial nerve in the medial malleolus: application to the effect of nerve block anesthesia. *Morphologie*, 2003;87(277):25-27.
- [10]. Heimkes B, Posel P, Stotz S, Wolf K. The Proximal and distal tarsal tunnel syndromes. An Anatomical study. *Int Orthop*. 1987; 11(3):193-196.
- [11]. Bilge O, ozer MA, Govsa F. Neurovascular branching in the tarsal tunnel. *Neuroanatomy*, 2003;2:39-41.
- [12]. Andreasen Struijk LNS, Birn H, Teglbjaeg PS, Haase J, Stuijk JJ. Size and separability of the calcaneal and the medial and lateral plantar nerves in the distal tibial nerve. *Anat. Sci. Int* . 2010; 85:13-22.

How to cite this article:

D.Malar A STUDY OF TIBIAL NERVE BIFURCATION AND BRANCHING PATTERN OF CALCANEAL NERVE IN THE TARSAL TUNNEL. *Int J Anat Res* 2016;4(1):2034-2036. **DOI:** 10.16965/ijar.2016.139