

STUDY OF VARIATIONS IN THE ORIGIN OF BICEPS BRACHII WITH SPECIAL THRUST ON ITS INNERVATIONS

Eti Sthapak ^{*1}, Navbir Pasricha ², Mohmmad Shakil Siddiqui ³.

^{*1} Assistant Professor, Department of Anatomy, Era's Lucknow Medical College & Hospital, Lucknow, India.

² Professor, Department of Anatomy, Era's Lucknow Medical College & Hospital, Lucknow, India.

³ Professor and Head, Department of Anatomy, Institution : Era's Lucknow Medical College & Hospital, Lucknow, India.

ABSTRACT

Background: Though human beings are thought to be singularly alike in their general anatomical construction, but when we come to investigate one particular region in detail, we frequently meet one or another type of variations. Muscles of the arm exhibit numerous variations. Commonest muscle of the arm to show variations is the biceps brachii. We are presenting series of variation of origin and number of heads of bicep brachi.

Materials and Methods: 20 limbs were dissected as per the standard methods to note the origin, insertion and the nerve supply of the biceps brachii in the Department of Anatomy, Era's Lucknow Medical College & Hospital, India.

Result: Supernumerary head of bicep brachii was seen in three limbs (15%). The origin of supernumerary head was different in each case though the nerve supply to each head was via musculocutaneous nerve.

Discussion: These supernumerary heads might be significant in producing the strong flexion as well as supination of forearm. They may cause compression of neurovascular structures because of their close relationship to brachial artery and median nerve.

Conclusion: Variant biceps brachii may confuse a surgeon who performs procedures on the arm and may lead to iatrogenic injuries. The surgeons should keep such muscular variations in mind.

KEY WORDS: Biceps Brachii, Variations, Accessory head, Innervations.

Address for Correspondence: Dr. Eti Sthapak, Assistant Professor, Department of Anatomy, Era's Lucknow Medical College & Hospital, Sarfaraj ganj, Moosa Bagh, Picnic Spot, Hardoi road, Lucknow-226003, India. **E-Mail:** etiupadhyaya@yahoo.co.in

Access this Article online

Quick Response code



DOI: 10.16965/ijar.2016.128

Web site: International Journal of Anatomy and Research
ISSN 2321-4287
www.ijmhr.org/ijar.htm

Received: 31 Jan 2016 Accepted: 16 Feb 2016
Peer Review: 01 Feb 2016 Published (O): 29 Feb 2016
Revised: None Published (P): 29 Feb 2016

BACKGROUND

Though human beings are thought to be singularly alike in their general anatomical construction, but when we come to investigate one particular region in detail, we frequently meet one or another type of variations. Muscles of the arm exhibit numerous variations. Commonest muscle of the arm to show variat-

ions is the biceps brachii. In the present study we have studied the variations in the origin of biceps brachii with its innervation.

Biceps brachii muscle belongs to the flexor group of muscle in arm. It is the only flexor muscle of the arm which crosses the shoulder as well as the elbow joint. Biceps brachii muscle has two heads, short head and long head. Long head

originates from the supraglenoid tubercle of scapula and short head originates from the coracoid process of scapula . Distally, these two heads join to form a common belly which inserts on the radial tuberosity as a tendon, and some aponeurotic fibers form the bicipital aponeurosis which merges with deep fascia of forearm. This muscle mainly contributes to flexion and supination of forearm . The Biceps brachii muscle is innervated by the musculocutaneous nerve and supplied by brachial and anterior circumflex humeral arteries. It has been reported that in 10% of cases, the third head of Biceps may arise from the superomedial part of the brachialis and is attached to bicipital aponeurosis and medial side of tendon insertion [1].

The biceps brachii muscle shows variations in the number of heads, with an estimated 9-22% of the population having a supernumerary head [2]. Thus, recognizing abnormalities of the biceps tendon is important because they are a common source of shoulder pain both alone and in combination with abnormalities of the rotator cuff, labrum and other structures. If diagnosis is not made appropriately it can lead to treatment failure, so it is important to recognize this less common entity. This can also help the surgeon in focusing the treatment on the actual pathology. Hence, knowledge of the existence of these anatomic variants is necessary to avoid errors in shoulder arthroscopy, surgery and evaluation of MRI scans [3]. Thus, we initiated a study designed to evaluate the nature of this finding in cadavers with a special thrust on its innervation.

MATERIALS AND METHODS

This study was carried out in the Department of Anatomy, Era's Lucknow Medical College & Hospital, India from 2015 to 2016. Ten cadavers (20 limbs), formalin fixed, irrespective of age and sex were dissected as per the standard methods. Detailed study of origin, insertion and presence of supernumerary heads of biceps brachii muscle was observed. Careful isolation of variant heads of biceps brachii was done, their proximal and distal attachment made clear in addition their pattern of innervation were also noted.

RESULTS

Three out of twenty arms (15%) were observed to have a three headed biceps brachii muscle. Accessory head of bicep brachii was seen in two right limbs and one left limb (unilateral). The origin of accessory head was different in each case.

Accessory head observed in one right limb originated from tendinous fibers which came from pectoralis major muscle near its insertion (Fig.1a,1b).

In the other variant right limb third head originated from lateral border of coracoid process (Fig.2a,2b).

In the variation observed in left limb, the third head originated from lateral lip of bicipital groove at its middle part (Fig.3a,3b) .

All the accessory heads were tendinous, then formed a fleshy belly & were inserted along with the main fleshy belly of the biceps. Each head received separate branch of innervation from musculocutaneous nerve (Fig. 1b,2b,3b).

Fig. 1a: Photograph of right shoulder & arm region showing tendinous accessory head originated from Pectoralis major muscle.

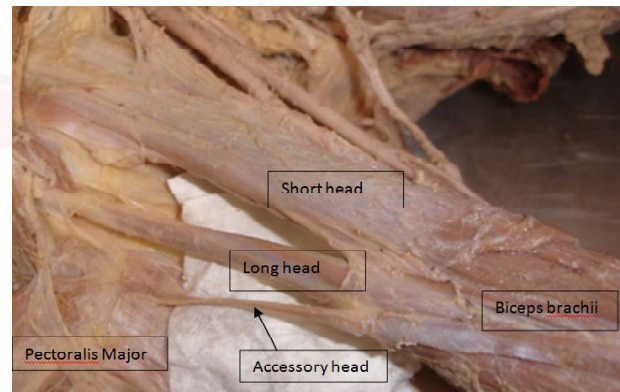


Fig. 1b: Photograph of accessory head of biceps brachii shows a separate branches of musculocutaneous nerve supplying the muscles.

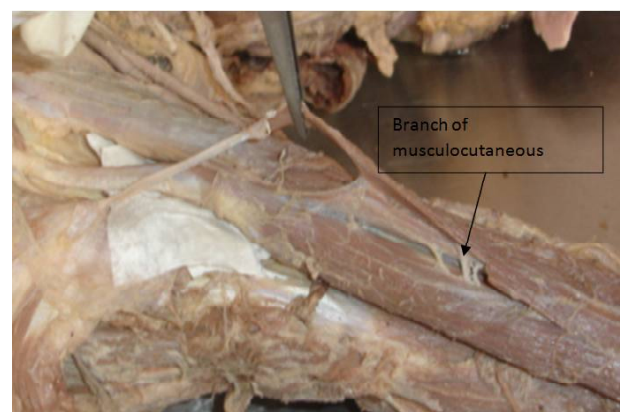


Fig. 2a: Photograph of right shoulder & arm region showing accessory head originated from lateral border of coracoid process.

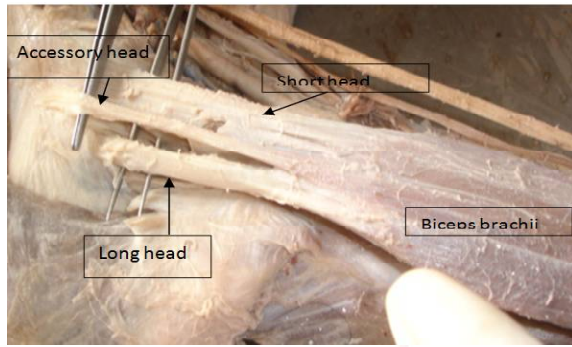


Fig. 2b: Shows musculocutaneous nerve gives three separate branches to three heads of biceps brachii.

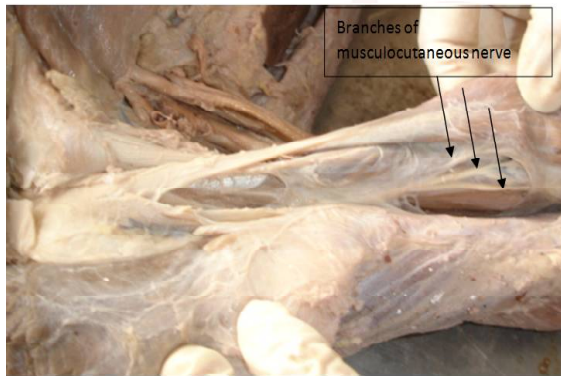

Fig. 3a: Photograph of left shoulder & arm region showing accessory head originated from lateral lip of bicipital groove.

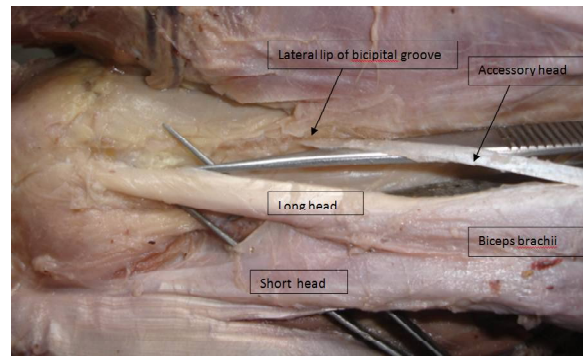
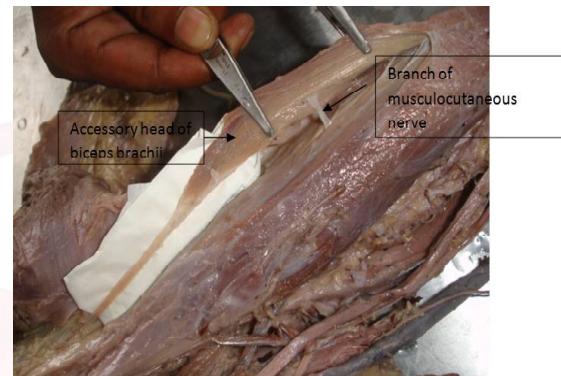


Fig. 3b: Shows branch of musculocutaneous nerve supply accessory head of biceps brachii.



DISCUSSION

In our study incidence of supernumerary head of biceps brachii was 15%. The review of literature shows a large variation in the occurrence of third head of biceps in different races: Africans – 18% Europeans – 12%, Chinese- 8%, Indian – 2 -7.1% [4-7]. Though the occurrence of third head of biceps brachii is not uncommon but it is seen less in the Indian population. Third head of Biceps may arise from any of these sources: coracoid process, pectoralis major tendon, head of humerus, articular capsule of humerus, shaft of humerus [8]. In the present study in two right limb accessory head originated, from pectoralis major & from lateral border of coracoid process which has been reported previously. The extension of the origin of biceps brachii on the coracoid process can be explained developmentally as it will add more stability to the shoulder joint. In the present study we found an unusual third head originated from the lateral lip of bicipital groove in left limb which has not been reported in previous studies. The accessory head of biceps brachii simulate partial tearing

of biceps tendon in MRI studies [9].

Variations in supernumerary heads of biceps brachii muscle occur due to genetic composition, inheritance carried over from ancient origins, errors of embryologic development or persistence of an embryological condition [10-12].

The nerve supply of the third head of the biceps brachii is by a branch of musculocutaneous nerve as was observed in our study and quoted by other authors [13,14]. Though in few case reports the third head of biceps brachii was supplied by a branch from the median nerve [15].

These supernumerary heads might be significant in producing strong flexion as well as supination of forearm [16]. They may cause compression of neurovascular structures because of their close relationship to brachial artery and median nerve [17]. Presence of third head of biceps brachii makes the muscle more bulky which may compress the musculocutaneous nerve. Intramuscular course is a potential compression site and compression of nerve in between heads of biceps may lead to paraesthesia and

weakness of elbow flexion and supination due to involvement of brachialis and nerve to long head of biceps. Accessory head may cause compression of neurovascular structures because of its close relationship to the brachial artery and median nerve. Therefore, surgeons, in particular orthopedic surgeons, should be aware of these anatomical variations of biceps brachii when dealing with some of the clinical syndromes. Morphological description helps in proper appreciation of the functions of Biceps brachii and may be helpful to the surgeons in the repair of ruptured biceps tendon [18]. Biceps brachii is useful as a component of flap surgery; in such cases the knowledge of the innervations of accessory head is important for plastic surgeons.

CONCLUSION

Knowledge of the morphological variations of biceps muscle provides better pre-operative evaluation, safe surgical intervention within the arm and better postoperative outcomes.

Conflicts of Interests: None

REFERENCES

- [1]. Susan Standring, Grays's anatomy: The anatomical basis of clinical medicine. 40th edition. Churchill Livingstone 2010;6: 825-26.
- [2]. Kosugi K, Shibata S, Yamashita H. Supernumerary head of biceps brachii and branching pattern of the musculocutaneous nerve in Japanese. *Surg Radiol Anat.* 1992;14:175-185.
- [3]. Nakatani, T.; Tanaka, S. & Mizukami, S. Bilateral fourheaded biceps brachii muscles: the median nerve and brachial artery passing through a tunnel formed by a muscle slip from the accessory head. *Clin. Anat.* 1998;11:209-12.
- [4]. Rai R, Randa AV, Prabhu LV, Pai MM, Prakash. Third head of biceps brachii in an Indian population. *Singapore Med. J.* 2007;48(10):929-931.
- [5]. Bergman RA, Thompson SA, Afifi AK, Saadeh FA. *Compendium of Human Anatomic Variations.* Baltimore: Urban & Schwarzenberg, 1988:139-143.
- [6]. Soubhagya R, Nayak, Latha V, et al. Third head of biceps brachii: a rare occurrence in the Indian population. *Ann Anat* 2006;188:159-61.
- [7]. Sargon MF, Tuncali D, Celik HH. An unusual origin for the accessory head of biceps brachii muscle. *Clin Anat* 1996;9:160-162.
- [8]. Abdullah G. Al-Kushi. Anatomical study of the third head of biceps brachii muscle and its innervation by median nerve in human dissection. *Journal of Clinical Medicine and Research* 2013;5:47-52.
- [9]. Ramon Gheno, Cristiane S. Zoner, Florian M. Buck, Marcelo A. C. Nico, Parviz Haghighi, Debra J. Trudell and Donald Resnick. Accessory Head of Biceps Brachii Muscle: Anatomy, Histology, and MRI in Cadavers. *American Journal of Roentgenology.* 2010;194:80-83.
- [10]. de Burlet HM, Correlje J. Uber Variationen des menschlichen Musculus biceps brachii. *Gegenbaur's Morphol. Jahrb.* 1919;50: 403-16.
- [11]. Sonntag CF. On the anatomy, physiology and pathology of the chimpanzee. *Proc. Zool. Soc.* 1923; 22: 323-363.
- [12]. Nayak SR, Krishnamurthy A, Kumar M et al. Four headed Biceps and Triceps brachii muscle, with neurovascular variation. *Anat. Sci. Lut.* 2008;83: 107-11.
- [13]. Ilayperuma, I.; Nanayakkara, G. & Palahepitiya, N. Incidence of humeral head of biceps brachii muscle-Anatomical insight. *Int. J. Morphol.* 2011;29(1):221-225.
- [14]. Mamatha H, Suhani S, Lakshmeesha Rao, Aruna Shree, Naveen Kuma. Supernumerary Heads Of Biceps Brachii Muscle In South Indian Cadavers. *Anatomy Journal of Africa* 2013;2(1):108-113.
- [15]. Abdullah G. Al-Kushi. Anatomical study of the third head of biceps brachii muscle and its innervation by median nerve in human dissection. *Journal of clinical medicine & research.* 2013;5(4):47-52.
- [16]. PP Poudel and C Bhattarai. Study on the supernumerary heads of biceps brachii muscle in Nepalese. *Nepal Med Coll J* 2009;11(2):96-98.
- [17]. Ramakrishna Avadhani, K. Kalyan Chakravarthi. A Study On Morphology Of The Biceps Brachii Muscle. *Nitte University Journal of Health Science.* 2012;2(3). ISSN 2249-7110.
- [18]. S.D. Joshi, S.S. Joshi, Y.A. Sontakke, P.S. Mittal. Some details of morphology of biceps brachii and its functional relevance. *Journal of the Anatomical Society of India.* 2014;63(1):24-29.

How to cite this article:

Eti Sthapak, Navbir Pasricha, Mohmmad Shakil Siddiqui. STUDY OF VARIATIONS IN THE ORIGIN OF BICEPS BRACHII WITH SPECIAL THRUST ON ITS INNERVATIONS. *Int J Anat Res* 2016;4(1):1994-1997. DOI: 10.16965/ijar.2015.128