

PERONEUS QUARTUS IN SOUTH INDIAN POPULATION: A CADAVERIC STUDY

Somesh M.S. ^{*1}, Murlimanju B.V ², Roshan S ³, Gautham Kamble ⁴.

^{*1} Associate Professor, Srinivas Institute of Medical Sciences & Research Centre (SIMS &RC), Mangalore, Karnataka, India.

² Associate Professor, Kasturba Medical College, Mangalore, Manipal University, Karnataka, India.

^{3,4} Assistant Professor, Srinivas Institute of Medical Sciences & Research Centre (SIMS &RC), Mangalore, Karnataka, India.

ABSTRACT

Aim: To observe the occurrence of any anomalous muscle known as peroneus quartus in the lateral compartment of the leg.

Materials and Methods: Forty seven (47) formalin fixed cadavers used for the routine dissection for the first year medical undergraduate students in Anatomy Dissection Laboratory at Srinivas Institute of Medical Sciences & Research Centre (SIMS& RC) and KMC, were chosen. Lateral compartment of the leg of these cadavers were chosen and neatly dissected.

Results: Out of these cadavers studied, we incidentally noted the Peroneus quartus muscle in the lateral compartment of the leg in two cadavers. In first case, it originated from the Peroneus longus and attached to the eminence on the lateral aspect of the calcaneum just behind the peroneal trochlea and in the second case from that of the Peroneus brevis tendon and inserted into the fifth metatarsal bone antero-medial to the main tendon and muscles in all other cadavers followed normal pattern of origin and insertions.

Conclusion: Incidence of this variant called the peroneus quartus is rare and the knowledge of such rare anatomical variations is important to Surgeons and Orthopedicians performing various procedures around the ankle joint.

KEY WORDS: Peroneus Quartus, Peroneus compartment, Leg, Ankle joint

Address for Correspondence: Dr. Somesh M.S., Associate Professor, Department of Anatomy, Srinivas Institute of Medical Science & Research Centre (SIMS&RC), Srinivas University, Surathkal, Mangalore – 574146, Karnataka, India. Phone no.: +919686924032

E-Mail: drsomeshms@gmail.com

Access this Article online

Quick Response code



DOI: 10.16965/ijar.2016.123

Web site: International Journal of Anatomy and Research
ISSN 2321-4287
www.ijmhr.org/ijar.htm

Received: 29 Jan 2016 Accepted: 12 Feb 2016
Peer Review: 29 Jan 2016 Published (O): 29 Feb 2016
Revised: None Published (P): 29 Feb 2016

INTRODUCTION

Surgical procedures are commonly performed in the lower extremity in and around the fibula, and an adequate knowledge of both normal and abnormal anatomy of the lateral region of leg is needed for any successful surgeries in this region. Also with the adaption of erect posture,

the foot has to bear weight of the body and also has to maintain balance while standing, walking etc, where the lateral compartment muscles of leg viz. fibularis (peroneus) longus and fibularis (peroneus) brevis comes into picture. The role of the fibular muscles is to evert the ankle and stabilize its subtler motion [1,2]

and also help in performing complex activities like dancing, skating etc and variations of these muscles are not uncommon [3]. Variants in the insertional pattern of fibularis longus [4] and fibularis brevis muscle [3,4] have been discussed in various literatures.

Apart from fibularis longus and brevis, a number of fibular accessory muscles have been described such as peroneus digiti quinti [5] or peroneus quartus [6] and this peroneus quartus is a very important variant of fibular muscles in the lateral compartment of the leg.

Therefore a in the present study an attempt has been made to study the anatomical and morphological details of peroneus quartus muscle and to create an awareness about anatomical variations of such muscles which is clinically relevant to surgeons undertaking various surgical procedures in the leg and foot.

MATERIALS AND METHODS

A total of Forty seven (47) lower limbs of formalin fixed cadavers were dissected in Anatomy Dissection Laboratory at Srinivas Institute of Medical Sciences & Research Centre (SIMS &RC) and Kasturba Medical College (KMC), Mangalore of which 32 belonged to 16 intact cadavers and 15 were isolated lower limbs. A total of 30 legs were from male and 17 from female cadavers were selected over a period of three years. Lateral compartment of the leg of these cadavers were chosen and neatly dissected in a standard fashion with an incision which started about 4 inches proximal to the lateral malleolus and ended about 2 inches distal to it. The superior peroneal retinaculum was identified and the peroneal compartment was examined for any peroneal tendon pathology such as splits, tears or attrition. Then we noted for any anomalous insertion patterns of fibularis longus and fibularis brevis tendons.

RESULTS

Case 1: We could find the peroneus quartus muscle in two dissected limbs of the 47 cadaveric limbs studied. In the first case, it was identified in a single isolated right leg of a female cadaver aged around 57 years. About 3cm proximal to the tip of the lateral malleolus, the tendon of fibularis longus gave a 7.2 cm long

slip of peroneus quartus muscle, which passed separately in the retromalleolar groove and got inserted on to the raised eminence on the lateral aspect of the calcaneum just behind the peroneal trochlea. This main tendon of Peroneus longus ran over the plantar surface of the cuboid bone and attached to the lateral aspect of the base of the first metatarsal (Fig 1).

Case 2: Subsequently the peroneus quartus was also noticed in the left lower limb of an intact male cadaver aged around 47 years. In this male cadaver, the fibularis brevis tendon just before its insertion on the base of the fifth metatarsal bone, gave a 3.6 cm long slip of peroneus quartus muscle, which was inserted anteromedial to the main tendon and the tendons of these two muscles were separate throughout their course (Fig 2).

Fig. 1: Dissection of the peroneal compartment of the right leg.

1. Lateral malleolus; 2. Peroneus longus tendon (Yellow thread)
3. Peroneus Quartus tendon (Blue thread).
4. Peroneus brevis tendon (Green thread).

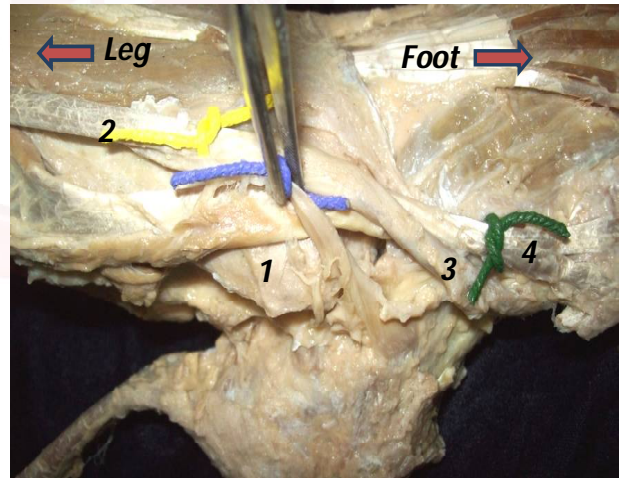
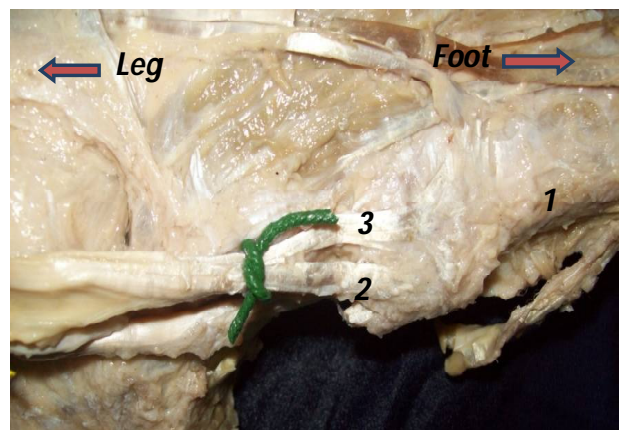


Fig. 2: Dissection of the peroneal compartment of left leg.

1. Fifth Metatarsal; 2. Peroneus Brevis tendon (Green thread)
3. Peroneus Quartus tendon



DISCUSSION

In humans, the variations in the muscles of the lower limb are not uncommon. There have been many variations both in the size and origin of the muscle belly and as well as in the length, size, course, and insertion of the tendon. In and around the foot and ankle, accessory muscles or anomalous muscles have been reported as much as about 8 % of the dissected limbs [7].

Normally in the lateral compartment, the peroneus longus muscle originates from the head and proximal two-thirds of the fibula and peroneus brevis muscle takes origin from the distal two-thirds of the fibula and these muscles traverses just below the lateral malleolus and the peroneus longus muscle gets inserted into the base of first metatarsal and medial cuneiform, whereas the peroneus brevis muscle is inserted into fifth metatarsal bone [8] and previous literature suggests that the variations in the muscles of the fibular compartment can range from 13% to 20% [9]. Also supernumerary muscles have been described in the various compartments of leg like accessory soleus in the posterior compartment [10] and peroneus quartus and peroneus digiti quinti muscles in the lateral compartment [5,11].

Various insertional patterns of accessory tendons of fibularis longus and brevis muscles have been reported in the previous literatures. The insertion of the tendon designated as peroneo - peroneus longus has been mentioned, with its insertion to the fibularis longus muscle in sole [12]. Accessory tendon arising from fibularis longus muscle and joining back with its main tendon just proximal to lateral malleolus is described [13]. The insertion of fibularis longus muscle as three tendinous slips to fifth, third and first metatarsal bones with an occasional slip to intermediate cuneiform bone [11], an additional slip to the medial cuneiform in 86.6% and an additional band close to the metatarsocuneiform joint in 30% of specimens, has been described [14]. In another study, the tendon of fibularis longus muscle was dividing into two, where first inserted into the lateral side of base of first metatarsal & medial cuneiform and other into tuberosity of the fifth metatarsal bone [15]. Also, slip from the tendon of fibularis

longus joining the first dorsal interosseous muscle has also been reported in the previous studies [15,13].

In a case study by Raheja et al, 2005 [3], the fibularis brevis muscle gave an additional slip just inferior to the fibular malleolus, which attached to the dorsal digital expansion of the little toe and the main tendon attached to the base of the fifth metatarsal bone. Also various authors have described an supernumerary muscle called peroneus digiti quinti, in the lateral compartment of leg, where it has been described as a small muscle arising either from tendon of peroneus brevis or distal fourth of the fibula and inserts into extensor aponeurosis of the little toe or to the head of the fifth metatarsus [11]. Also Sonmez et al, 2003 [16] described the peroneus digiti quinti muscle as a small slip which originated from the tendon of peroneus brevis around the malleolus, and attached to the dorsal aponeurosis of the fifth digit, with an additional small separate branch to the fifth metatarsal base. However in the present study fibularis brevis muscle gave an extra musculotendinous slip, just inferior to the fibular malleolus and both the main and the accessory tendons attached to the metatarsal of the fifth bone and the accessory tendon inserting anteromedial to the main tendon. So, whether this additional digital slip can be considered as another variant of peroneus digiti quinti muscle, needs to be studied in much detailed aspects in order to make more conclusive statements.

The Peroneus quartus muscle is an accessory muscle which originates mainly from the distal part of the fibula and or from the tendon of the peroneus longus and gets attached to the peroneal trochlea of the calcaneus [17]. Also sometimes it may arise as a small slip from the tendon of peroneus brevis around the malleolus, and gets attached to the fifth digit [16].

And this peroneus quartus muscle is thought to represent an evolutionary step in the development of bipedal posture of humans [12]. The incidence of the peroneus quartus muscle in our cadaveric study was 4.25%. The incidence of this muscle was less as compared with previous studies done in the past as shown in Table 1 [12,18,19].

Table 1: Incidence of Peroneus Quartus muscle in previous studies.

Earlier Studies	Incidence of Peroneus Quartus
Hecker, 1923 [12]	13%
Sobel et al, 1990 [18]	21.70%
Zammit and Singh, 2003 [19]	6.60%
Present Study	4.25%

So this Peroneus quartus is an exceptional muscle which presents various anatomical characteristics, both with regard to its origin and insertion and the most frequent origin was from the muscle fibres of peroneus brevis and its most frequent insertion was into the retrotrochlear eminence of the calcaneum [20]. In a detailed study carried on peroneus quartus muscle in 102 dissected cadaver legs, they found peroneus quartus in six (6.6%) legs with different proximal and distal attachments, where three were arising from the peroneus brevis muscle, two from the distal fibula and one from the distal fibres of peroneus longus tendon and out of which three inserted into the retrotrochlear eminence of the calcaneum, two into the base of the fifth metatarsal and one into the cuboid bone [19]. So, when peroneus quartus muscle originated from peroneus longus, its tendon passed separately in the retromalleolar groove and inserted into the retrotrochlear eminence of the calcaneum. In our present study, the scenario was similar to this with an additional slip arising from fibularis longus and inserting on to an eminence on the lateral aspect of the calcaneum, just behind the peroneus trochlea and we can consider this additional tendon as peroneus quartus muscle itself.

CONCLUSION

Only a few literature is available in the recent times regarding the origin, nature and importance of this muscle especially in our ethnic group to compare and contrast about the findings of this muscle. Also we believe that surgeons, orthopaeditions and radiologists should be aware of the existence of such variants of the muscles for possible associated pathology like peroneus tendonitis and tendon dislocations which are increasing alarmingly. Also peroneus tendon tears are also relatively common, especially the peroneus brevis tendon tears (PBT) in the lateral ankle-inversion injury

leading to chronic ankle instability. Also this peroneus quartus tendon can also be used to reconstruct the retromalleolar groove which stabilises the peroneal tendons in a patient with recurrent peroneal tendon dislocations. So the authors tend to do more work on this muscle so that the knowledge of this muscle and their variant is much beneficial for the surgeons for any ankle related injuries.

ACKNOWLEDGEMENTS

The authors are grateful for the nonteaching staff of the department of anatomy of SIMS&RC & KMC, for their support in conducting the present study. Also we are thankful for all the previous authors for their contribution in this field of medicine from which we are motivated to conduct the present study.

Conflicts of Interests: None

REFERENCES

- [1]. Sinnatamby, C S. Last 'Anatomy Regional and applied. 10th.ed. New York, Churchill Livingstone. 2001; 140-141.
- [2]. Moore, K L, Arthur FD. Clinically Oriented Anatomy. 4th ed. Lippincott Williams & Wilkins A Wolters Kluwer Company. 1999; 584 - 585.
- [3]. Raheja S, Choudhry R, Singh P , Tuli A, Kumar H. Morphological description of combined variation of distal attachments of fibulares in a foot. Surgical and Radiologic Anatomy. 2005; 27(2): 158-160.
- [4]. Sammarco GJ, Brainard JB. A symptomatic anomalous peroneus brevis in a high jumper: A case report. J Bone Joint Surg [Am]. 1991; 73-A: 131-133.
- [5]. Wood J. Variations in human myology observed during the winter session of 1867- 68 at King's College, London. Proc. Roy. Soc. Lond. 1868; 17: 483-525.
- [6]. Bergman RA, Afifi AK, Ryosuke M. Peroneus Brevis and longus. Illustrated Encyclopedia of Human Anatomic Variation. 2005; Opus I. Muscular system.
- [7]. Sarrafian S. Myology: Anatomy of the foot and ankle. Philadelphia, JB Lippincott. 1993; Vol 2: 218-226.
- [8]. Standring S. Gray's Anatomy. 39th. ed. Churchill Livingstone Elsevier New York, 2005; 1498-1499.
- [9]. Goss, C. CD. Gray's Anatomy. 29th ed. Lea & Febiger, Philadelphia, 1973.
- [10]. Mestdagh H, Champetie J, Mauroy B, Leclat H, Drizenko A, Vasseur J. The supernumerary muscles of the leg: A report of two cases. Surgical and Radiologic Anatomy 1990; 12(3): 219-223.
- [11]. Macalister A. Observation on muscular anomalies in the human anatomy. Third series with a catalogue of the principal muscular variations hitherto published. Trans. Roy. Irish Acad. (sciences). 1875; 25: 1.

- [12]. Hecker P. Study on the peroneus on the tarsus. *Anat Rec.* 1923; 26: 79-82
- [13]. Jayakumari S, Suri RK, Rath G, Arora J. Accessory tendon and tripartite insertion pattern of fibularis longus muscle: A case report. *International Journal of Morphology.* 2006; 24(4): 633-636
- [14]. Patil V, Frisch NC, Ebraheim NA. Anatomical variations in the insertion of the peroneus (Fibularis) longus tendon. *Foot & ankle international.* 2007; 28(11): 1179-1182.
- [15]. Harbeson AE. Further studies on the origin of the first dorsal interosseus muscle of the foot from the tendon of the peroneus longus. *Journal of Anatomy.* 1937; 72: 463-464.
- [16]. Sonmez M, Ko^oar I, Çimen M. The supernumerary peroneal muscles: Case report and review of the literature. *Folia Morphology.* 2003; 62(2):147-155.
- [17]. Wachter S, Beekman S. Peroneus Quartus: A case report. *J. Am. Podiatry Med. Assoc.* 1983; 73: 523-524.
- [18]. Sobel M, Levy ME, Bohne WH. Congenital variations of the peroneus quartus muscle: An anatomic study. *Foot Ankle.* 1990;11:81-89.
- [19]. Zammit J, Singh D. The peroneus quartus muscle: Anatomy and clinical relevance. *J Bone Joint Surg [Br].* 2003;85-B:1134-1137.
- [20]. Cheung YY, Rosenberg ZS, Ramsinghani R, Beltran J, Jahss MH. Peroneus quartus muscle: MRI imaging features. *Radiology.* 1997;202:745-750.

How to cite this article:

Somesh M.S., Murlimanju B.V, Roshan S, Gautham Kamble. PERONEUS QUARTUS IN SOUTH INDIAN POPULATION: A CADAVERIC STUDY. *Int J Anat Res* 2016;4(1):1972-1976. **DOI:** 10.16965/ijar.2016.123