

## AN ANATOMICAL STUDY ON THE POSITION OF MANDIBULAR FORAMEN IN 100 DRY MANDIBLES

Gopalakrishna. K <sup>\*1</sup>, Deepalaxmi S <sup>2</sup>, Somashekara S.C <sup>3</sup>, Rathna B.S <sup>4</sup>.

<sup>\*1,2</sup> Assistant Professor, Department of Anatomy, Malabar Medical College and Research Centre, Modakkallur, Atholi, Kozhikode, Kerala, India.

<sup>3</sup> Professor, Department of Pharmacology, Malabar Medical College and Research Centre, Modakkallur, Atholi, Kozhikode, Kerala, India.

<sup>4</sup> Professor, Department of Anatomy, Malabar Medical College and Research Centre, Modakkallur, Atholi, Kozhikode, Kerala, India.

### ABSTRACT

**Background:** Mandibular foramen is leading to mandibular canal through which inferior alveolar nerve and vessels will transmit and supply the teeth of lower jaw. Inferior alveolar nerve block is common anesthetic procedure prior to dental surgeries on lower jaw. Failure in mandibular anesthesia or injury to neurovascular bundle may be resulted by inaccurate localization of mandibular foramen. Hence this study is aimed to locate the mandibular foramen and its distances from different bone landmarks on internal surface of ramus of dry mandible of South Indian origin.

**Objective:** Study to determine the precise position of mandibular foramen in 100 dry mandibles, which is essential for successful inferior alveolar nerve block prior to dental procedures.

**Materials and Methods:** This descriptive study was done on 100 dentulous South Indian origin adult dry human mandibles of unknown sex and age. Distance of mandibular foramen from the mandibular notch, anterior border of the ramus of mandible, posterior border of the ramus of the mandible (angle of mandible), posterior border of the 3<sup>rd</sup> molar socket and meeting point of base with posterior border of ramus were measured. Further observation regarding the presence of accessory mandibular foramen was done. The observations were tabulated and descriptive statistics was used analyze the data.

**Result:** In the present study, totally 100 mandibular foramina and 18 accessory foramina were observed in the 100 mandible. The mean distance of mandibular foramina to anterior border of ramus is 14.63±3.16 (R) mm and 15.31±3.11 mm(L), to posterior border is (R):12.34±3.10 mm and (L):13.51±3.92 mm, to mandibular notch is (R):21.23±4.56 mm and (L):21.16±3.12 mm, to angle of mandible (R):22.14±3.18 mm and (L):22.1±4.12 mm, to posterior border of 3<sup>rd</sup> molar socket is (R):14.37±3.16 mm and (L):19.26±2.57 mm.

**Conclusion:** The present study on the precise location of mandibular foramen and on the incidence of accessory mandibular foramen will help the dental surgeons for more successful anesthesia and to perform safer surgeries on the ramus of mandible.

**KEY WORDS:** Mandibular Foramen, Inferior Alveolar Nerve Block, Mandibular Notch.

**Address for Correspondence:** Dr. Gopalakrishna. K, Assistant Professor, Department of Anatomy, Malabar Medical College and Research Centre, Modakkallur, Atholi, Kozhikode - 673315, Kerala, India. Ph: 09747059273 **E-Mail:** drgkport@gmail.com

### Access this Article online

Quick Response code



DOI: 10.16965/ijar.2016.122

**Web site:** International Journal of Anatomy and Research  
ISSN 2321-4287  
[www.ijmhr.org/ijar.htm](http://www.ijmhr.org/ijar.htm)

Received: 28 Jan 2016      Accepted: 12 Feb 2016  
Peer Review: 29 Jan 2016      Published (O): 29 Feb 2016  
Revised: None                      Published (P): 29 Feb 2016

## INTRODUCTION

Mandibular foramen is an irregular foramen located just above the center of the medial surface of the ramus of the mandible. Mandibular foramen is leading to mandibular canal through which inferior alveolar nerve and vessels will transmit and supply the teeth of lower jaw [1]. Inferior alveolar nerve block is a common anesthetic procedure prior to dental surgeries on lower jaw. The success of this technique highly depends on the needle tip to the MF at the time of anaesthetic injection [3]. Failure in Mandibular anesthesia and injury to neurovascular bundle may be resulted by inaccurate localization of mandibular foramen or by marked variability in their location [2-4]. Usually by palpation of lingual [5] or by using radiographs [6,7] the localization of foramen is done. Hence this study is aimed to locate the mandibular foramen and its distances from different bone landmarks on internal surface of ramus of dry mandible. As the dry mandibles were obtained from Malabar medical college Calicut, the study gives the position of mandibular foramen in the local population.

## MATERIALS AND METHODS

This descriptive study was performed with the approbation by the Institutional Ethical Committee of Malabar Medical College and Research Centre, Calicut (MMCRC/IEC/2013/ dated 04.11.2013). A total of 100 dentulous adult dry human mandibles of unknown sex and age were collected and studied in Department of Anatomy, Malabar Medical College and Research, Calicut. Mandibles with sockets for third molar teeth, those regular in shape, and devoid of deformities were selected. The damaged bones and those having pathological abnormalities were excluded. The mandibles were observed for the presence, prevalence rate and laterality of mandibular foramen. Magnifying lens, metallic probe, Vernier calipers of 1/20 mm accuracy were used for taking measurements. Irrespective of shape of lingula, the center of mandibular foramen was taken as reference point. The position of the center of mandibular foramen was measured from various landmarks like,

1. Mandibular notch

2. Anterior border of the ramus of mandible
3. Posterior border of the ramus of the mandible
4. Posterior border of the 3<sup>rd</sup> molar socket.
5. Meeting point of base with posterior border of ramus (Angle of mandible).

Further observation was done for the presence of accessory mandibular foramen. The distances from the mandibular foramen to various bone landmarks were recorded as an average of three independent measurements. The mean and standard deviation were calculated separately for right and left sides and tabulated [8].

## RESULTS

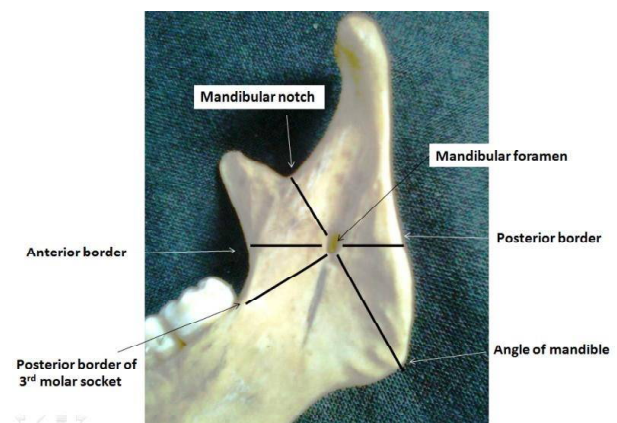
A total of 100 dentulous adult dry human mandibles were studied for the position of mandibular foramen. The minimum, maximum, average and standard deviation values of the various parameters which were studied on either side of the mandible are shown in Table 2.

The mean distance of mandibular foramen from,

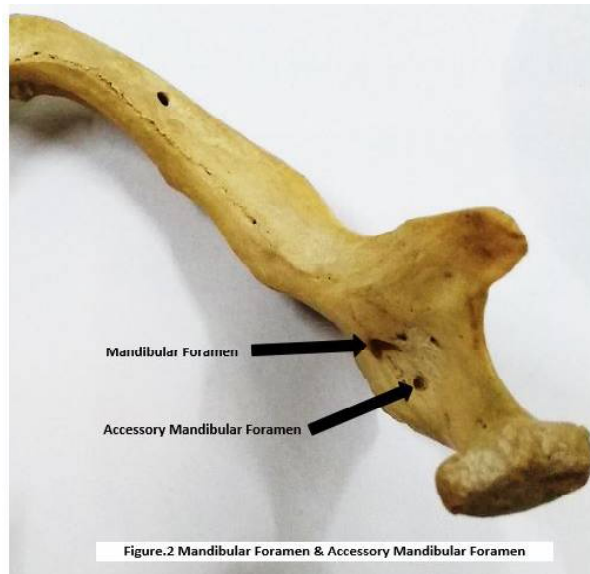1. Mandibular notch is 21.23mm on right side and 21.16 mm on left side
2. Anterior border of the ramus of mandible is 14.63 mm on right side and 15.31 mm on left side
3. Posterior border of the ramus of the mandible is 12.34 mm on right side and 13.51 mm on left side
4. Posterior border of the 3<sup>rd</sup> molar socket is 22.14 mm on right side and 19.26mm on left side
5. Angle of mandible is 22.14 mm on right side and 22.10 mm on left side

Accessory mandibular foramina was observed in the 15 mandible.

**Fig. 1:** Showing the morphological features of the mandible.



**Fig. 2:** Showing the mandibular and accessory mandibular foramen.



**Table 3:** The comparisons of results of different studies on mandibular foramen.

Position of mandibular foramen	Side	Prajnaparamitasa manta et al [9]	Varshasheno y et al [10]	C.Lavanyavar ma et al [11]	Padmavat[hi G et al [12]	Present study
Anterior border to mandibular foramen	Right	15.72±2.92	16.1	16.52	16.8±2.8	14.63±3.16
	Left	16.23±2.88	16.3	16.94	16.9±2.5	15.31±3.11
Posterior border to mandibular foramen	Right	13.29±1.74	11.7	13.35	11.7±2.0	12.34±3.10
	Left	12.73±2.04	11.3	13.46	12.1±2.4	13.51±3.92
Mandibular notch to mandibular foramen	Right	22.70±3.00	23.6	23.39	22.0±3.0	21.23±4.56
	Left	22.27±2.92	23.6	24.41	22.3±3.4	21.16±3.12
Angle of mandible to mandibular foramen	Right	21.54±2.92	-	-	22.6±3.4	22.14±3.18
	Left	21.13±3.43	-	-	22.2±2.9	22.1±4.12
Posterior border of 3 <sup>rd</sup> molar socket to mandibular foramen	Right	-	-	15.6	-	14.37±3.16
	Left	-	-	18.7	-	19.26±2.57

**Table 1:** General findings of present study on mandibular foramen.

Sl.No	Findings	Description	Numbers	Percent	Total
1	Sample size (n=100) mandible	Right	100	100%	100 Bones
		Left	100	100%	
2	Incidence of mandibular foramen.	Right	100	100%	100 Foramina
		Left	100	100%	
3	Incidence accessory foramen	One per bone	18	-	18 Foramina
		Two per bone	0	-	

**DISCUSSION**

The location of mandibular foramen is clinically crucial in achieving inferior alveolar block. Failure of locate neurovascular bundle will result due to inaccurate localization of mandibular foramen. In the present study, the location of the mandibular foramen and its distances from different bony landmarks on mandibles of South Indian origin was done. This study was compared with the studies done in other parts of India and also one study from Pakistan to know any geographical difference.

**Table 2:** Position of mandibular foramen from different bone landmarks.

Sl.No	Position of mandibular foramen	Side	Mean (mm)	Standard deviation	Max-Min (mm)
1	Anterior border to Mandibular foramen	Right	14.63	3.16	12.4-21.5
		Left	15.31	3.11	10.6-20.4
2	Posterior border to Mandibular foramen	Right	12.34	3.1	7.6-14.8
		Left	13.51	3.92	6.8-18.2
3	Mandibular notch to Mandibular foramen	Right	21.23	4.56	18.4-25.1
		Left	21.16	3.12	13.6-26.4
4	Angle of mandible to Mandibular foramen	Right	22.14	3.18	14.3-28.8
		Left	22.1	4.12	13.5-27.4
5	Posterior border of the 3 <sup>rd</sup> molar socket to Mandibular foramen	Right	14.37	3.16	10.7-30.3
		Left	19.26	2.57	10.12-27.28

According to Pragna Paramitha et al [9] study on 60 mandibles from North part of India, the mandibular foramen was located 15.75±2.92 mm (R) and 16.23±2.88mm(L) from the anterior border, 13.29±1.74mm (R) and 12.73±2.04mm (L) from the posterior border. It was positioned 22.7±3.0mm (R) and 22.27±2.62mm (L) from mandibular notch. The distance of mandibular foramen from the angle of mandible was 21.54±2.92mm (R) and 21.13±3.43mm (L).

Karan Shah et al [10] studied on 100 human mandibles from Ahmadabad and found the average distance of mandibular foramen was 23-25mm from mandibular notch, 16-18mm from anterior border, 12-13mm from posterior border and 27-30mm from the angle of mandible.

A study done on mandibles from South Indian population by C. Lavanya Varma et al [11], the following observations were made. The average

PadmavathiG et al [12] studied on mandibles from South Indian population found that the distance of mandibular foramen from various landmarks are 16.9±2.5mm (R), 16.8±2.8mm (L) from anterior border; 12.1±2.4mm (R), 11.7±2.0 (L) from posterior border; 22.3±3.4mm (R), 22.0±3.0 (L) from mandibular notch; 22.2±2.9mm (R), 22.6±3.4 (L) from the angle of mandible.

Another study from Pakistan by AsmoSaher Ansari et al [13] on 152 panoramic radiograph of mandibles, it was found that mean distance from mandibular foramen to anterior border was 17.69±0.61mm on right side, 17.65±0.63mm on left side in females and was 17.55±0.68mm on right side, 17.56±0.81mm on left side in males. From posterior border it was 12.03±1.02mm on right side, 11.84±0.70mm on left side in females and was 12.66±1.23mm on right side, 12.52±1.84mm on left side in males. From mandibular notch the distance was 20.51±0.92mm on right side, 21.03±0.90mm on left side in females and was 20.45±1.02mm on right side, 21.28±0.85mm on left side in males.

The values recorded in the present study on 100 mandibles on South Indian population maintains bilateral symmetry which is in parallel to other studies. The geographical difference in the position of MF was ruled out in this assessment by considering studies from South and North Indian population with the present study. Further it was assessed with study from Pakistan population [9-13].

Single accessory mandibular foramina was observed in 18% of the cases. The reported cases of accessory mandibular foramina is less. Other South Indian study reported 16.5% of the cases. The presence of accessory mandibular foramen could be associated with additional branches of inferior alveolar nerve. Branch arising from inferior alveolar nerve proximal to the mandibular foramen or in the infratemporal fossa will transmit through this foramen to supply the 3rd molar teeth [14-17]. Hence it will escape local anesthesia and result with inadequate or failure to achieve nerve block. Also accessory mandibular foramina may provide a route for the spread of infections and tumor following radiotherapy.

## CONCLUSION

Precise localization of mandibular foramen is

clinically very important to achieve effective inferior alveolar nerve block, prior to dental surgeries in the lower jaw like osteotomy, orthognathic reconstruction surgeries of the mandible and dental implant procedures[18] and to avoid injury to the neurovascular contents passing through it. Accessory mandibular foramina will serve as a route for spread of infection and tumor cells [19].The present study concludes that the pinpoint knowledge on the position of mandibular foramen with its normality and laterality is important for planning and conducting dental surgeries, which will help for effective management, better result and prognosis.

**Conflicts of Interests: None**

## REFERENCES

- [1]. Standring S. From Gray's Anatomy, The anatomical basis of clinical practice, 40<sup>th</sup> edition. Churchill livingstone, Elsevier. 2008. Chapter-31, Page 530-533, 595-614.
- [2]. Ennes JP, Medeiros RM. Localisation of the mandibular foramen and its clinical implications. International journal of morphol2009; 27:1305-1311.
- [3]. Shenoy V, Vijayalakshmi S, Saraswathi P. Osteometric analysis of the mandibular foramen in dry human mandibles. Journal of clinical and diagnostic research2012; 6:557-560.
- [4]. Oguz O, Bzkir MG. Evaluation of the location of the mandibular and the mental foramina in dry, young, adult human male dentulous mandibles. West Indian medical journal2002; 51:14-16.
- [5]. Ennes JP, Medeiros RM. Localization of mandibular foramen and clinical implication. Int J Morphol 2009;4:1305-1311.
- [6]. Mbajjorgu EF. A study of the position of mandibular foramen in adult black Zimbabwean mandibles. Central Africa Journal of Medicine 2000;46(7):184-190.
- [7]. Hwang TJ, Hsu SC, Huang QF, Guo MK. Age changes in location of mandibular foramen. ZhonghuaYa Yi XheZaZhi1990;9(3):98-103.
- [8]. B.Burt Gerstman. Basic Biostatistics: Statistics for public health practice. Johnes and Bartlett publications, Inc. Sudbury, Massachusetts 2008. Page 63-84, 210-250.
- [9]. Prajna Paramita Samanta, Poonam Kharb. Morphometric analysis of mandibular foramen and incidence of accessory mandibular foramina in adult human mandibles of an Indian population. Rev Arg de AnatClin2013;5(2):60-66.
- [10]. Kanan Shah, Pratik Shah and Ajay Parmar. Study of the location of mandibular foramina in Indian dry mandibles. Global research analysis 2013;2(7):128-130.

- [11]. Lavanya Varma C, ImtiazulHaq, Rajeshwari T. Position of mandibular foramen In South Indian andibles. *Anatomica Karnataka* 2011;5(1):53-56.
- [12]. Padmavathi G, Suman Tiwari, Varalakshmi KL, Roopashree R. An anatomical study of mandibular and accessory mandibular foramen in dry 2014;13(4):83-88.
- [13]. AsmaSaher Ansari, Imtiaz Ahmed. Localization of the mandibular foramen on the panoramic radiographs 2015;27(3):576-579.
- [14]. Murphy TR, Grundy EM. The inferior alveolar neurovascular bundle at the mandibular foramen. *Dent Pract*1969;20:41-48.
- [15]. Haveman CW, Tebo HG. Posterior accessory foramina of the human mandible. *J Prosthetic Dentistry* 1976; 35: 462-468.
- [16]. Das S, Suri RK. An anatomico-radiological study of an accessory mandibular foramen on the medial mandibular surface. *Folia Morphol* 2004;63:511-513.
- [17]. Jeyaseelan N, Sharma JK. A morphological study of unnamed foramina in the North Indian human mandibles and their possible role in neurovascular transmission. *Int J Oral Surg* 1984;13:239-242.
- [18]. Sloodtwerger PJ, Muller H. Mandibular invasion by squamous cell carcinoma. *J CraniomaxillarySurg* 1989;17:69-74.
- [19]. Fanibunda K, Matthews JNS. Relationship between accessory foramina and tumor spread in the lateral mandibular surface. *J Anat*1999;195:185-190.

**How to cite this article:**

Gopalakrishna. K, Deepalaxmi S, Somashekara S.C, Rathna B.S. AN ANATOMICAL STUDY ON THE POSITION OF MANDIBULAR FORAMEN IN 100 DRY MANDIBLES . *Int J Anat Res* 2016;4(1):1967-1971. **DOI:** 10.16965/ijar.2016.122