

A STUDY ON THE LEVEL OF TERMINATION OF TIBIAL NERVE: REVIEW OF LITERATURE AND ITS CLINICAL IMPLICATIONS

Sharma S ^{*1}, Wadhwa A ², Bhardwaj S ³.

^{*1} Associate Professor, Department of Anatomy, Punjab Institute of Medical Sciences, Jalandhar, Punjab, India.

² Professor Department of Anatomy, Punjab Institute of Medical Sciences, Jalandhar, Punjab, India.

³ Medical Officer, PHC Thariawal, Block Majitha, Amritsar, Punjab, India.

ABSTRACT

Introduction: Variation of nerve is not only of anatomical and embryological interest, but also of clinical importance, as these can be etiological factors behind various pathological conditions. Likewise, their adequate knowledge will help in increasing surgical precision and decreasing morbidity. In present study level of division of tibial nerve into medial and lateral plantar nerve was studied.

Material and Methods: The material for the present study comprised of 60 lower extremities belonging to 30 adult human cadavers obtained from Dept of Anatomy, GMC, Amritsar. Tibial nerve was dissected and the level at which it divided into medial and lateral plantar nerve was studied.

Result: Tibial nerve bifurcated into medial and lateral plantar nerve deep to flexor retinaculum in 93.33% of cases and proximal to flexor retinaculum in 6.67% of cases.

Discussion: There are various clinical conditions associated with the involvement of tibial nerve. It is reported that an accessory flexor digitorum muscle is associated with high division of tibial nerve. Accessory flexor digitorum muscle can be one of causes of tarsal tunnel syndrome.

Anatomical studies of the tibial nerve in the distal third of the leg and at the level of the tarsal tunnel began to take more importance with the establishment and definition of compression pathology of this nerve, in its osteofibrous tunnel. In an analogy with the upper limb, this syndrome resembles carpal tunnel syndrome, also sharing decompression surgery as one of the therapeutic approaches.

KEY WORDS: Tibial Nerve, Medial Plantar Nerve, Lateral Plantar Nerve, Flexor Retinaculum, Accessory Flexor Digitorum Muscle.

Address for Correspondence: Dr. Sherry Sharma, Associate Professor, Department of Anatomy, Punjab Institute of Medical Sciences, Jalandhar, Punjab, India. Ph: 9872830406

E-Mail: bhardwajsherry2@gmail.com

Access this Article online

Quick Response code



DOI: 10.16965/ijar.2016.109

Web site: International Journal of Anatomy and Research
ISSN 2321-4287
www.ijmhr.org/ijar.htm

Received: 11 Jan 2016 Accepted: 29 Jan 2016
Peer Review: 11 Jan 2016 Published (O): 29 Feb 2016
Revised: None Published (P): 29 Feb 2016

INTRODUCTION

Tibial nerve, the larger sciatic division (from the ventral branches of the fourth and fifth lumbar and first to third sacral ventral rami), descends along the back of the thigh and popliteal fossa

to the distal border of popliteus, passing anterior to the arch of soleus with the popliteal artery and continuing into the leg. In the thigh, it is overlapped proximally by the hamstring muscles, but becomes more superficial in the

popliteal fossa, where it is lateral to the popliteal vessels, becoming superficial to them at the knee and crossing to the medial side of the artery. Distally in the fossa it is overlapped by the junction of the two heads of gastrocnemius. In the leg, the tibial nerve lies deep to the soleus and gastrocnemius, its distal third is covered only by skin and fasciae. At first medial to the posterior tibial vessels, it crosses behind them, descending lateral to them until it bifurcates. It lies on the tibialis posterior for most of its course except distally, where it adjoins the posterior surface of the tibia. It courses beneath the flexor retinaculum and here its terminal branches medial and lateral plantar nerves arise [1].

There are various clinical conditions associated with the involvement of tibial nerve [2]. Increased tibial nerve tension plays role in pathophysiology of tarsal tunnel syndrome, then this needs to be considered for treatment of patients with this syndrome [3]. The knowledge of anatomic variations also helps to explain discrepancies between the clinical examinations and electrophysiological tests as to the location of neuronal lesions [4].

MATERIALS AND METHODS

The material for the present study comprised of 60 lower extremities belonging to 30 (well embalmed) adult human cadavers of known sex obtained from the Department of Anatomy, Government Medical College, Amritsar. The tibial nerve and its branches were exposed as per the dissection steps provided by Cunningham's Manual of Practical Anatomy [5].

RESULTS

Termination of tibial nerve

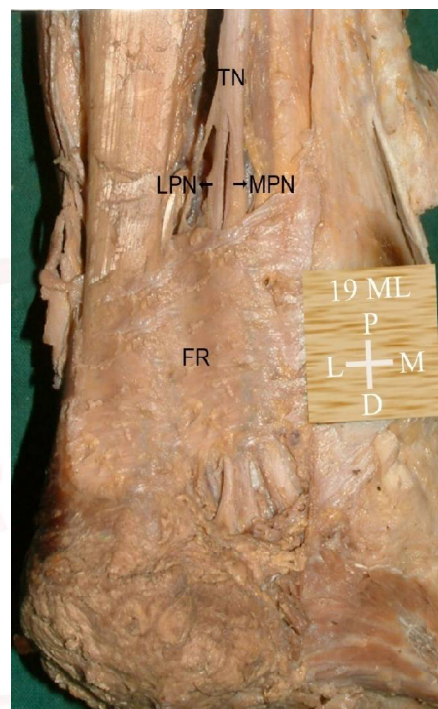
Mode: In the present study, where classical text book description was true, the tibial nerve bifurcated into medial and lateral plantar nerve in all the limbs.

Level: In the present study, in 56 (93.33%) limbs (28 on right and 28 on left), the tibial nerve divided deep to flexor retinaculum and in 4 (6.67%) limbs (2 on right and 2 on left), it divided proximal to flexor retinaculum. (Table 1) Figure 1 showing bifurcation of tibial nerve above flexor retinaculum.

Table 1: Level of termination of tibial nerve.

Level of bifurcation of tibial nerve	No. of limbs with particular level of bifurcation of tibial nerve [n (%)]		
	Right 30(100%)	Left 30(100%)	Total 60(100%)
Deep to flexor retinaculum	28(93.33%)	28(93.33%)	56(93.33%)
Proximal to flexor retinaculum	02(06.67%)	02(06.67%)	04(06.67%)

Fig. 1: Showing bifurcation of tibial nerve proximal to flexor retinaculum.



TN – Tibial Nerve, LPN – Lateral Plantar Nerve, MPN – Medial Plantar Nerve, FR – Flexor Retinaculum

DISCUSSION

Table 2: Comparison of level of bifurcation of tibial nerve.

Author	Year	% of no. of limbs with particular level of termination of tibial nerve [n (%)]	
		Deep to flexor retinaculum	Proximal to flexor retinaculum
Dellon & Mackinnon [7]	1984	95.00%	5.00%
Havel et al [8]	1988	93.00%	7.00%
Davis and Schon [9]	1995	90.00%	10.00%
Lousia and Masquelet [6]	1999	73.00%	27.00%
Present Study	2008	93.33%	6.67%

Lousia and Masquelet (1999) [6] reported that in 73% limbs tibial nerve bifurcated in the tarsal tunnel.

Dellon and Mackinnon (1994) [7] reported 95% of such cases. Havel et al (1988) [8] found it to be 93%.

Davis and Schon (1995) [9] found it to be 90%.

Bareither et al (1990) [10] identified the bifurcation more proximally in upto 31 % of the feet studied. Torres and Ferreira (2012) [11] found that the tibial nerve bifurcation occurred under the tunnel in 88% of the cases and proximally in 12%.

In the present study, the relative percentages of level of bifurcation of tibial nerve are in comparison to the earlier studies. (Table 2)

Kurtoglu et al (2001) [12] reported that an accessory flexor digitorum muscle was associated with high division of tibial nerve. This finding could not be found in present study due to small sample of lower limbs.

Sammarco and Conti (1994) [13] quoted a rare anomaly of a non terminating tibial nerve which was associated with tarsal tunnel syndrome. The branches of medial and lateral plantar nerve as well as medial calcaneal nerve, nerve to abductor digiti minimi and motor branches to abductor hallucis and to joints, vessels and skin took origin directly from tibial nerve. Surgeons should be aware of this anomaly to avoid inadvertent cutting of nerve branch, they assume to be of a non critical nature.

CONCLUSION AND CLINICAL IMPLICATIONS

There are various clinical conditions associated with the involvement of tibial nerve. The tibial nerve is one of the terminal branches of sciatic nerve and forms its largest component. There is involvement of tibial nerve in various clinical conditions as poliomyelitis, nerve compression syndromes, tuberculosis, idiopathic heterotopic ossification and leprosy. Leprosy affects tibial nerve in a scattered way from distal part of sciatic nerve to exit of tarsal tunnel. Interfascicular, microsurgical neurolysis is beneficial in its treatment provided it is performed on all the affected nerve segments [2].

As an evolutionary integral part of diabetes mellitus, neuropathies appear as diverse entities. As final consequences in its physiopathology, there is the occurrence of edema and loss of neuronal elasticity, entailing alteration in the conductivity of nerve impulses and a greater propensity to compression at specific anatomic sites. The compression syndrome known as tarsal tunnel syndrome is initially described by Kopell and Thompson [14]. The

observation that tarsal tunnel syndrome, considered rare in the population in general, could appear in an increasingly large population, undoubtedly augments the number of candidates to interventions in an area with anatomy subject to variations.

The importance of this fact, also observed by other authors, appears to be related to a greater propensity to the development of tarsal tunnel syndrome in these cases, due to the presence of a larger cross-sectional area represented by the nerve already bifurcated in a narrow, rigid osteofibrous structure [11].

Increased tibial nerve tension plays role in pathophysiology of tarsal tunnel syndrome, then this needs to be considered for treatment of patients with this syndrome [3]. Selective tibial neurotomy is indicated to improve muscle imbalance of spastic ankle. There is an improvement of clinical and electrophysiological spastic indices. Neurotomy acted not only on motor neurons by decreasing strength but also the reflex enlargement by decreasing sensory afferent [15]. As documented, the anatomic variations in level at which sciatic nerve divides into tibial and common peroneal nerve have been suspected as a possible cause for incomplete block of sciatic nerve and popliteal fossa. Level at which sciatic nerve divides in popliteal fossa is essential to determine the optimal distance from popliteal crease for injection of local anaesthetic agent to produce popliteal block. Tip of the needle ideally should be positioned next to main trunk of sciatic nerve before its separation into tibial and common peroneal nerve.

Injection of local anaesthetic agent in vicinity of only one of these components may result in an incomplete block. Similarly the knowledge of the level at which tibial nerve divides into medial and lateral plantar nerve is essential [16]. Also this block provides effective analgesia after foot and ankle surgery in children [17]. As mentioned earlier there can be non terminating tibial nerve which was associated with tarsal tunnel syndrome. Proximal bifurcation may predispose to tarsal tunnel syndrome and its infrequent occurrence correlates with infrequent clinical diagnosis [8]. The branches of medial and lateral plantar nerve as well as medial

calcaneal nerve, nerve to abductor digiti minimi and motor branches to abductor hallucis and to joints, vessels and skin took origin directly from tibial nerve. Surgeons should be aware of this anomaly to avoid inadvertent cutting of nerve branch, they assume to be of a non critical nature [13]. The knowledge of anatomic variations also helps to explain discrepancies between the clinical examinations and electrophysiological tests as to the location of neuronal lesions [4].

Conflicts of Interests: None

REFERENCES

- [1]. Williams PL, Bannister LH, Berry MM, Collins P, Dyson M, Dussek LE et al. The Nervous System. Berry MM, Mstrandring S, Bannister LH. In: Gray's Anatomy. 38th Edition. Edinburgh, London: Churchill Livingstone; 1995;1282-1288
- [2]. Richard B, Khatri B, Knoll E, Lucas S, Turkof E. Leprosy affects the tibial nerve diffusely from the middle of thigh to the sole of the foot, including skip lesions. *Plast Reconstr Surg* 2001; 107(7): 1717-1724.
- [3]. Lau J, Daniels TR. Effects of tarsal tunnel release and stabilization procedures on tibial nerve tension in a surgically created pes planus foot. *Foot Ankle Int* 1998;19(11):770-777.
- [4]. Davis TJ, Schon LC. Branches of tibial nerve: anatomic variation. *Foot Ankle Int* 1995;16(1):21-29
- [5]. Romans GJ. The popliteal fossa, back of thigh, leg and foot. In: Cuninghams Manual of Practical Anatomy. 15th Edition. Edinburgh, London: Book Society and Oxygen University Press; 1986;(3):160-214.
- [6]. Louisia S, Masquelet AC. The medial and inferior calcaneal nerves; an anatomic study. *Surg Radiol Anat* 1999;21:169-173.
- [7]. Dellon AL, Mackinnon SE. Tibial nerve branching in tarsal tunnel. *Arch Neurol* 1984;41:645-646.
- [8]. Havel PE, Ebraheim NA, Clark SE, Jackson WT, Didio L. The tibial nerve branching in tarsal tunnel. *Foot Ankle* 1988;9:117-119.
- [9]. Davis TJ, Schon LC. Branches of tibial nerve and anatomic variation. *Foot Ankle Int* 1995;16:21-29.
- [10]. Bareither DJ, Genau JM, Massaro JC. Variation in the division of the tibial nerve: application to nerve blocks. *The Journal of foot surgery* 1990;29(6):581-3.
- [11]. Torres ALG, Ferreira MC. Study of the anatomy of the tibial nerve and its branches in the distal medial leg. *Acta Ortop Bras* 2012;20(3):157-164.
- [12]. Kurtoglu Z, Uluutku MH, Can MA, Onderoglu S. An accessory flexor digitorum longus muscle with high division of tibial nerve. *Surg Radiol Anat* 2001;23(1):61-63.
- [13]. Sammarco GT, Conti SF. Anomalous tibial nerve: a case report. *Clin Orthop Relates Res* 1994;305:239-241.
- [14]. Kopell HP, Thompson WA. Peripheral entrapment neuropathies of the lower extremity. *N Engl J Med*. 1960;262:56-60.
- [15]. Feve A, Decq P, Filipetti P, Verroust J, Harf A, N' Guyen JP et al. Physiological effects of selective tibial neurotomy on lower limb spasticity. *J Neurol Neurosurg Psychiatry* 1997;63(5):575-8.
- [16]. Vloka JD, Hadzic A, April E, Thys DM. The division of sciatic nerve in the popliteal fossa: Anatomical implications for popliteal nerve blockade. *Anesth Analg* 2001;92: 215-217.
- [17]. Tobias JD, Mencia GA. Popliteal fossa block for post-operative analgesia after foot surgery in infants and children. *J Pediatr Orthop* 1999;19(4):511-514.

How to cite this article:

Sharma S, Wadhwa A, Bhardwaj S. A STUDY ON THE LEVEL OF TERMINATION OF TIBIAL NERVE: REVIEW OF LITERATURE AND ITS CLINICAL IMPLICATIONS. *Int J Anat Res* 2016;4(1):1901-1900.
DOI: 10.16965/ijar.2016.109