

ANOMALOUS BICIPITAL ORIGIN OF FLEXOR CARPI RADIALIS MUSCLE: A CADAVERIC STUDY

Madhumita Datta ¹, Phalguni Srimani ^{*2}, Nabanita Chakraborty ³, Alpana (De) Bose ⁴.

¹ Demonstrator, Department of Anatomy, ESIC Medical College, Joka, Kolkata, India.

^{*2} Demonstrator, Department of Anatomy, Calcutta National Medical College, Kolkata, India.

³ Junior Resident, Department of Anatomy, R. G. Kar Medical College, Kolkata, India.

⁴ Professor and Head, Department of Anatomy, R. G. Kar Medical College, Kolkata, India.

ABSTRACT

Background: Morphological variations of muscles in the flexor compartment of forearm have been reported by several authors. Flexor carpi radialis (FCR) is a superficial flexor of forearm which is known to present variations regarding its occurrence, origin from unusual sites, presence of additional belly and /or tendon of existing muscle as well as its insertion pattern. The aim of the present study was to document variations of FCR muscle and to establish embryological and clinic-anatomical correlation of such variation.

Methods: The present study was carried out on thirty upper limbs from fifteen cadavers of both sexes of different ages during routine dissection in the department of Anatomy over three years. Presence, absence or any other morphological variations of FCR muscle, its nerve-supply and relation to neighbouring structures were carefully observed.

Results: Study revealed in one upper limb (right) that FCR muscle had an additional head of origin from tendo-aponeurotic junction of biceps brachii muscle. No similar or other variation was observed in other cadavers and even on the contralateral side of the same cadaver.

Conclusion: The variant we observed was explained on embryological background and based on reviewing related literature was documented not only as rare but seemed to be relevant and clinically noteworthy for clinical and radiological diagnosis of neurovascular compression syndrome affecting upper limb distal to cubital fossa and also to surgeons undertaking reconstructive surgeries.

KEY WORDS: Flexor carpi radialis, Variation, Additional head, Tendo-aponeurotic.

Address for Correspondence: Dr. Phalguni Srimani, Department of Anatomy, Calcutta National Medical College, Kolkata - 700032, India. Mobile: +91 9830479835

E-Mail: falgunisreemani@yahoo.co.in

Access this Article online

Quick Response code



DOI: 10.16965/ijar.2016.101

Web site: International Journal of Anatomy and Research
ISSN 2321-4287
www.ijmhr.org/ijar.htm

Received: 01 Jan 2016 Accepted: 29 Jan 2016
Peer Review: 01 Jan 2016 Published (O): 29 Feb 2016
Revised: None Published (P): 29 Feb 2016

INTRODUCTION

Flexor compartment of forearm presents usually five superficial and three deep muscles. The superficial flexor muscles are Pronator teres, Palmaris longus, Flexor carpi radialis, Flexor digitorum superficialis and Flexor carpi ulnaris.

Deep group of flexor muscles include Flexor pollicis longus, Flexor digitorum profundus and Pronator quadratus. FCR muscle is a known flexor of the wrist. The action of FCR in combination with Extensor carpi radialis longus and brevis can cause abduction of wrist also. It usually takes its origin from medial epicondyle of

humerus as common origin of superficial flexors as well as from antebrachial fascia and adjoining fascial septa. After taking origin, the muscle forms fusiform belly from which tendinous part arises about half way down the middle of forearm. The tendon while passing through flexor retinaculum of wrist, lodges in groove on trapezium before its final insertion to palmar surface of base of second and third metacarpal bones. It derives its nerve supply from median nerve while in forearm [1]. Reported variations regarding FCR muscle include its unusual occurrence, attachments, duplication including presence of additional belly and/or tendon and also regarding insertion pattern [2-8]. The aim of present study is to document variations of FCR muscle and analyze anatomical basis of possible clinical and applied entities related to such variations.

MATERIALS AND METHODS

The present study was carried out on thirty upper limbs from fifteen embalmed cadavers of both sexes of different ages during routine dissection for teaching undergraduate students in the department of Anatomy, R. G. Kar Medical College, Kolkata over three years. In this respect, flexor aspect of arm, forearm including wrists were dissected following standard dissection techniques. All the muscles of forearm were exposed. FCR muscles were isolated and carefully observed. Any variations regarding their origin, course, insertion, nerve-supply, relation with neighboring structures were studied. Photographs of observed relevant variations were taken. Then, embryological basis and clinical importance of such variation were stressed upon. Finally, results were compared with other similar type of studies.

RESULTS

Origins of FCR muscle were found to be from medial epicondyle of humerus as common superficial flexors of forearm in all of the cases examined. However, in one case, on right upper limb of an approximately 70 year-old female cadaver, we came across the following unusual findings:

Some muscular slips were seen arising from near the junction of terminal part of tendon of biceps

brachii and bicipital aponeurosis and after passing downwards and medially they got fused inseparably with FCR muscle taking usual origin from medial epicondyle of humerus; thus considered as additional head of FCR muscle. (Figure 1) About half way down the forearm, fused muscle belly was replaced by flat tendon which became cord like at wrist and underwent usual insertion. (Figure 2) In this case, we observed median nerve, terminal part of brachial artery and proximal part of radial artery with its radial recurrent branch passing deep to muscular arch formed by fusion of two heads of FCR muscle. Moreover, we did not find any additional nerve separately supplying such additional muscular slips. No similar or other variation was observed on any other cadaver and not even on contralateral side of upper limb of the same cadaver.

Fig. 1: Showing an additional variant (head) origin of right flexor carpi radialis muscle from tendo-aponeurotic junction (TA) of biceps brachii (BB) muscle [(*) : usual origin, (**): additional head, FCR: Flexor carpi radialis muscle belly after fusion of two heads, BA: terminal part of brachial artery, RA: proximal part of radial artery]

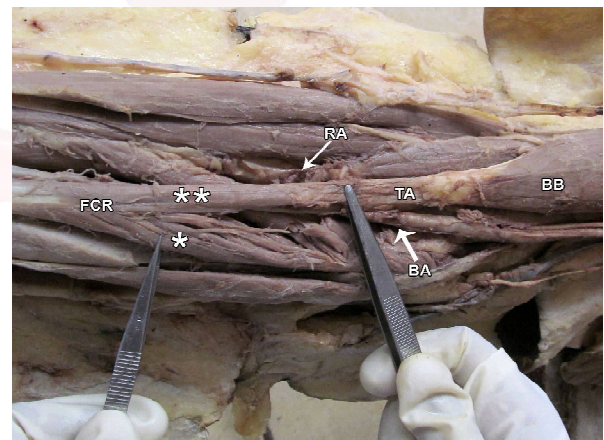


Fig. 2: Showing bulk of right Flexor carpi radialis (FCR) muscle after fusion of two heads subsequently replaced by flat tendon (*) and becoming cord like (**) at wrist.



DISCUSSION

Anatomical variations related to muscles of flexor compartment of forearm have been considered as subjects of many anatomical and radiological studies. It is not uncommon to get the variations related to FCR muscle [2-8]. Both congenital absence [2] and duplication in the form of two separate musculotendinous units, a FCR and a FCRB (flexor carpi radialis brevis) have been reported [4]. Further importance of FCR muscle has been documented and studies have highlighted the use of supernumerary tendons of FCR muscle as interpositional graft during reconstructive surgeries [9, 10]. Accordingly, variant FCR with small belly and long tendon has been reported to be beneficial to surgeons undertaking regional reconstructive surgeries and also to physiotherapists for making better post reconstructive rehabilitation planning [3]. Previous studies have shown that FCR muscle can receive additional slips from biceps tendon, brachialis, coronoid process or anterior oblique line of radius [6]. But very few reports regarding its origin from bicipital aponeurosis has been documented in medical literature [5,7,8]. Bhat et al in 2012 [5] observed variant tendinous slip arising from undersurface of aponeurotic extension of biceps brachii near its tendo aponeurotic bifurcation splitted into two bands, one continued with pronator teres and other joined with FCR. Trivedi et al [8] also reported musculotendinous slip extending from medial side of biceps belly and going for attachment to pronator teres as well as FCR muscles. Moreover, other studies describing variant course and insertion pattern of biceps brachii have been documented that tendinous slip arising from biceps brachii distally merged either with fascia covering flexor carpi ulnaris [11] or presented as additional extension to join with extensor carpi radialis longus muscle [12]. Such variations have been reported as clinically relevant implicating aponeurosis causing median nerve entrapment, compression of brachial artery, pronator syndrome etc. In the present study also, we did not find normal course of bicipital aponeurosis as broad flat medial expansion towards upper part of posterior border of ulna. Rather, we observed muscle slips after arising from tendoaponeurotic

junction of biceps brachii in cubital fossa fused inseparably with FCR muscle taking usual origin without any attachment to pronator teres muscle and it was described as additional head of FCR muscle. Deopujari et al [7] also reported extra muscle fibers originating from bicipital aponeurosis and merging with muscle belly of FCR without attachment to Pronator teres similar to our findings. Additionally, in this study, we observed median nerve, terminal part of brachial artery and proximal part of radial artery with its radial recurrent branch passing deep to muscular arch formed by fusion of two heads of FCR muscle which may become particularly significant in causing compression of those neighboring neurovascular structures. Previous study has also mentioned presence of long communicating branch between musculocutaneous and median nerve along with additional bellies of FCR and pronator teres muscle for which authors described that those additional fibers might have been innervated by communicating nerve [5]. But as we did not get any such communicating nerve branch; so it was thought that additional belly found in our case might be innervated from main motor branch of usual median nerve indicated to supply FCR muscle.

Such anatomical variations can likely be explained on the basis of deviation from regular embryological development of upper limb muscle. During initial stage of development, myogenic precursor cells arise from differentiated ventral muscle mass which is segmental in origin earlier but later on fuse to form a single muscle with loss of some muscle primordial through cell death during differentiation under control of family of transcription factors called myogenic regulatory factors. Thus altered signaling between mesenchymal cells resulting into persistence of cells not undergoing into process of cell death may account for occurrence of such additional muscle slips [13].

CONCLUSION

Though minor differences have been observed between past and present study, knowledge of present study highlighting anatomical variant of FCR muscle seemed to be relevant and clinically noteworthy and it would definitely supplement

the understanding of muscular variations of flexor compartment of upper limb.

ACKNOWLEDGEMENTS

Authors sincerely acknowledge faculties of the Department of Anatomy for their hands of help.

Conflicts of Interests: None

REFERENCES

- [1]. Standring S, Johnson D. Gray's anatomy: The Anatomical Basis of Clinical Practice. 40th ed., Edinburg: Churchill Livingstone (Elsevier); 2008: 845-46.
- [2]. Rumball KM, Tonkin MA. Absence of flexor carpi radialis. J Hand Surg. 1996 Dec 21 (6): 778.
- [3]. Reghunathan D, Satheesha Nayak B, Surendran S, Kumar N, Rao SS. Tendinous flexor carpi radialis: a case report. OA Case Reports 2013 Sep 10; 2 (10): 96-97.
- [4]. Duncan SFM, McCormack RR Jr, Roberts CC. Characteristics of flexor carpi radialis brevis tendon on magnetic resonance imaging and its use in basal joint arthroplasty. Radiology Case Reports. [Online] 2006; 1(1): 24-26.
- [5]. Bhat KMR, Kulakarni V, Gupta C. Additional muscle slips from the bicipital aponeurosis and a long communicating branch between the musculocutaneous and the median nerves. Int J Anat Var. 2012; 5: 41-43.
- [6]. Bergman RA, Thompson SA, Afifi AK, Saadeh FA. Compendium of Human Anatomic Variation: Text, Atlas and World Literature. Baltimore: Urban & Schwarzenberg; 1988: 12.
- [7]. Deopujari R, Quadir N, Athavale S, Gajbhiye V, Kotgirwar S. Variant Bicipital Aponeurosis: A Cadaveric Study. PJSR 2014; 7 (2): 43-46.
- [8]. Trivedi S, Sinha MB, Sharma DK, Rathore M, Siddiqui AU. Abnormal musculotendinous slip from Biceps Brachii to Pronator Teres: A Case Report. IJBAR 2015; 6(01): 64-66.
- [9]. Brunton LM, Wittstadt RA. Thumb carpometacarpal arthroplasty using an absorbable interference screw for flexor carpi radialis ligament reconstruction. Tech Hand Up Extrem Surg. 2011 Jun; 15 (2): 115-118.
- [10]. Gahankari D, Tambwekar S, Rana RE. Flexor carpi radialis opponensplasty. Br J Plast Surg. 1996 Sep; 49 (6): 401-03.
- [11]. Paval J, Mathew JG. A rare variation of the biceps brachii muscle. Indian J Plast Surg. 2006; 39: 65-67.
- [12]. Roy S, Mitra D, Pandey M, Dasgupta H. An aberrant tendo-aponeurotic extension of biceps brachii muscle: a possible factor for neurovascular compression in the antebrachium. Int J Anat Var. 2014;7:91-92.
- [13]. Mooney EK, Loh C. Hand Embryology Gross Morphologic Overview of Upper Limb Development. <http://emedicine.medscape.com/article/1287982-overview> (accessed November 2015).

How to cite this article:

Madhumita Datta, Phalguni Srimani, Nabanita Chakraborty, Alpana (De) Bose. ANOMALOUS BICIPITAL ORIGIN OF FLEXOR CARPI RADIALIS MUSCLE: A CADAVERIC STUDY. Int J Anat Res 2016;4(1):1878-1881. DOI: 10.16965/ijar.2016.101