

## SIZE OF YOLK SAC BY ULTRASONOGRAPHY AND ITS CORRELATION WITH PREGNANCY OUTCOME

Geetanjali Srivastava <sup>\*1</sup>, Mumal Nagwani <sup>2</sup>, Navbir Pasricha <sup>3</sup>, Vineeta Tewari <sup>4</sup>, M.S. Siddiqui <sup>5</sup>, Eti Sthapak <sup>6</sup>.

<sup>\*1</sup> Junior resident IIIrd year, Department of Anatomy, Era's Lucknow medical college, Lucknow, Uttar Pradesh, India.

<sup>2</sup> Assistant Professor, Department of Anatomy, Era's Lucknow Medical College, Lucknow, Uttar Pradesh, India.

<sup>3</sup> Professor, Department of Anatomy, Era's Lucknow Medical College, Lucknow, Uttar Pradesh, India.

<sup>4</sup> Professor, Department of Anatomy, Era's Lucknow Medical College, Lucknow, Uttar Pradesh, India.

<sup>5</sup> Professor, Department of Anatomy, Era's Lucknow Medical College, Lucknow, Uttar Pradesh, India.

<sup>6</sup> Assistant Professor, Department of Anatomy, Era's Lucknow Medical College, Lucknow, Uttar Pradesh, India.

### ABSTRACT

**Introduction:** The yolk sac is the first extra embryonic structure that becomes sonographically visible within the gestational sac and acts as the primary route of exchange between the human embryo and the mother before the placental circulation is established. The yolk sac is a round structure that is made up of an anechoic center bordered by a regular well-defined echogenic rim. It is usually 2-5 mm in diameter. The yolk sac appears at 6 weeks, thereafter increases in size, attains its maximum diameter at 10 weeks and then it starts decreasing in size. It disappears at 12 weeks. Aims and Objectives of the present study is to measure the size of yolk sac in pregnancies of duration 6-12 weeks by Transvaginal sonography and also to measure the inner diameter of yolk sac and correlate it with pregnancy outcome.

**Materials and Methods:** We studied 72 pregnant women of duration 6-12 weeks referred by Department of Obstetrics and Gynaecology. The inner diameter of yolk sac was measured by Transvaginal sonography and its correlation with pregnancy outcome was studied.

**Observations and Results:** The mean yolk sac diameter was noted as  $3.7 \pm 1.8$  mm. The diameter of the smallest yolk sac was 1.25 mm and that of the largest was 8.96 mm. Yolk sac size was normal in 62 (88.57%) cases, it was smaller in size in one (1.4%) case. Further in another 7 (10%) cases, the yolk sac was found to be abnormally enlarged. In these cases where yolk sac was either enlarged or smaller in size, gestation terminated into abortion.

**KEY WORDS:** Yolk sac, Gestational sac, Yolk sac diameter, Transvaginal sonography, Pregnancy outcome.

**Address for Correspondence:** Dr. Geetanjali Srivastava, Junior resident IIIrd year, Department of Anatomy, Era's Lucknow medical college, Lucknow-226003, Uttar Pradesh, India. 9792171135, E-Mail: [srivastavageetanjali2012@gmail.com](mailto:srivastavageetanjali2012@gmail.com)

### Access this Article online

#### Quick Response code



DOI: 10.16965/ijar.2016.135

**Web site:** International Journal of Anatomy and Research  
ISSN 2321-4287  
[www.ijmhr.org/ijar.htm](http://www.ijmhr.org/ijar.htm)

Received: 04 Feb 2016      Accepted: 18 Feb 2016  
Peer Review: 04 Feb 2016    Published (O): 31 Mar 2016  
Revised: None                Published (P): 31 Mar 2016

## INTRODUCTION

The yolk sac is the first extra embryonic structure that becomes sonographically visible within the gestational sac and acts as the primary route of exchange between the human embryo and the mother before the placental circulation is established. It provides nutritional, metabolic, endocrine, immunologic, and hematopoietic functions during organogenesis in embryonic life, and is considered to reach its highest level of functional activity between the 4th and 7th week of embryonic development [1].

The yolk sac is a critical landmark that identifies a true gestational sac [2]. Sonography shows the yolk sac as a round structure that is made up of an anechoic center bordered by a regular well-defined echogenic rim. The diameter of a yolk sac is usually 2-5 mm and increases in size up to the 10<sup>th</sup> week of gestation [3]. Transvaginal sonographic diagnosis of a blighted ovum is certain when the mean gestational sac diameter exceeds 8 mm without a yolk sac or when the mean gestational sac diameter exceeds 16 mm without an embryo. Transabdominally, a gestational sac greater than 20 mm without a yolk sac or 25 mm without an embryo is diagnostic of a blighted ovum [4].

The threatened and spontaneous abortions together present the most common complications of early pregnancy. Only 1/3 of the total number of conceived embryos continue further development [5]. As far as yolk sac is concerned, its enlarged or small size is also correlated with spontaneous abortion. But the studies on yolk sac size yields a conflicting result. According to some studies, pregnancy has a poor outcome if enlarged or small yolk sac is present. Whereas according to few studies, a pregnancy can have a normal outcome in spite of presence of enlarged or small yolk sac. Therefore, its effects on gestational outcome requires further investigation. Thus, the purpose of the present study is to evaluate the yolk sac size and to correlate it with pregnancy outcome.

Present study carried out with an aim and objective to measure the inner diameter of yolk sac in pregnancies of duration 6 - 12 weeks by Transvaginal sonography, Correlate it with preg-

nancy outcome and to compare the results with those of previous studies.

## MATERIALS AND METHODS

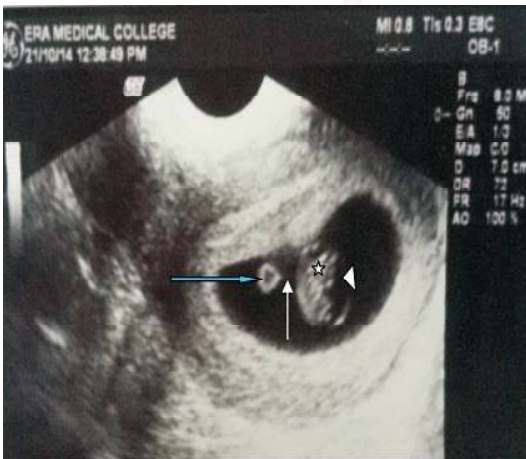The present study was carried out on 72 patients in the Department of Anatomy in collaboration with Department of Radiology & Department of Obstetrics and Gynaecology at Era's Lucknow Medical College and Hospital, Lucknow, India. All pregnant women in their first trimester of pregnancy referred by Department of Obstetrics for transvaginal sonography were recruited for the study on the basis of inclusion/exclusion criteria. Detailed history was taken to rule out medical and surgical illnesses which could affect our study. Thorough general and physical examination was done. Uncomplicated, singleton pregnancy belonging to gestational age between 6-12 Weeks were included for the study where as women with structural anomalies of uterus and cervix, known medical disorders causing abnormal pregnancy outcome i.e. patients with Anemia, Hyperthyroidism, Diabetes mellitus, Chronic hypertension, Molar pregnancy and patients refusing for transvaginal sonography, who were unwilling for follow up.

**Scanning technique:** Informed consent was taken for the performance of transvaginal scan from all study subjects. The machine used was Logiq Pro 5 by GE Healthcare with a TVS probe of 7-12 MHz. The sonography was done with empty bladder. The procedure was explained in detail to the patient and consent was taken. The endovaginal transducer was covered with a sterile condom lubricated with gel before insertion. The patient was placed in the lithotomy position with a slight reversed trendelenburg tilt. The patient was asked to relax the pelvic muscles. The transducer was inserted approximately 6-8 cm into the vagina. Scanning was done in both coronal and sagittal planes. A systematic approach was used for performing TVS. First the uterus was scanned, then the adnexa, and finally the cul-de sac. The gestational sac and yolk sac were identified (Figure 1). The inner yolk sac diameter was measured by placing calipers at inner margin (Figure 2). The range of normal diameter was considered to be 2-5 mm. A large yolk sac was

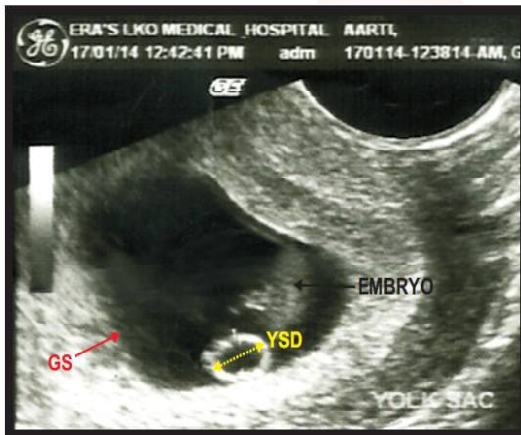
defined as a yolk sac with a diameter  $\leq 5$  mm and small with a diameter  $<2$  mm. The patients were followed till 20 weeks of gestation and were considered as normal pregnancy outcome if pregnancy continued beyond 20 weeks and abnormal outcome if they ended in abortion.

**Ethical consideration:** For the present study, clearance was obtained from the ethical committee of the Institution.

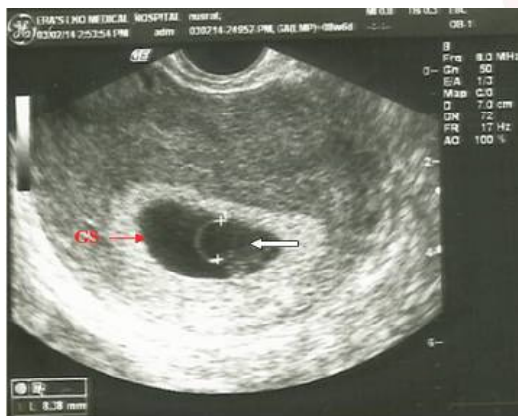**Fig. 1:** Showing ultrasonographic picture of Gestation sac (pink arrow), amniotic sac (arrow head), yolk sac (blue arrow), developing embryo (star) and vitelline duct (white arrow).



**Fig. 2:** Showing sonographic measurement of inner YSD.



**Fig. 3:** Showing ultrasonographic picture of a large yolk sac (white arrow).



**OBSERVATIONS AND RESULTS**

Out of 72 cases, yolk sac was seen in 70 cases (97.22%) and in two cases (2.78%), it was absent (Table 1). In GA of 6-11 weeks, the total mean  $\pm$  S.D. of YSD was  $3.7 \pm 1.8$  mm. Individual mean  $\pm$  S.D for each category of GA from 6-11 weeks were  $3.19 \pm 1.7$ mm,  $3.7 \pm 2.1$ mm,  $3.5 \pm 0.87$  mm,  $4.1 \pm 1.9$ mm,  $4.5 \pm 2.7$ mm and  $3.3 \pm 0.3$ mm respectively (Table 2). Though the p-value is non-significant (0.727), but we found increasing trend of YSD up till 10 weeks. Afterwards, YSD decreased. While yolk sac size was normal in 62 (88.57%) cases, it was smaller in size in one (1.4%) case (Table 3 and Graph 1). Further in another 7 (10%) cases, the yolk sac was found to be abnormally enlarged (Figure 3). In the cases where yolk sac was either enlarged or smaller, gestation terminated into abortion (Table 4 and Graph 2). In addition, 1 case where the size of yolk sac was normal, gestation had also resulted into abortion (because it was irregular in shape). The p-value is  $<0.001$ . This shows that the correlation between yolk sac size and pregnancy outcome is highly significant.

**Table 1:** Showing prevalence of yolk sac in study population.

Yolk Sac	(n)	%
Present	70	97.22
Absent	2	2.78
Total	72	100

**Table 2:** Showing Yolk Sac Diameter (YSD) in millimeters with respect to Gestational age in weeks.

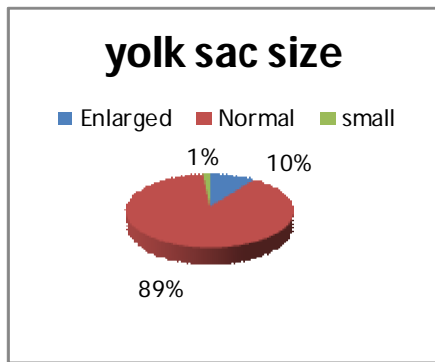
Gestational age in weeks	(n)	Range of YSD (mm)	Mean $\pm$ Std. Deviation (mm)	p value
6	13	1.25-7.90	$3.19 \pm 1.7$	0.727
7	23	1.5-8.96	$3.7 \pm 2.1$	
8	14	1.6-4.78	$3.5 \pm 0.87$	
9	13	2.04-8.38	$4.1 \pm 1.9$	
10	4	2.78-8.56	$4.5 \pm 2.7$	
11	3	2.92-3.48	$3.3 \pm 0.3$	
Total	70	1.25-8.96	$3.7 \pm 1.8$	

**Table 3:** Showing distribution of yolk sac size.

Yolk sac size	Frequency (n)	Percentage (%)
Enlarged	7	10
Normal	62	88.57
Small	1	1.4
Total	70	100



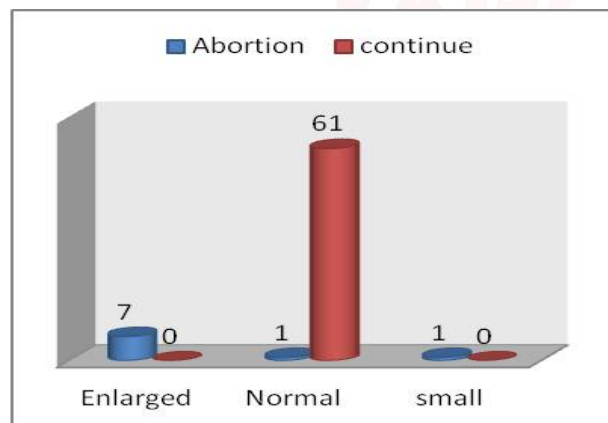**Graph 1:** Showing distribution of yolk sac size.



**Table 4:** Showing correlation of yolk sac size with outcome.

Yolk sac size	Outcome		Total	p value
	Abortion	Continued beyond 20 weeks		
Enlarged	7	0	7	<0.001
Normal	1	61	62	
Small	1	0	1	
<b>Total</b>	<b>9</b>	<b>61</b>	<b>70</b>	

**Graph 2:** Bar graph showing distribution of yolk sac size with gestation outcome.



## DISCUSSION

The present study demonstrates the fact that visualization of yolk sac is crucial for a normal pregnancy outcome and the yolk sac was not visualized in 2.78% of the cases. In studies carried by Xie YJ et al [6], non visualization of yolk sac was reported in 0.67% cases, which is much lower than what has been seen in the present study. While in the studies done by Heller R et al [7], Jose L et al [8], Moradan S et al [9] and Shetty AS et al [10] different percentages of non-visualization of the yolk sac were found as 11%, 20.3%, 4.54% and 4.3% respectively which were much higher than our

findings. Similar findings were reported by Heller R et al [7], Jose L et al [8] and Sanam Moradan et al [9]. Thus, these studies strongly support the findings of the present study, that a yolk sac should always be present in normal pregnancies. Contrary to the present study, Kurtz AB et al<sup>2</sup> and Shetty AS et al [10] depicted the fact that detection of the yolk sac is not an early predictor of pregnancy outcome and they concluded that the absence of the yolk sac was not consistently predictive of a spontaneous abortion. In the present study all cases with absent yolk sac ended up in abortion, while in the study done by Shetty AS et al [10], only 75% of the cases with absent yolk sac ended in spontaneous abortions. 11.43% of the cases showed abnormalities in yolk sac size in the present study. Approximately, similar data were reported by Küçük T et al [3] and Adija P et al [11] according to whom 11.2% cases and 10% cases had abnormal size of the yolk sac and in the study by Jose L et al [8], 5.6% cases had abnormal size of the yolk sac.

In the present study in 88.89% of the cases abortion took place due to abnormal size of the yolk sac, while in the study carried by Küçük T et al [3] and Adija P et al [11], abortions due to abnormal yolk sac size occurred in 64.5% and 35.71% respectively. These percentages are much lower than the present findings. The reason behind the differences in findings may be the smaller sample size of the present study. The enlarged yolk sac was responsible for 77.78% of the abortions in the present study, while in the study carried by Tan S et al [12] and Adija P. et al [11] miscarriage occurred in 37.5% and 80% of the cases respectively in which enlarged yolk sacs were present.

In the present study, none of the cases having enlarged yolk sac size continued beyond 20 weeks. This finding is not in accordance with the findings of Küçük T et al. [3] and Berdahl DM et al [13], They reported that 28.57% and 66.25% of the cases, which had enlarged yolk sac terminated into normal outcome respectively. According to Malinowski W et al [14], the visualization of a large size yolk sac is a predictor of poor pregnancy outcome. In agreement with the above studies, the results of study

by Moradan S et al [9] also showed that yolk sac size was an important factor for prediction of spontaneous abortion. Thus it is in agreement with the present study.

In contrast, a study by Cho FN et al [15] has mentioned the existence of a very large yolk sac (with a diameter of 8.1 mm) in a normal live pregnancy. Thus, this is also not according to the previous studies as all the cases with enlarged size aborted and in all cases in which pregnancy continued, none yolk sac had an enlarged diameter.

In the present study, small size yolk sac was found in 1.4% of cases. The data given by Adija P et al [11] are similar to the present study i.e. 1.4% whereas, the findings of Jose L et al [8] are slightly higher (3.7%).

11.11% of the cases of the present study aborted because of small yolk sac size. In the study by Adija P et al [11], a small yolk sac was related with a higher percentage (40%) of abortions. A further study with a larger sample size can be undertaken to confirm the co-relation found in the present study. We found that a smaller yolk sac diameter than expected for any gestational age is a predictor of poor pregnancy outcome and this fact is in agreement with the conclusion given by Varelas FK et al [16] in their study.

## CONCLUSION

The present study attempted to evaluate the size of yolk sac and its correlation with pregnancy outcome. Out of 72 cases, yolk sac was seen in 70 cases (97.22%) and in two cases (2.78%), it was absent. The mean yolk sac diameter was noted as  $3.7 \pm 1.8$  mm. The diameter of the smallest yolk sac was 1.25 mm and that of the largest was 8.96 mm. Yolk sac sizes was normal in 62 (88.57%) cases, it was smaller in size in one (1.4%) case. Further in another 7 (10%) cases, the yolk sac was found to be abnormally enlarged. In few cases where yolk sac was either enlarged or smaller in size, gestation terminated into abortion. The p-value is  $< 0.001$ , showing a highly significant correlation between yolk sac size and pregnancy outcome. Abnormalities of the yolk sac size can be used as a good predictive indicator of early pregnancy loss, even before fetal morphology can be

studied sonographically. Thus, in the era of artificial reproductive techniques, this parameter may be used as good tool in clinical practice to predict whether a pregnancy is going to have a good or a poor outcome.

## ABBREVIATIONS:

**GS** - Gestational Sac

**YSD** - Yolk Sac Diameter

**GA** - Gestational Age

**TVS** - Trans Vaginal Sonography

**S.D** - Standard Deviation

**Conflicts of Interests: None**

## REFERENCES

- [1]. Pereda J, Niimi G. Embryonic erythropoiesis in human yolk sac: two different compartments for two different processes. *Microsc Res Tech* 2008; 71: 856-862.
- [2]. Kurtz AB, Needleman L, Pennell RG, Baltarowich O, Vilaro M, Goldberg BB. Can detection of the yolk sac in the first trimester be used to predict the outcome of pregnancy? A prospective sonographic study. *AJR Am J Roentgenol* 1992; 158: 843-847.
- [3]. Kucuk T, Duru NK, Yenen MC, Dede M, Ergun A, Ba'er I. Yolk sac size and shape as predictors of poor pregnancy outcome. *J Perinat Med* 1999; 27: 316-320.
- [4]. Levi CS, Lyons EA, Lindsay DJ. Early diagnosis of nonviable pregnancy with endovaginal US. *Radiology* 1988;167:383-5.
- [5]. Hakim RB, Gray RH, Zacur H. Infertility and early pregnancy loss. *Am J Obstet Gynecol* 1995; 172:1510-17.
- [6]. Xie YJ, Chen M, Chen SJ. Prediction of pregnancy outcomes with combined ultrasound scanning of yolk sacs and serum CA125 determinations in early threatened abortion. *Clin Exp Obstet Gynecol*. 2014;41(2):186-9.
- [7]. Heller R, Cameron S. Termination of pregnancy at very early gestation without visible yolk sac on ultrasound. *J Fam Plann Reprod Health Care*. 2015;41(2):90-95.
- [8]. Jose L., Nanditha Abdul Latheef . Sonographic evaluation of yolk sac. *International Journal of Scientific & Engineering Research*. 2015;6(5):11-15.
- [9]. Moradan S., Forouzesfar M.F. Are abnormal yolk sac characteristics important factors in abortion rates?. *International Journal of Fertility and Sterility* 2012;6(2): 127-130.
- [10]. Shetty AS, Hegde D, Shetty BSK, Padubidri JR. Yolk Sac Abnormalities –Is it a Reliable Indicator of Abortions? – A Prospective Study in the Population Residing in Rural Setup of Mangaluru, Karnataka, India. *JPharm Biomed Sci* 2015; 05(05): 380-384.

- [11]. Adija P, Selvi C, Rai L, Hebbar S. Evaluation of yolk sac diameter and embryonic heart rate as prognostic factors of gestational outcome in early singleton pregnancies. *Scholars Journal of Applied Medical Sciences (SJAMS)*, 2015;3(2A):543-550.
- [12]. Tan S. et al. Abnormal sonographic appearances of the yolk sac: which can be associated with adverse perinatal outcome? *Med Ultrason* 2014;16(1):15-20.
- [13]. Berdahl DM, Blaine J, Van Voorhis B, Dokras A. Detection of enlarged yolk sac on early ultrasound is associated with adverse pregnancy outcomes. *Fertil Steril* 2010;94:1535- 1537.
- [14]. Malinowski W. Yolk sacs in twin pregnancy. *Ginekol Pol.* 2000;71(8):815-818.
- [15]. Cho FN, Chen SN, Tai MH, Yang TL. The quality and size of yolk sac in early pregnancy loss. *Aust N Z J Obstet Gynaecol* 2006;46:413-418.
- [16]. Varelas FK, Prapas NM, Liang RI, Prapas IM, Makedos GA. Yolk sac size and embryonic heart rate as prognostic factors of first trimester pregnancy outcome. *Eur J Obstet Gynecol Reprod Biol* 2008;138:10-13.

**How to cite this article:**

Geetanjali Srivastava, Mumal Nagwani, Navbir Pasricha, Vineeta Tewari, M.S. Siddiqui, Eti Sthapak. SIZE OF YOLK SAC BY ULTRASONOGRAPHY AND ITS CORRELATION WITH PREGNANCY OUTCOME. *Int J Anat Res* 2016;4(1):2052-2057. **DOI:** 10.16965/ijar.2016.135