

A MORPHOLOGICAL STUDY OF PONTICULI OF THE HUMAN ATLAS VERTEBRAE AND ITS CLINICAL SIGNIFICANCE

Md. Jawed Akhtar ^{*1}, Nasreen Fatima ², Ritu ³, Vinod Kumar ⁴.

^{*1} Senior Resident, Department of Anatomy, Indira Gandhi Institute of Medical Sciences, Patna, Bihar, India.

² Senior Resident, Department of Anaesthesiology, All India Institute of Medical Sciences, Patna, Bihar, India.

³ Senior Resident, Department of Forensic Medicine & Toxicology, Indira Gandhi Institute of Medical Sciences, Patna, Bihar, India.

⁴ Head of Department, Department of Anatomy, Indira Gandhi Institute of Medical Sciences, Patna, Bihar, India.

ABSTRACT

BACKGROUND: The first cervical vertebra, atlas plays a vital role in the movement of skull & neck. The anatomy of atlas is complex due to its three dimensional structure. There is a groove on superior surface of posterior arch of atlas for passage of 3rd part of vertebral artery and first cervical spinal nerve (suboccipital nerve). Sometimes the oblique ligament of atlas which is present at the lower border of posterior atlanto-occipital membrane may ossify and convert this groove into a foramen. This foramen may be complete or incomplete, In some cases a bony bridge also extends from lateral masses of atlas to the posterior root of transverse process and form an additional foramen through which vertebral artery travels. The vertebral artery is prone to compression in its entire course between foramen transversarium and foramen magnum during extreme rotation movement of head & neck. This condition may be aggravated by the presence of these ponticuli & results in compromised blood flow and causes vertebrobasilar insufficiency presenting with dizziness, fainting, vertigo, transient diplopia & various neurological disturbances.

MATERIALS & METHODS: The present study was carried out on 118 (Male-62, Female-56) dried fully ossified adult human atlas of known sex for the presence of complete or incomplete ring for vertebral artery i.e. different ponticuli on the superior surface of the atlas vertebra.

RESULTS: We observed 21.17% cases of ponticulus posterior in which 7.62% specimens had complete ring while 13.55% specimens had incomplete ring & ponticulus lateralis was reported only in 5.93% cases (unilateral: 2.54% & bilateral: 3.39%). Incidence of ponticulus posterior as well as lateralis were more common in male as compared to female. Complete ponticulus posterior was more common in right side, while incomplete ponticulus posterior as well as ponticulus lateralis were more commonly bilaterally.

CONCLUSION: As indicated by our study, ponticulus posterior as well as lateralis are not so rare anomaly in the population of Bihar. So, the detail knowledge about these variations is very helpful to the neurophysicians, neurosurgeons, orthopedicians & otolaryngologists who faces regularly the patients complaining about the symptoms of vertebrobasilar insufficiency. These informations are also important for the spine surgeons to prevent vascular complications during spinal surgeries especially in those patients who required screw placements in the lateral mass of atlas.

KEY WORDS: Ponticulus Posterior, Ponticulus Lateralis, Arcuate Foramen, Atlas Vertebra.

Address for Correspondence: Md. Jawed Akhtar, Senior Resident, Department of Anatomy, Indira Gandhi Institute of Medical Sciences, Patna, Bihar, India. **E-Mail:** drjawedakhtarpmch@gmail.com

Access this Article online

Quick Response code



DOI: 10.16965/ijar.2015.296

Web site: International Journal of Anatomy and Research
ISSN 2321-4287
www.ijmhr.org/ijar.htm

Received: 10 Oct 2015 Accepted: 04 Nov 2015
Peer Review: 10 Oct 2015 Published (O): 30 Nov 2015
Revised: None Published (P): 31 Dec 2015

BACKGROUND

As we all know first cervical vertebra is Atlas. It is ring shaped & does not have body and spine like other cervical vertebrae. The free nodding movement of the head is possible due to the absence of spine. The atlas holds the entire globe of our skull. It has two lateral masses joined with each other by anterior and posterior arch. The posterior surface of the anterior arch bears an oval facet, which articulates with dens of the 2nd cervical vertebrae. The posterior arch is longer than the anterior arch & form about three fifth of atlantal ring. The posterior arch of atlas, which corresponds to the laminae of other vertebrae, bears a groove known as sulcus arteriae vertebralis, on its superior surface for the 3rd part of vertebral artery and dorsal ramus of first cervical spinal nerve (suboccipital nerve). Posterior atlanto-occipital membrane is attached to superior border of posterior arch of atlas. This membrane is deficient at its each lateral border through which vertebral artery & first cervical nerve passes. The oblique ligament of atlas which is present at the lower border of this membrane, bridges the vertebral artery groove sometimes may ossify & convert the groove into a foramen [1,2]. These foramina may be complete or incomplete, which is commonly known as ponticulus posterior (ponticulus posticus) or arcuate foramen of the atlas. The alternative names of this foramen are: retroarticular canal, retroarticular vertebral artery ring, foramen retroarticular superior, retrocondylar bony foramen, posterior atlantoid, atlas bridging, pons posticus, foramen atlantoideum posterius (or vertebrale), canalis arteriae vertebralis, foramen sagitale, posterior glenoid process and speculum & kimmerle anomaly (or deformity) [3]. The lateral masses form ellipsoid type of synovial joint after articulation with the occipital condyles. The vertebral artery passes from foramen transversarium of the atlas, turns backwards & medially behind the lateral mass and lies in the groove in the posterior arch. Then, it pierces the posterior atlanto-occipital membrane and enters the foramen magnum & finally form the basilar artery. Sometimes, a bony bridge also extends from these lateral masses to the posterior root of transverse process and forms an additional

foramen through which vertebral artery travels which is commonly known as ponticulus lateralis [4]. In some cases the posterior as well as lateral ponticuli are present together and form the posterolateral ponticuli. The vertebral artery is vulnerable to damage or distortion from any external factors like bony or ligamentous structures [5]. The ponticuli are among the examples of such factors which may cause external pressure on the vertebral artery & causes vertebro-basilar insufficiency [6,7]. During therapeutic manipulation of the cervical spine extreme rotational movements carried out, in which sometimes pressure over vertebral artery becomes severely enough which reduces the cross sectional area & compromises the blood supply and results in vertebrobasilar insufficiency [4,8]. Thus these anatomical variations should be considered during any manipulation of cervical spine [9]. But, still no data were available about these variations in Bihar region hence the necessity of the present study arose. So, we study the incidence of ponticulus posterior as well as lateralis on atlas vertebra in the population of Bihar which explain vertebral artery entrapment and compare the incidence of such type of variation in atlases of various races of world.

MATERIALS AND METHODS

The present study carried out on 118 dried fully ossified adult human atlas, which were collected from the students of the 1st year MBBS and Department of Anatomy & Forensic Medicine of Indira Gandhi Institute of Medical Sciences, Lord Buddha Koshi Medical College & Patna Medical College of Bihar, by the consents and permission from heads of the departments. These 118 atlases were segregated into male and female atlas on the basis of following criteria [2]:

1. In males: The maximum atlantal width varies from 74-95 mm.
2. In females: The maximum atlantal width varies from 65-76 mm.

Finally, these were segregated as 62 male & 56 female atlases. All bones were examined to ensure that the vertebrae were intact and free from osteophytes or metastatic tumors. Then the each atlas vertebrae was observed carefully on the superior surface of the posterior arch for the

presence or absence of complete or incompleting for vertebral artery i.e. different ponticuli on the superior surface of the atlas vertebra.

RESULTS

We observed 21.17% cases of ponticulus posterior in which 7.62% specimens had complete ring while 13.55% specimens had incomplete ring & ponticulus lateralis was reported only in 5.93% cases (unilateral: 2.54% & bilateral: 3.39%) (Table:1 & 2). Incidence of ponticulus posterior as well as lateralis were more common in male as compared to female. Complete ponticulus posterior was more common in right side, while incomplete ponticulus posterior as well as ponticulus lateralis were more commonly bilaterally (Figure:1-7).

Table 1: Distribution of ponticulus posterior.

Sex	Complete Ring			Incomplete Ring			Total
	Right side	Left side	B/L	Right side	Left side	B/L	
Male	4 (3.39%)	2 (1.69%)	--	3 (2.54%)	1 (0.85%)	7 (5.93%)	17 (14.40%)
Female	3 (2.54%)	--	--	2 (1.69%)	--	3 (2.54%)	8 (6.77%)
Total	7 (5.93%)	2 (1.69%)	--	5 (4.23%)	1 (0.85%)	10 (8.47%)	25 (21.17%)

B/L: Bilateral.

Table 2: Distribution of ponticulus lateralis.

Sex	U/L		B/L	Total
	Right Side	Left Side		
Male	1 (0.85%)	--	3 (2.54%)	4 (3.39%)
Female	2 (1.69%)	--	1 (0.85%)	3 (2.54%)
Total	3 (2.54%)	--	4 (3.39%)	7 (5.93%)

U/L: Unilateral, B/L: Bilateral.

Fig. 1: Atlas vertebra showing right sided complete ponticulus posterior.

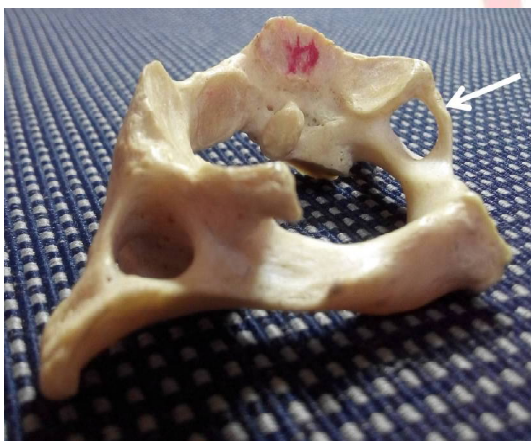

Fig. 2: Atlas vertebra showing left sided complete Ponticulus Posterior.

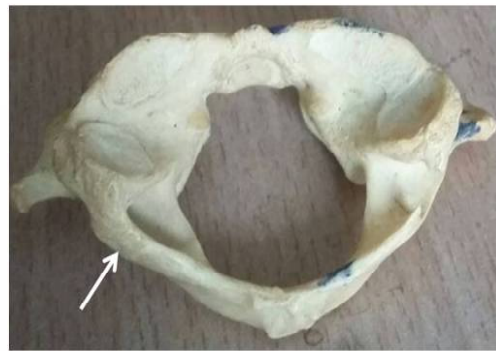


Fig. 3: Atlas vertebra showing right sided incomplete ponticulus posterior.

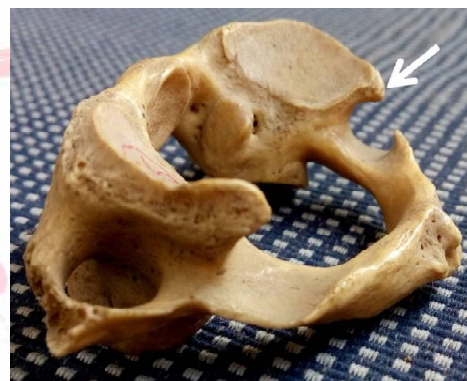

Fig. 4: Atlas vertebra showing left sided incomplete ponticulus posterior.

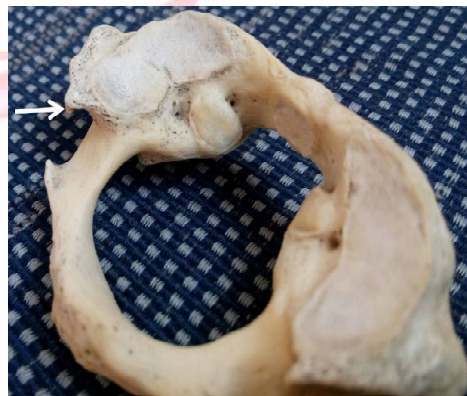

Fig. 5: Atlas vertebra showing bilateral incomplete ponticulus posterior.

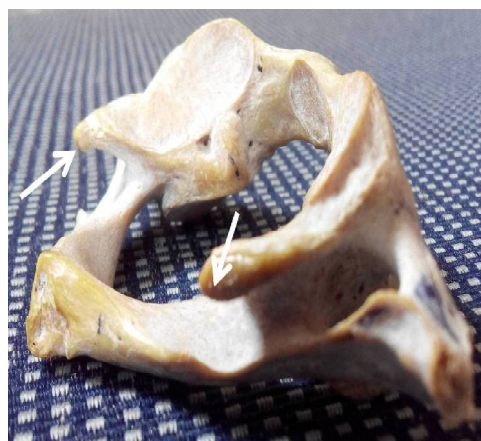

Fig. 6: Atlas vertebra showing right sided lateral ponticulus.

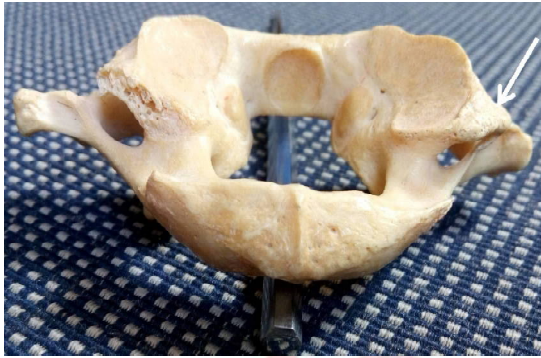
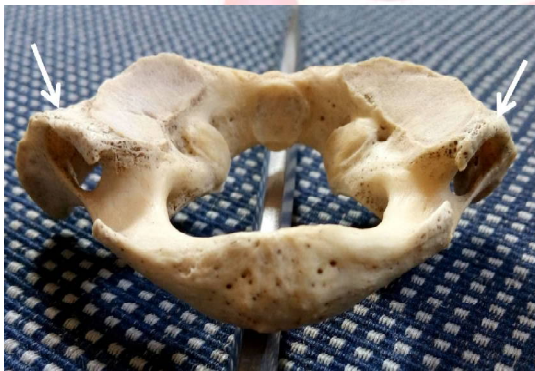

Fig. 7: Atlas vertebra showing bilateral lateral ponticulus.



DISCUSSION

Now a days, usage of different surgical procedures and instrumentation were increased for the management of unsteady cervical spine. Various traumatic, neoplastic or congenital conditions continue to progress, hence detail knowledge about anatomy around this region becomes necessary. Many authors have studied about the ponticulus posterior and lateralis & reported their occurrence in 5.7% - 37.83% and 2% - 13.5% of the general population respectively [10-21] (Table:3). The ponticulus posterior as well as lateralis first of all reported by Macalister in 1869. Further Macalister along with Le Double studied detailed morphology about these variations which drawn attention of the anatomists since then. The mechanism of formation of these ponticuli is a matter of debate because many theories have been postulated regarding their development. LeDouble described that pulsation of vertebral artery induced the ossification of the ligament

and also mention that such type of bony ring formation could not occurs simply due to ossification of the ligament but it occurs as a result of a regressive & disappearing morphological phenomenon [21].

This hypothesis was further supported by Lamberty and Zivanovic [8], who reported these posterior ponticuli in skeletons of two children aged 2 & 4 years and explained that ossification of the ligaments never occur in such young groups of people. Tritz and Nathan [4] proposed a hypothesis that the development of the bony ponticuli may be due to external mechanical factors like carrying heavy objects on the head, which was further supported by Paraskevas G et al [15] who reported that occurrence of these complete bony ponticuli was more common in laborers with respect to non laborers & also mentioned that incomplete bony rings were more common in 5 to 44 years age group. Paraskevas G et al [15] also hypothesized that these incomplete bony ponticuli are precursor of the complete bony ponticuli, which was supported by observations of Kendrick GA & Biggs NL [22] regarding two female in which over a period of 1 to 2 years the unilateral incomplete ponticulus posterior changed into radio opaque complete ring.

In the present study we observed 21.17% cases of ponticulus posterior which is very near to findings of Kavakli A et al [13] who reported 22.10% cases of ponticulus posterior and we found ponticulus lateralis in 5.93% cases which is close to observation of Taitz C and Nathan H [4] who reported 3.8% cases in their study. Stubbs DM [23] found that complete bony ring was more common in male and partial ring was more common in white females & we also reported the same i.e. complete ponticulus posterior was more common in male while incomplete one was more common in females. These foramen is more common in black as compare to white [9]. While Cakmak O et al [14] reported just opposite to our findings i.e. higher incidence of complete bony rings in females as compared to males. These complete posterior ponticuli is a normal structure in the adult Japanese macaques [24]. Krishnamurthy A et al [16] studied about the different dimensions of the arcuate foramen and reported that mean

length was 9.99 mm in right side & 7.16 mm in left side in bilateral cases while it was 9.26 mm & 8.14 mm respectively in unilateral cases. The vertical height was 6.52 mm in right side & 6.57 mm in left side in bilateral cases while it was 5.38 mm & 4.91 mm respectively in unilateral cases. Unur E et al [25] also studied different dimensions of the arcuate foramen and reported that the mean height was 5.7 mm (Range: 3.7-8.5 mm) and mean length was 8.1 mm (Range: 5.7-10.0 mm). The mean area of the arcuate foramen was 14.2 square mm observed by Tubbs RS et al [3].

Table 3: Incidence of ponticulus posterior and lateralis recorded by different workers.

Sr. No.	Authors	Incidence of ponticulus posterior	Incidence of ponticulus lateralis
1	Taitz C and Nathan H 1986 [4]	33.70%	3.80%
2	Dhall U et al 1993 [10]	37.83%	13.50%
3	Mitchell J 1998 [11]	9.80%	---
4	Hasan et al 2002 [12]	6.57%	2%
5	Kavakli A et al 2002 [13]	22.10%	3.60%
6	Cakmak O et al 2005 [14]	15%	---
7	Paraskevas G et al 2005 [15]	34.66%	11.36%
8	Krishnamurthy A et al 2007 [16]	13.80%	---
9	Simsek S et al 2008 [17]	9.40%	---
10	Dahiphale VP 2009 [18]	20%	---
11	Zambara & Reddy 2011 [19]	16%	---
12	Gupta C et al 2013 [20]	5.70%	---
13	Lalit M et al 2014 [21]	23.33%	8.30%
14	Present Study 2015	21.17%	5.93%

Mitchell J [9,11] classified the posterior bridges into three classes as follow : Class I - Groove of the vertebral artery; Class II - Vertebral artery groove with incomplete ring in which middle part was absent; Class III - Vertebral artery groove with complete ring. Hasan M et al [12] classified these posterior bridges into six classes as follow : Class I - included those having only the impression of vertebral artery on the posterior arch of atlas; Class II - included those having deeper impression like groove or sulcus for the vertebral artery; Class III - included those in which partial ponticulus posterior was present as a bony spicule; Class IV - included those having complete ponticulus posterior; Class V - included those having ponticulus lateralis

which extended from the lateral mass to the transverse process; Class VI - included those having posterolateral tunnel i.e. combination of complete ponticulus posterior (Class IV) & ponticulus lateralis (Class V).

Cushing KE et al [26] observed an association between vertebrobasilar artery stroke and presence of arcuate foramen which was due to tethering of the vertebral artery in this foramen which finally leads to dissection due to repetitive trauma with various movements of the head. Cakmak O et al [14] suggested that cervical spine radiography is a very simple and cost effective simple technique to know the presence or absence of arcuate foramen and should be considered if any patient complaining about headache, vertigo, pain in temporal region as well as back of eye, periodic photophobia & shoulder pain.

CONCLUSION

As indicated by our study, ponticulus posterior as well as lateralis are not so rare anomaly in the population of Bihar. So, the detail knowledge about these variations is very helpful to the neurophysicians, neurosurgeons, orthopedicians & otolaryngologists who faces regularly the patients complaining about the symptoms of vertebrobasilar insufficiency like headache, vertigo, pain in temporal region as well as back of eye, periodic photophobia, shoulder & arm pain. These informations are also important for the spine surgeons to prevent vascular complications during spinal surgeries especially in those patients who required screw placements in the lateral mass of atlas.

ACKNOWLEDGEMENTS

We sincerely thanks the Prof. Dr. K. Alam, Prof & HOD of Department of Anatomy, Patna Medical College, Patna (Bihar, India) for granting the permission to carry out the study in the department.

Conflicts of Interests: None

REFERENCES

- [1]. Last RJ: In Anatomy Regional and applied. 11th Ed. J and A Churchill Ltd. London. 2006; pp. 443.
- [2]. Richard LM Newell. "The Back" in Grays Anatomy: The Anatomical Basis of Clinical Practices, S. Standring, H. Ellis, J. C. Healy, D. Jhonson and A. Williams, Eds.; Churchill Livingstone, New York, NY, USA, 40th ed, 2008, pp. 720.

- [3]. Tubbs RS, Johnson PC, Shoja MM, Loukas M, Oakes WJ, Foramen arcuale: Anatomical study and review of the literature. *J Neurosurg Spine*. 2007;6(1):31–34.
- [4]. Taitz C and Nathan H. Some observations on the posterior and lateral bridge of the atlas. *Acta Anatomica*. 1986;127(3):212-217.
- [5]. Mehalic T, Farhat SM. Vertebral artery injury from chiropractic manipulation of the neck. *Surgical Neurology*. 1974;2:125-129.
- [6]. Sylvia S, Kulkarni S, Hatti A. Bilateral Retro Articular ring in Atlas vertebra – A Case Report. *Anatomica Karnataka*. 2011;5(1):81-86.
- [7]. Karau PB, Ogeng'o JA, Hassanali J, Odula PO. Morphometry and Variations of Bony Ponticles of the Atlas Vertebrae (C1) in Kenyans. *Int J of Morphology*. 2010;28(4):1019-1024.
- [8]. Lamberty BGH, Zivanovic S. The Retro-articular vertebral artery ring of the atlas and its significance. *Acta Anat*. 1973;85:113-122.
- [9]. Mitchel J. The incidence of the lateral bridge of the atlas vertebra. *J of Anat* 1998b;193: 283-285.
- [10]. Dhall U, Chhabra S, Dhall JC. Bilateral asymmetry in bridges and superior articular facets of atlas vertebra. *J Anat Soc. India*. 1993;42(1):23-27.
- [11]. Mitchell J. The incidence and dimensions of the retroarticular canal of the atlas vertebra. *Acta Anatomica*. 1998;163:113–120.
- [12]. Hasan M, Shukla S, Siddiqui MS, Singh D. Posterolateral tunnels and ponticuli in human atlas vertebrae. *J. Anat* 2001;199:339-343.
- [13]. Kavakli A, Aydinlioglu, Yesilyurt H, Kus I, Diyarbakirli, Erdem S et al. Variants and deformities of atlas vertebrae in eastern Anatolian people. *Saudi Med J*. 2004;25(3): 322-325.
- [14]. Cakmak O, Gurdal E, Ekinci G, Yildiz E, Cavdar S. Arcuate foramen and its clinical significance. *Saudi Med J*. 2005;26:1409-1413.
- [15]. Paraskevas G, Papaziogas B, Tsonidis C & Kapetanos G. Gross morphology of the bridges over the vertebral artery groove on the atlas. *Surg. Radiol. Anat*. 2005;27(2):129-136.
- [16]. Krishnamurthy A, Nayak SR, Khan S, Prabhu Latha V, Ramanathan LA, Kumar CG, et al. Arcuate foramen of atlas: Incidence, Phylogenetic and Clinical significance. *Romanian J of Morphol and Embryol*. 2007;48(3):263-266.
- [17]. Simsek S, Yigitkanli K. Posterior osseous bridging of C1. *J Clin Neurosci*. 2008;15:686–688.
- [18]. Dahiphale VP, Bahetee BH. The retroarticular vertebral artery ring of the atlas and its significance. *J Anat Soc. India*. 2009;58:149-151.
- [19]. Zambare BR, Reddy BB. The retroarticular ring of the atlas and its clinical significance. *Anatomica Karnataka*. 2011;5(2):74-76.
- [20]. Gupta C, Radhakrishnan P, Palimar V, D'souza AS, Kiruba NL. A quantitative analysis of atlas vertebrae and its abnormalities. *J Morphol Sci*. 2013;30(2):77-81.
- [21]. Lalit M, Piplani S, Arora AK, Kullar JS, Sharma T. Incidence of atlas bridges and tunnels: Their phylogeny, ontogeny and clinical implications. *Rev Arg de Anat Clin*. 2014;6(1):26-34.
- [22]. Kendrick GA, Biggs NL. Incidence of the ponticulus posticus of the first cervical vertebra between ages six to seventeen. *Anatomical Record*. 1963; 145:449-451.
- [23]. Stubbs DM. The arcuate foramen. Variability in distribution related to race and sex. *Spine*. 1992;17(12):1502-1504.
- [24]. Yamamoto A, Kunitatsu Y. Ontogenetic change and geographical variation of atlas bridging in Japanese macaques (*Macaca fuscata*). *Anthropological Science*. 2006; 114(2):153-160.
- [25]. Unur E, Erdogan N, Ulger H, Ekinci N, Ozturk O. Radiographic incidence of complete arcuate foramen in Turkish population. *Erciyes Med J*. 2004;26(2):50–54.
- [26]. Cushing KE, Ramesh V, Gardner Medwin D, Todd NV, Gholkar A, Baxter P, Griffiths PD. Tethering of the vertebral artery in the congenital arcuate foramen of the atlas vertebra: a possible cause of vertebral artery dissection in children. *Dev Med Child Neurol*. 2001;43(7):491–496.

How to cite this article:

Md. Jawed Akhtar, Nasreen Fatima, Ritu, Vinod Kumar. A MORPHOLOGICAL STUDY OF PONTICULI OF THE HUMAN ATLAS VERTEBRAE AND ITS CLINICAL SIGNIFICANCE. *Int J Anat Res* 2015;3(4):1597-1602. DOI: 10.16965/ijar.2015.296