

Antipsoriatic activity of ayurvedic ointment containing aqueous extract of the bark of *Pongamia Pinnata* using the rat ultraviolet ray photodermatitis model

Divakara P.^{1*}, Nagaraju B.¹, Buden R. P.², Sekhar H. S.³ and Ravi C. M.²

¹Department of Pharmacology, Nargund College of Pharmacy and Research Centre, Bangalore 560085, India.

²Bangalore Division of South Western Railway 560023, India.

³Department of Pharmacy Practice, Visveswarapura Institute of Pharmaceutical Sciences, Bangalore-560070, India.

Accepted 21 January, 2013

ABSTRACT

Many herbal remedies individually or in combination have been recommended in various medical expositions for the cure of different diseases. Chronic plaque psoriasis is an immune-mediated, inflammatory skin disease. Current treatments are unable to counter the inflammatory conditions of psoriasis. The present study was carried out to evaluate whether the presence of aqueous extract of bark of *Pongamia pinnata* in a commercial preparation SUEX GEL that is used in the treatment of psoriasis, has any additional benefits over a similar preparation supplied by the manufacturer that does not have the extract using the rat ultraviolet ray photo dermatitis model. The irradiated rat skin treated with SUEX GEL containing aqueous extract of the bark of *P. pinnata* showed a significant reduction in the total epidermal thickness, retention of the stratum granulosum and the absence of movement of neutrophils, and further substantiated that the SUEX GEL having aqueous extract of the bark of *P. pinnata* has been very useful in the changes that occur in the skin due to irradiation. The presence of the aqueous extract of the bark of *P. pinnata* produces an improvement in the efficacy of the ayurvedic ointment (SUEX GEL) used in the treatment of psoriasis.

Keywords: *Pongamia pinnata*, psoriasis, ultra-violet ray photo dermatitis.

*Corresponding author. E-mail: divacology@gmail.com

INTRODUCTION

The role of traditional medicines in the solution of health problems is invaluable on a global level. Medicinal plants continue to provide valuable therapeutic agents, both in modern and in traditional medicine (Krentz and Bailey, 2005). With the associated side effects of modern medicine, traditional medicines are gaining importance and are now being studied to find the scientific basis of their therapeutic actions (Gupta and Briyal, 2004). It is also gaining greater acceptance from the public and the medical profession due to greater advances in understanding the mechanism of action by which herbs can positively influence health and quality of life (Fugh-Berman, 2000).

Pongamia pinnata (Family: *Leguminosae*) is a medium sized glabrous semi-evergreen tree growing up to 18 m or higher, with a short bole, spreading crown with greyish green or brown bark. Leaves are imparipinnate, alternate, leaflets 5 to 7, ovate and opposite. This tree is popularly known as Karanja in Hindi, Indian Beech and Derris indica in English, and Hongae in Kannada. *P. pinnata* occurs all over India in the bank of rivers and streams and planted as avenue tree in gardens (Srinivasan et al., 2001). Bark is sweet, anthelmintic and alexteric. Fresh bark is reported be used to treat the piles (Joy et al., 1998). Previous studies have demonstrated that *P. pinnata* is rich in flavonoids and related compounds.

Seeds and seed oil, flowers and stem bark yield karanjin, pongapin, pongaglabrone, kanugin, desmethoxykanugin and pinnatin-5-furanoflavonoid glucosides, pongamosides A-C, flavonol glucoside pongamoside-D have also been reported (Joy et al., 1998). In recent researches, Meher et al. (2006) studied the transesterification of karanja oil with methanol using solid basic catalysts. The crude decoction of dried leaves of *P. pinnata* for its antimicrobial effects (antibacterial, anti-giardial and antiretroviral) was evaluated by Brijesh et al. (2006). Manoharan et al. (2006) evaluated the antihyperglycemic and antilipid peroxidative effect of ethanolic extract of *P. pinnata* (Leguminosae) flowers (PpEt) in normal and alloxan induced diabetic rats. Ramasamy and Rameshthangam 2007 reported that ethanolic extract of the leaves of *P. pinnata* has significant antibacterial activity against the tested bacteria *Vibrio* sp., *Pseudomonas* sp., and *Streptococcus* sp. Punitha and Manohar in 2006 evaluated anti-hyperglycemic and antilipid peroxidative effects of ethanolic extract of *P. pinnata*. Effects of *P. pinnata* on lipid peroxidation products and antioxidants in hyperammonemic rats with reference to circadian variations were evaluated by Essa et al. (2005).

In the traditional systems of medicines, such as Ayurveda and Unani, *P. pinnata* is used for anti-inflammatory, antiplasmodial, anti-nociceptive, anti-hyperglycaemics, antilipidoxidative, anti-diarrhoeal, anti-ulcer, antihyperammonic and antioxidant. Its oil is a source of biodiesel. It has also alternative source of energy, which is renewable, safe and non-pollutant (Chopade et al., 2008). The plant affords patulitrin, β -sitosterol, spicigerine, aminoacids, albumin, globulin, glutelins and flavonoids such as furanoflavones, furanoflavanols, chromenoflavones and furanochalcones (Tanaka et al., 1992). The plant also contains alkaloids, tannins and carbohydrate (Yin et al., 2006).

The overall aim of the proposed study is to evaluate whether the presence of aqueous extract of bark of *P. pinnata* in a commercial preparation SUEX GEL that is used in the treatment of psoriasis, has any additional benefits over a similar preparation supplied by the manufacturer that does not have the extract using the rat ultraviolet ray photo dermatitis model.

MATERIALS AND METHODS

Chemicals and drugs

1. Commercially available formulation SUEX GEL to treat psoriasis containing *P. pinnata* (aqueous extract of bark) as one of the ingredients.
2. SUEX GEL that does not contain *P. pinnata* (aqueous extract of bark) with all the other ingredients remaining the same as in the commercial formulation.
3. Only ointment base used in formulating SUEX GEL. The other active ingredients in the formulations are *neem*, *daruhaldi*, *tulsi*, *karanja*, *katuki*, *kutaja*, *biding*, *gandak*, and components of the ointment base are methyl paraben, propyl paraben, bromopol, acrophyl 940, tri-ethanol amine and distilled water.

The above three products were provided by the manufacturer "SRUSHTI HERBAL PHARMA" Bangalore (Batch no: SSHP02/2010/ Exp: Dec-2015). All other chemicals and reagents used in this study were of analytical grade.

Rat ultraviolet ray photo dermatitis model for psoriasis (Vogel et al., 2002)

Irradiation of the depilated rat skin with ultraviolet radiation is known to produce a biphasic erythema. Immediately after irradiation, initial faint erythema appears, and disappears within 30 min. The second phase of erythema starts 6 h after the irradiation and gradually increases, peaking between 24 and 48 h. This reaction is confined to the exposed area and has a sharp boundary. It develops a brownish-red colour. By 48 to 72 h, silvery white scale appear on the erythematous lesion. These scales are relatively thick and begin to fall beyond 72 h. The erythema decreases daily and the irradiated site returns to normal in about 10 days. Although the erythematic reaction is induced artificially, many of the pathological features resemble those seen in psoriasis vulgaris. Earlier publications that made use of this model have reported the use of ultraviolet ray B (290 to 320 nm); however, due to its non availability, induction of the erythema using ultraviolet ray C (wavelength less than 290 nm) was tried in the preliminary part of current investigation.

Preliminary experiments were carried out using three groups of rats having two animals in each group. The depilated skin of the animals was irradiated for a time period of 15 min in case of Group I, 30 min in case of Group II and 45 min in case of Group III.

Only the animals which were irradiated for a period of 45 min exhibited the biphasic response reported to be produced with the use of ultraviolet ray B, whereas those irradiated for a period of 15 or 30 min did not exhibit such a response. As the bandwidth of ultraviolet radiation produced by the source falls to a level less than that of the wavelength of ultraviolet ray B, unnecessary exposure to the harmful shorter wavelength has been avoided by restricting the time of exposure to the minimum required level. All the animals in the 45 min exposed group developed silvery white scales within the third day of exposure, which was considered as an indication that the inflammatory process has set in and is progressing in accordance with its normal pathway. Comparison of the histopathological changes observable on day third between the drug treated and non drug treated groups was considered as a good method to evaluate the effectiveness of the drug. This type of evaluation is necessitated by the fact that all the histopathological changes associated with the exposure to UV-C radiation subside within the tenth day of exposure and the integrity of the skin returns to normal.

Male Wistar rats weighing 250 to 300 g were divided to form 5 groups having 6 animals in each. All animal procedures have been approved by the Animal Ethical Committee (No: IAEC/NCP/2009) in accordance with animal experimentation and care guidelines provided by IAEC/CPCSEA. The time and treatment protocol followed are as under:

- Group I: Exposed to UV-C radiation for 45 min but not subjected to any subsequent drug application (served as positive control).
- Group II: Exposed to UV-C radiation for 45 min and subsequently treated with the ointment base only.
- Group III: Exposed to UV-C radiation for 45 min and subsequently treated with the SUEX GEL.
- Group IV: Exposed to UV-C radiation for 45min and subsequently treated with the SUEX GEL not having *P. pinnata* as one of the ingredient.

The hairs of the skin, on one side of the flank, were depilated by clipping with a scissors followed by careful shaving taking

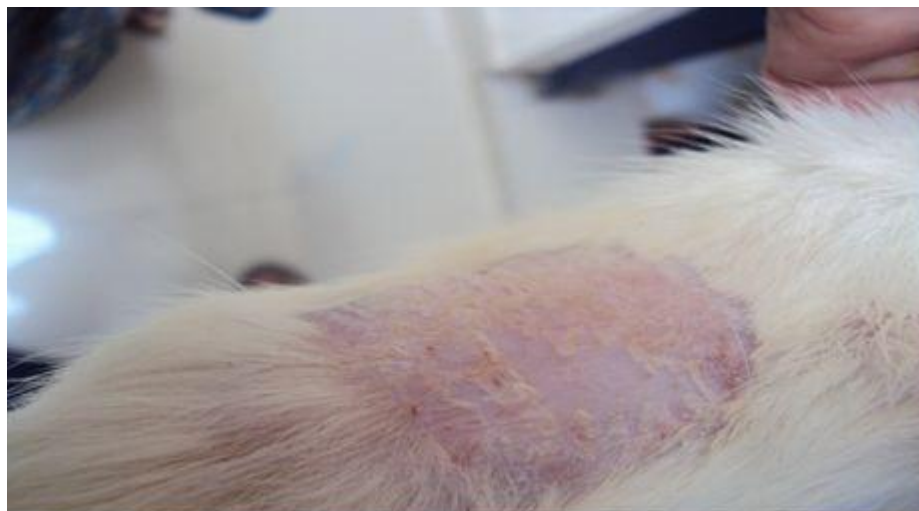

Figure 1. UV-C induced erythema in rats as seen on Day 3.

precaution to avoid injury to the skin. The animals were then placed on a curved wooden block and their legs tied around it, to avoid contact with the floor. This arrangement prevented the movement of the animal during its subsequent exposure UV radiation. Except for an area of 1.5 × 2.5 cm on the depilated skin, the entire animal was covered with a UV resistant film. The uncovered area of 1.5 × 2.5 cm was then irradiated for 45 min with a UV-C lamp kept at a vertical distance of 20 cm from the skin.

Application of the drug was started 12 h after irradiation, and was continued for three days. A schedule of two applications per day spaced over 12 h intervals was maintained. On the third day, 2 h after the last treatment, animals were anaesthised using anaesthetic ether and the exposed area of the skin was removed by surgical incision. The incised skin was then fixed in 10% buffered formalin solution that was followed by gradual dehydration using increasing strength of alcohol (80% to absolute alcohol). The skin was then embedded in paraffin wax and sections of 4 μm thickness were obtained using a microtome. These sections were transferred on to a glass slide and stained with hematoxylin and eosin.

Parameters evaluated

- Mean thickness of epidermis,
- Mean thickness of stratum corneum,
- Mean thickness of stratum granulosum,
- Ratio thickness of epidermis to stratum corneum (Chapman and Ross, 2001).

All measurements were made at a magnification of 400X using OLYMPUS microscope having a digital camera attachment and software to take measurements.

RESULTS AND DISCUSSION

Rat UV ray photo dermatitis model for psoriasis

Effects of the ointment base and SUEX GEL with and without *P. pinnata* as one of its component that were applied from the 12th hour after UV irradiation of the rats skin was evaluated on day 3 as thickness of epidermis,

stratum corneum and stratum granulosum was measured and the mean value for each group was obtained and UV-C induced erythema and erythema with scales in rats can be seen in Figure 1 and 2. Ratio of thickness of stratum corneum, and stratum granulosum as a percentage of total thickness of epidermis was calculated (Chapman and Ross, 2001).

Mean thickness of the epidermis

Mean thickness of the epidermis, in the positive control group, and the groups that were treated only with the ointment base, SUEX GEL, and SUEX GEL not having *P. pinnata* was found to be 62.50 ± 5.79 , 73.59 ± 1.17 , 31.69 ± 0.60 and 74.21 ± 2.02 μm, respectively (Figure 3, Table 1).

There was a significant decrease in the total thickness of epidermal layer in the group treated with SUEX GEL when compared with the positive control group, whereas no such significant change was observed in the groups that were treated with the ointment base or SUEX GEL not having *P. pinnata*.

Mean thickness of the stratum corneum

Mean thickness of the stratum corneum in the positive control group, and the groups which were treated only the ointment base, SUEX GEL and SUEX GEL not having *P. pinnata*, was found to be 3.95 ± 0.43 , 6.91 ± 1.69 , 3.95 ± 0.20 and 11.79 ± 2.29 μm, respectively (Figure 4, Table 1).

There was a significant increase in the total thickness of the stratum corneum in the group treated with SUEX GEL when compared with the positive control group, whereas no such significant change was observed in the groups that were treated with the ointment base or SUEX

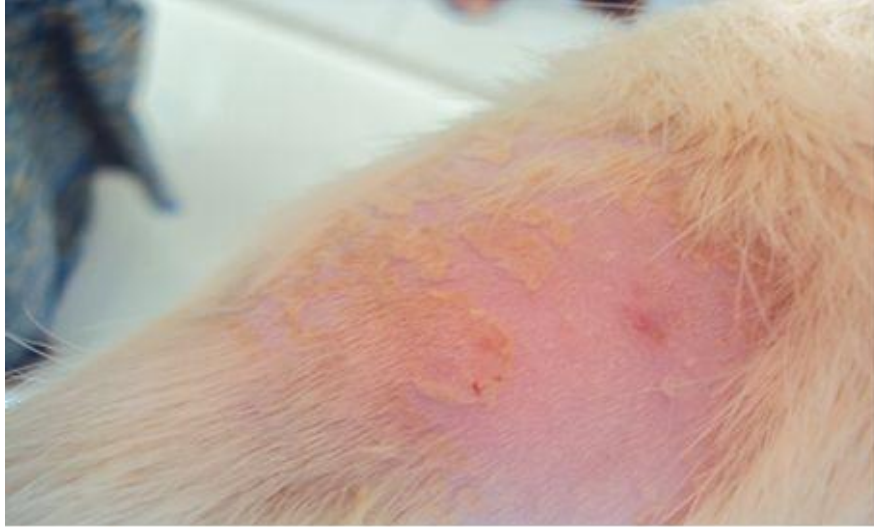


Figure 2. UV- C induced erythema with scales in rats as seen on Day 3.

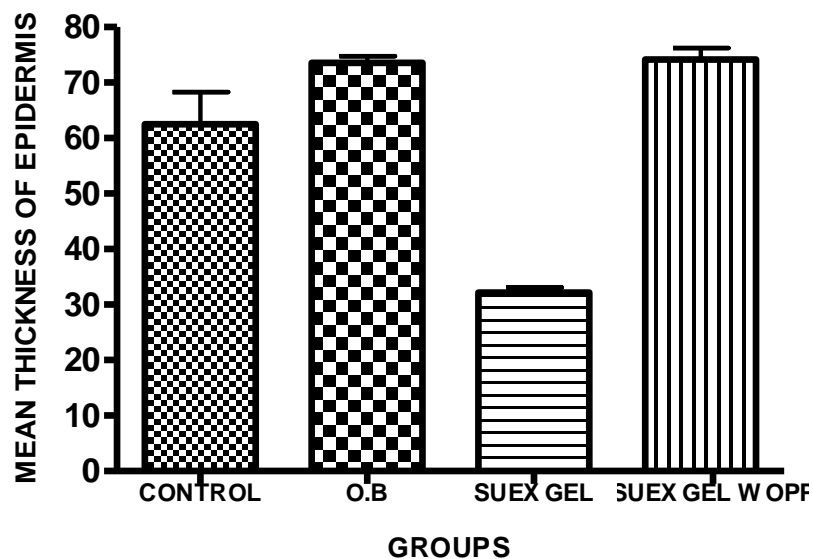


Figure 3. Mean thickness of epidermis. Control = Untreated; O.B = Ointment base treated; SUEX GEL WOPF = SUEX GEL treated without *Pongamia pinnata* (aqueous extract of bark).

GEL not having *P. pinnata*.

Mean thickness of the stratum granulosum

Stratum granulosum was absent in the positive control group and the groups that were treated with only the ointment base or SUEX GEL not having *P. pinnata*. The SUEX GEL treated group showed the presence of stratum granulosum $7.16 \pm 1.53 \mu\text{m}$ which is highly significant when compared with the positive control (Figure 5, Table 1).

Ratio of thickness of stratum corneum to total thickness of epidermis

The ratio of the thickness of stratum corneum expressed as percentage of total epidermal thickness, in the positive control group, and the groups that were treated only with the ointment base, SUEX GEL, and SUEX GEL not having *P. pinnata*, were found to be 6.37 ± 1.13 , 9.28 ± 2.15 , 24.45 ± 0.62 and $5.31 \pm 0.12\%$, respectively (Figure 6, Table 1).

Only the SUEX GEL treated group showed a significant increase in the ratio when compared with the positive

Table 1. Total thickness and thickness of different layers of epidermis.

GROUP	GROUP I, Positive control	GROUP II, Treated with ointment base	GROUP III, Treated with SUEX GEL	GROUP IV, SUEX GEL without <i>Pongamia pinnata</i>
Thickness				
Total thickness of epidermis, in μm (Mean \pm S.E.M)	62.50 \pm 5.79	73.59 \pm 1.17	31.69 \pm 0.60***	74.21 \pm 2.02
Thickness of stratum corneum, in μm (Mean \pm S.E.M)	3.95 \pm 0.43	6.91 \pm 1.69	11.79 \pm 2.29**	3.95 \pm 0.20
Thickness of stratum granulosum in μm (Mean \pm S.E.M)	Absent	Absent	7.16 \pm 1.53 ***	Absent
Thickness of stratum corneum expressed as % thickness of total epidermis (Mean \pm S.E.M)	6.37 \pm 1.13	9.28 \pm 2.15	24.45 \pm 0.62***	5.31 \pm 0.12
Thickness of stratum granulosum expressed as % thickness of total epidermis (Mean \pm S.E.M)	0.00	0.00	22.15 \pm 5.73***	0.00

***Significant (P < 0.001); **significant (P < 0.01).

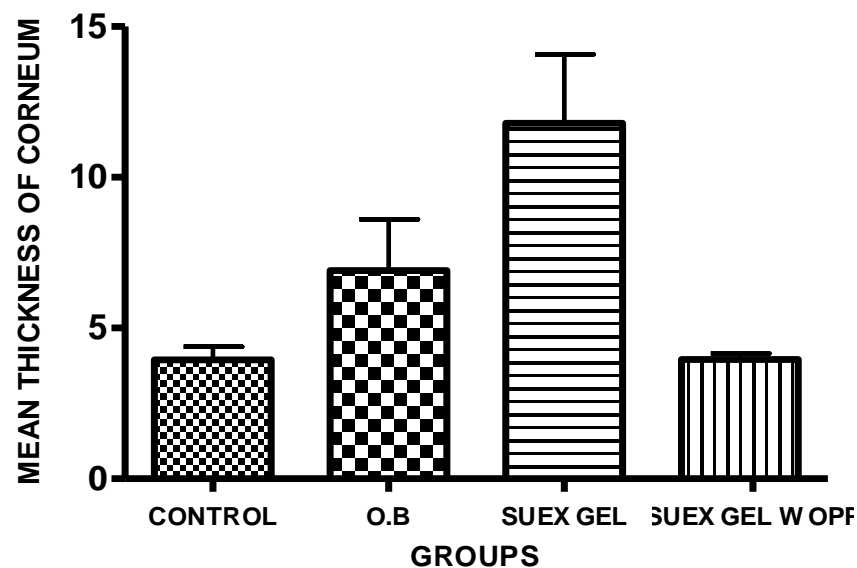


Figure 4. Mean thickness of corneum. Control = Untreated; O.B = Ointment base treated; SUEX GEL WOPP = SUEX GEL treated without *Pongamia pinnata* (aqueous extract of bark).

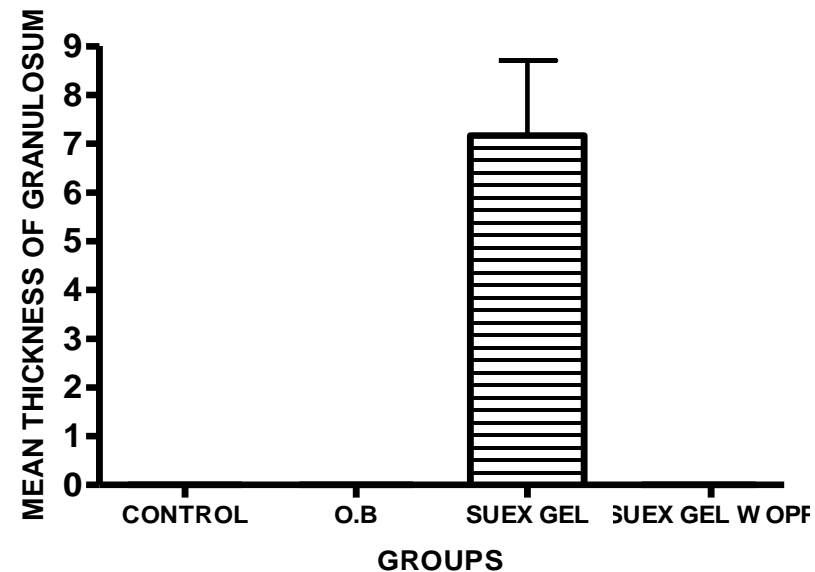


Figure 5. Mean thickness of granulosum. Control = Untreated; O.B = Ointment base treated; SUEX GEL WOPP = SUEX GEL treated without *Pongamia pinnata* (aqueous extract of bark).

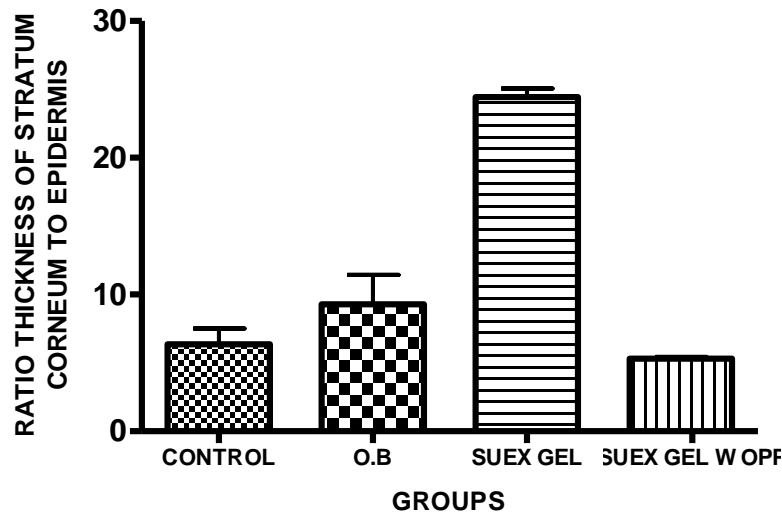


Figure 6. Ratio thickness of stratum corneum to epidermis. Control = Untreated; O.B = Ointment base treated; SUEX GEL WOPP = SUEX GEL treated without *Pongamia pinnata* (aqueous extract of bark).

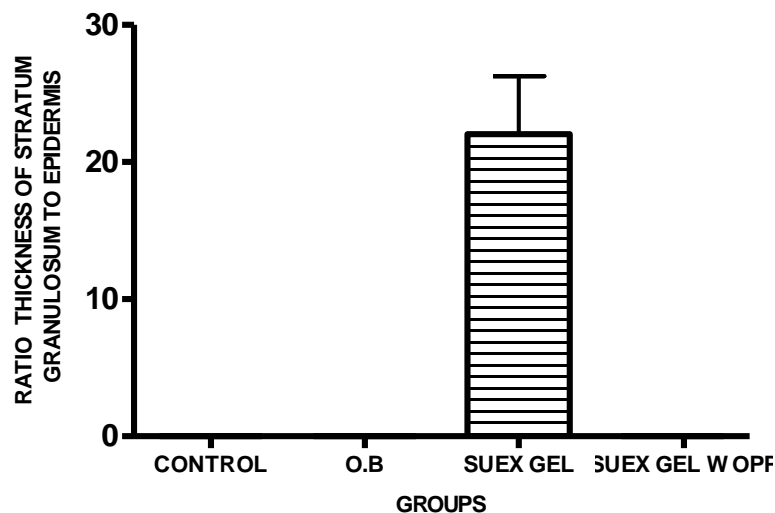


Figure 7. Ratio thickness of stratum granulosum to epidermis. Control = Untreated; O.B = Ointment base treated; SUEX GEL WOPP = SUEX GEL treated without *Pongamia pinnata* (aqueous extract of bark).

control. There was no significant change in the ratio for the groups that were treated with only the ointment base, or the SUEX GEL not having *P. pinnata*.

Ratio of thickness of stratum granulosum to total thickness of epidermis

The ratio of the thickness of stratum granulosum expressed as percent of total epidermal thickness in the positive control group, and the groups that were treated only with the ointment base, SUEX GEL, and SUEX GEL

not having *P. pinnata*, were found to be 0.00, 0.00, 22.15 ± 5.73 and 0.00%, respectively (Figure 7, Table 1).

Stratum granulosum was completely absent in the positive control groups and the groups that were treated with only the ointment base or SUEX GEL not having *P. pinnata*. The SUEX GEL treated group showed a ratio of 22.15 ± 5.73% which is highly significant when compared with the positive control.

The presence of *P. pinnata* in the SUEX GEL significantly decreases total thickness of the epidermis indicating that its presence in the formulation has an influence to retard the hyper proliferation of the keratin-

ocytes that occurs when the skin is exposed to UV radiation. The significant increase in the thickness of the stratum corneum is probably due to its ability to enhance the keratinisation process which is a protective strategy adopted by the skin when exposed to penetrating radiation. The presence of the granulosum layer in the skin treated with SUEX GEL only and its completely absent in the positive control, ointment base treated group and the group treated with SUEX GEL not having *P. pinnata*, indicates that its presence in the ointment is probably able to suppress the altered process of differentiation of the keratinocytes. The significant increase in the thickness of stratum corneum expressed as percent thickness of the total epidermis in the group treated with SUEX GEL is probably more due to a nearly two fold increase in the thickness of the stratum corneum rather than the decrease of the total thickness of the epidermis.

Histopathology report

In the “ultraviolet ray photodermatitis model for psoriasis”, the exposure of the rat skin to UV radiation using UV-C bulb (wavelength <290 nm) has induced pro-inflammatory reaction in the skin that resembles the one observed in psoriasis. This was evident by the altered skin parameters; the most important of which are increase in epidermal thickness to almost double the normal size, absence of stratum granulosum and the movement of neutrophils towards epidermis which are typical of psoriasis. Although the causative factor and the mechanism underlying the chronic manifestation of psoriasis is not clearly understood, there is scientific agreement that the end result is the initiation of a T-cell lymphocyte mediated immunological response that is pro-inflammatory in nature. The inflammatory reaction is restricted to the area of the skin where the antigen exists (Michael et al., 2005).

The irradiated rat skin treated with SUEX GEL that has aqueous extract of the bark of *P. pinnata* has shown a significant reduction in the total epidermal thickness and also significant retention of the stratum granulosum, the absence of movement of neutrophils, further substantiates that the SUEX GEL having aqueous extract of the bark of *P. pinnata* has been very useful in containing the changes that occur in the skin due to irradiation. The significant increase in the thickness of stratum corneum and ratio of thickness and stratum corneum to total thickness of epidermis have been observed in the SUEX GEL having aqueous extract of bark of *P. pinnata* treated group. Histopathological sections showed significant variation in all the four groups (Figures 8, 9, 10 and 11).

Overall, the irradiation of rat skin with UV-C for 45 min has shown good changes in the epidermis, resembling psoriasis. The close resemblance of inflammatory

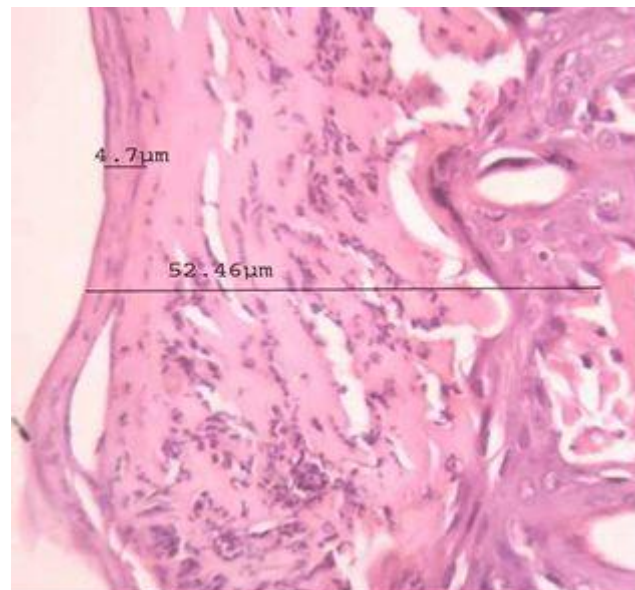


Figure 8. Histopathology studies of positive control group: (UV-C irradiated with untreated).

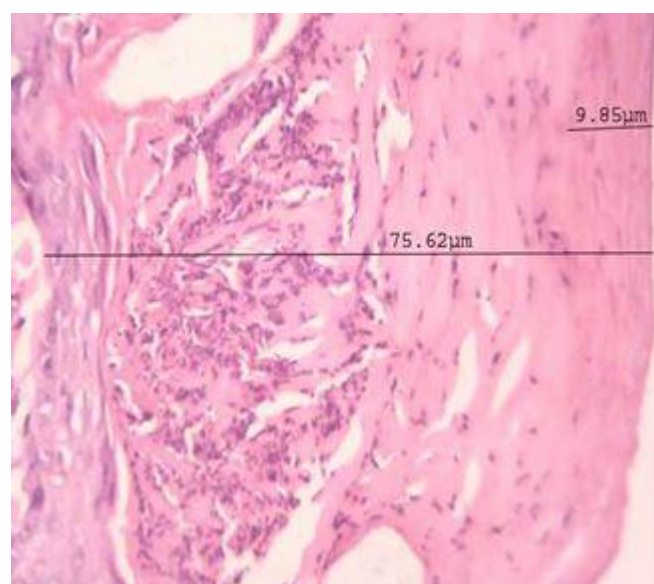


Figure 9. Histopathology studies of ointment base treated group.

process produced by ultraviolet radiation to the one exhibited in psoriasis provides us with a good model to investigate drugs that have a potential to reduce the inflammatory reaction associated with psoriasis. Further, the drug used, that is, SUEX GEL having aqueous extract of bark of *P. pinnata* has brought about useful changes in the epidermis of the irradiated skin, which shows that the drug may be useful in psoriasis.

Application of the ointment base or SUEX GEL not having *P. pinnata* has not been able to significantly

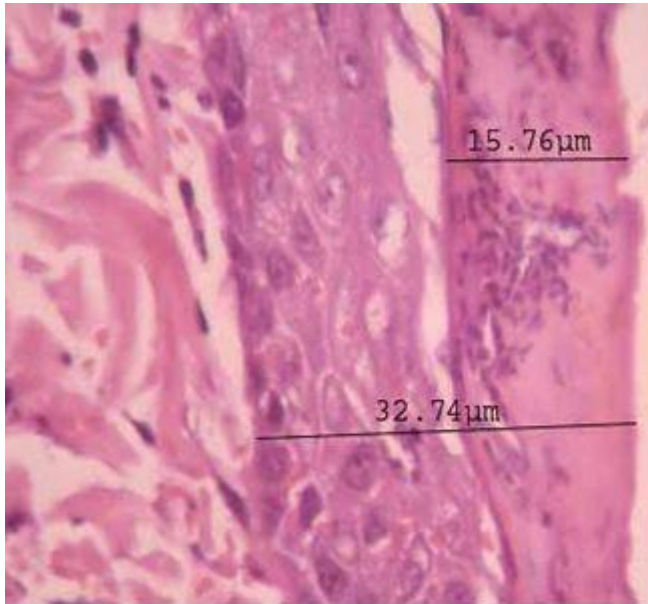


Figure 10. Histopathology studies of SUEX GEL treated group.

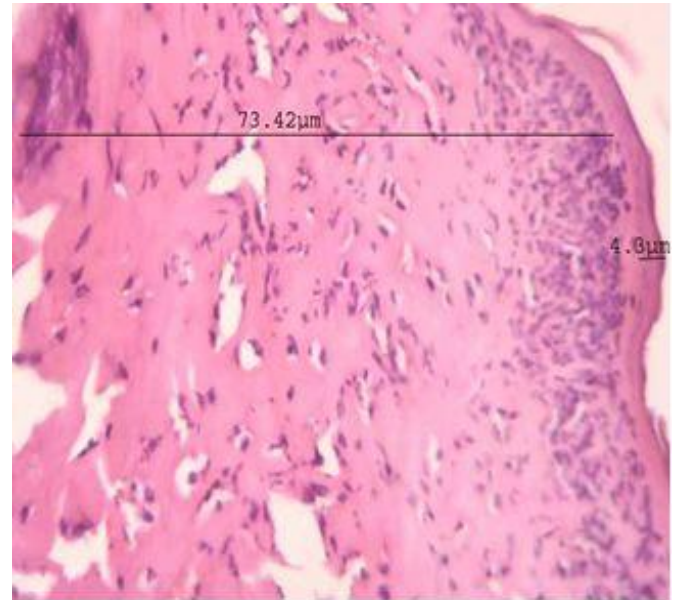


Figure 11. Histopathology studies of SUEX GEL without *Pongamia pinnata* treated group.

change inflammatory reaction induced by UV radiation. This is an indication that the incorporation of aqueous extract of bark of *P. pinnata* in the SUEX GEL is able to bring about a reduction in the proliferation of the keratinocytes and also alter the process of keratinization.

Conclusion

The irradiated rat skin treated with SUEX GEL containing aqueous extract of the bark of *P. pinnata* has showed a significant reduction in the total epidermal thickness, significant retention of the stratum granulosum and the absence of movement of neutrophils and further substantiated that the SUEX GEL having aqueous extract of the bark of *P. pinnata* has been very useful in the changes that occur in the skin due to irradiation.

The close resemblance of inflammatory process produced by ultraviolet radiation to the one exhibited in psoriasis provides us with a good model to investigate drugs that have a potential to reduce the inflammatory reaction associated with psoriasis. Hence, ayurvedic ointment containing aqueous extract of the bark of *P. pinnata* has shown antipsoriatic activity by good reduction in the thickness of epidermis, significant retention of the stratum granulosum and the absence of movement of neutrophils in UV-C induced psoriasis.

ACKNOWLEDGEMENTS

Authors are thankful to Nargund College of Pharmacy, Bangalore for providing necessary facilities for carrying out this research work.

REFERENCES

- Brijesh S, Daswani PG, Tetali P, Rojatkar SR, Antia NH, Birdi TJ, 2006. Studies on *Pongamia pinnata* (L.) Pierre leaves: understanding the mechanism(s) of action in infectious diarrhea, *J Zhejiang Univ Science B*, 7(8):665-674.
- Chapman DM, Ross JB, 2001. Objective measurement of three epidermal parameters in psoriasis vulgaris and in dermatopathology in general. *Top Magn Reson Imaging*, 12(6):375-40.
- Chopade VV, Tankar AN, Pande VV, Tekade AR, Gowekar NM, Bhandari SR, Khandake SN, 2008. *Pongamia pinnata*: Phytochemical constituents, traditional uses and pharmacological properties: A review. *Int J Green Pharm*, 72-75.
- Essa MM, Subramanian P, Suthakar G, Manivasagam T, Dakshayani KB, 2005. Protective influence of *Pongamia pinnata* (Karanja) on blood ammonia and urea levels in ammonium chloride induced hyperammonemia. *J Appl Biomed*, 3:133-8.
- Fugh-Berman A, 2000. Herbs and dietary supplements in the prevention and treatment of cardiovascular disease. *Prev Cardiol*, 3:24-32.
- Gupta YK, Briyal S, 2004. Animal models of cerebral ischemia for evaluation of drugs. *Indian J Physiol Pharmacol*, 48:379-94.
- Joy PP, Thomas J, Mathew S, Skaria BP, 1998. *Medicinal Plants*, Kerala Agricultural University Research Station Publishers, Kerala, India, pp.73.
- Krentz AJ, Bailey CJ, 2005. Oral antidiabetic agents: current role in type 2 diabetes mellitus. *Drugs*, 65:385-411.
- Manoharan S, Punitha R, 2006. Antihyperglycemic and antilipidperoxidative effects of *Pongamia pinnata* (Linn.) Pierre flowers in alloxan induced diabetic rats, *J Ethnopharmacol*, 105:39-46.
- Meher LC, Kulkarni MG, Dalai AK, Naik SN, 2006. Transesterification of karanja (*Pongamia pinnata*) oil by solid basic catalysts. *Eur J Lipid Sci Technol*, 108:389-397.
- Michael P, Schön MP, Boehncke WH, 2005. Medical Progress on psoriasis. *N Engl J Med*, 352:1899-912.
- Punitha R, Manohar S, 2006. Antihyperglycemic and antilipidperoxidative effects of *Pongamia pinnata* (Linn.) Pierre flowers in alloxan induced diabetic rats. *J Ethnopharmacol*, 105:39-46.
- Ramasamy P, Rameshthangam P, 2007. Antiviral activity of bis (2-methylheptyl) phthalate isolated from *Pongamia pinnata* leaves against White Spot Syndrome Virus of *Penaeus monodon* Fabricius, *Virus Res*, 126:38-44.

- Srinivasan K, Muruganandan S, Lal J, Chandra S, Tandan SK, Ravi Prakash V, 2001. Evaluation of anti-inflammatory activity of *Pongamia pinnata* leaves in rats. *J Ethnopharmacol*, 78:151–157.
- Tanaka T, Linuma M, Fujii Y, Yuki K, Mizuno M, 1992. Flavanoids in root, bark of *Pongamia pinnata*. *Phytochemistry*, 31:993-98.
- Vogel HG, Vogel WH, Scholkens BA, Sandow J, Muller G, Vogel WF, 2002. *Drug discovery and evaluation pharmacological assays*. 2nd Ed. Springer. Berlin, Germany.
- Yin H, Si Z, Wu J, Nan H, Lijuan L, Yang J, 2006. Pongaflavanol: a prenylated flavonoid from *Pongamia pinnata* with a modified ring A. *Molecules*, 11:786-9.