

REGENERATION OF EXTENSOR DIGITORUM LONGUS MUSCLE GRAFTS IN TESTOSTERONE PROPIONATE SUPPLEMENTED RATS*

JAVED I. QAZI AND SHAHZAD A. MUFTI

*Department of Zoology, University of the Punjab, Quaid-e-Azam Campus,
Lahore-54590 (JIQ) and Pakistan Museum of Natural History, Garden Avenue,
Shakarparian, Islamabad (SAM), Pakistan*

Abstract: Exogenous administration of testosterone propionate to normal male rats accelerated the process of skeletal muscle fibre's regeneration following orthotopic transplantations of extensor digitorum longus muscles. At one-week postgrafting period the hormone supplemented muscle grafts were found to attain significantly higher average cross-sectional area of the regenerated muscle fibres than those in the control transplants. The steroid exerted its pronounced anabolic effects during the early phase of muscle regeneration and the experimental grafts looked also better in terms of less deposition of connective tissue and earlier completion of degeneration-regeneration course than the control regenerates. In the later stages of regeneration cross-sectional areas of the regenerated muscle fibres were comparable in both categories of the grafts, however, number of the regenerated muscle fibres appeared higher in the hormone supplied transplants accompanied with little connective tissue deposition.

Key words: Androgens, muscle transplantation, testosterone propionate.

INTRODUCTION

Damaged skeletal muscles regenerate and regain structural and functional characteristics of varying degrees depending on amount and nature of the injury incurred (Carlson, 1985; Brooks and Faulkner, 1990; Islamov *et al.*, 1991; Zacharias and Anderson, 1991; Robertson *et al.*, 1993; Sesodia *et al.*, 1994). Likewise, skeletal muscles also regenerate following various types of graftings (Carlson and Gutmann, 1973; Mufti and Ali, 1977; Carlson *et al.*, 1983; Martin *et al.*, 1990; Qazi and Mufti, 1990; Zamir and Oron, 1993; Chuang *et al.*, 1994). Among the different grafting procedures the model of free skeletal muscle transplantation has been used widely in various experimental studies to understand the mechanism of the regeneration (Grim *et al.*, 1986; Phillips *et al.*, 1987; Schultz *et al.*, 1988; Gulati and Swamy, 1991; Qazi and Mufti, 1997). Concerning clinical applications, free skeletal muscle transplantations have successfully been attempted in a number of cases to cure paralysees of different muscles (Thompson and Wynn-Parry, 1981), anal and urinary incontinences (Gierup and Hakelius, 1978; Hakelius *et al.*, 1978) and for upper limbs

reconstructions (Grotting *et al.*, 1990; Chuang *et al.*, 1994) in addition to many cosmetic surgeries.

At time of transplantation a freely grafted skeletal muscle is an avascular, denervated and tenotomized mass, kept within a bed of surrounding tissues. These conditions subject the graft to necrosis followed by appearance of regenerating muscle fibres within the transplant accompanied by revascularization and reinnervation processes (Carlson and Faulkner, 1983; Womble, 1983; Grim *et al.*, 1986; Carlson, 1989; Schultz, 1989). Ultimately, the regenerated skeletal muscle becomes integrated with its surroundings and starts functioning, however, the structural and functional recoveries of a mature regenerate are only about 50% of the original grafted tissue (Carlson and Faulkner, 1983; Faulkner and Côte, 1986; Baker and Poindexter, 1991).

For its wider clinical applications many efforts have been made to improve the quality of skeletal muscle regenerates. Such studies include ablation of muscles synergistics to the graft (Coan and Tomanek, 1981; Mufti and McNemar, 1986), addition of extra satellite cells or soluble factors from crushed muscle (Bischoff and Heintz, 1994) and application of laser irradiation (Bulyakova, 1992; Weiss and Oron, 1992). One of the ways considered to obtain better skeletal muscle transplants is to study the effects of anabolic hormones, especially androgens on the process of regeneration (Carlson and Faulkner, 1989; Qazi and Mufti, 1989, 1997; Ullman and Oldfors, 1991). Testosterone is a highly myotropic hormone (Allen *et al.*, 1983; Kuhn and Max, 1985) and its deficiency causes muscle atrophy (Miyamoto *et al.*, 1989). Role of this hormone in the process of skeletal muscle regeneration has been studied, in detail, for a testosterone dependent muscle, the levator ani (Max *et al.*, 1981; Mufti, 1985; Mufti and Chaban, 1987; Mufti and Raouf, 1990). Regarding the effects of androgens on regenerating skeletal muscles other than the levator ani, practically little information is available. However, Qazi and Mufti (1989, 1997) have reported that the extensor digitorum longus (EDL) muscle grafts regenerated poorly in orchidectomized rats and the transplants responded positively to exogenous supply of the hormone. The present study was undertaken to observe the effects of testosterone propionate on regenerating EDL muscle grafts in normal (uncastrated) rats. The information reported here is useful for improving the quality of skeletal muscle regeneration and adds further to the understanding of the mechanisms underlying this process.

MATERIALS AND METHODS

Experimental animals

Twenty-seven adult, *Rattus norvegicus*, males were used in this research. The rats weigh at start of the experiment was in the range of 121 to 210 g. They were kept in an animal house with roughly 12 hours dark/light cycle and fed on Lab. prepared food comprising of poultry feed, fish meal, wheat flour, molasses and water (see Ali and Shakoori, 1990). The animals were provided a constant supply of water.

Surgical procedure and hormone administration

The rats were anaesthetized with ether and orthotopic transplantations of both EDL muscles were performed under disinfected conditions. The operated animals were supplied with 0.06% terramycin in drinking water for 3-4 days postoperative. Details of the surgical protocol have been mentioned elsewhere (Qazi and Mufti, 1997). Following the graftings of the muscles the rats were categorized into two groups. One set of the animals (TP) was injected with a solution of testosterone propionate in corn oil in an amount of 1.0 mg/100 g body weight (bw). Second group of the rats received 0.2 ml of corn oil/100 g bw and served as vehicle injected controls (cv). The drug and the vehicle were administered intraperitoneally, each day starting from the day of muscle transplantation.

Processing of grafts for various observations

The operated animals were anaesthetized as mentioned above and the EDL muscle grafts were recovered at each week within a period of one month postgrafting. The regenerates were isolated from the surrounding tissues removed out by cutting the tendinous connections and immediately immersed in 0.9% saline solution to protect them from drying. They were soon weighed and calibrated as mg/100 g bw. Tendons of both sides of the regenerates were then cut away, while mid portions were processed for histological and morphometric analyses. The tissues were fixed in Bouin's fluid for at least 4-6 hours and processed routinely for paraffin embedding and sectioning. Cross and longitudinal sections were cut at 8 μm on a Cambridge rotary microtome. The sections were subsequently stained with haematoxylin and eosin. Photomicrographs of representative sections were taken on a camera fitted microscope.

Morphometric analysis of the regenerated muscle fibres was performed by measuring average cross-sectional area of the fibres within graft. This procedure involved projection of six areas from a cross-section of a given regenerate onto paper with the help of camera lucida. While observing at 400X magnification through the microscope, outlines of individual regenerating/ed muscle fibres falling within 17x14 cm sample area on the paper were traced for each of the six areas. Magnification of the microscopic image on the paper was determined by projecting and tracing the divisions of a stage micrometer. Cross-sectional areas of outlines of the muscle fibres were then measured by a K-E polar Planimeter. Readings of the planimeter (cm^2) were calibrated as (μm)² by the following formula:

$$\text{Cross-sectional area } (\mu\text{m})^2 = \frac{\text{Planimeter reading} \times 10^8}{(\text{Magnification})^2}$$

Average cross-sectional area of regenerated muscle fibres was calculated for each cross-section representing a given sample. Statistical difference of the experimental EDL muscle grafts from the controls was then assessed by applying Student's 't' test.

RESULTS

Weight of animals and EDL muscle grafts

A gradual increase in weights of the control rats was observed throughout the study period and upto 2-week postgrafting there was no difference in the % body weight gain in the CV and TP rats. However, at 3- and 4-week stages the increase in body weights of the hormone supplemented animals was found significantly less than the respective controls (Table 1).

Table I: Percent gain in the body weights (A) and percent recovery in weights of the EDL muscle regenerates (B) during the postgrafting periods in the control (CV) and testosterone propionate supplemented (TP) rats.

Experi- mental group	Time postgrafting (weeks)							
	1		2		3		4	
	A	B	A	B	A	B	A	B
CV	10.47 ^a ±0.96 (4)	65.77 ^b ±4.26 (3)	18.41 ±3.39 (4)	39.58 ±0.62 (4)	33.67 ±4.83 (4)	40.91 ±6.39 (3)	49.99 ±5.90 (4)	32.53 ±2.62 (4)
TP	11.71 ±3.81 (4)	53.05 ±4.87 (4)	18.76 ±1.22 (4)	38.34 ±3.85 (3)	5.75 ^{**} ±5.57 (4)	40.45 ±5.06 (4)	5.93 [*] ±10.90 (4)	55.04 [*] ±5.51 (4)

a: body weights taken in grams; b: weights of EDL muscles regenerates calibrated as mg/100 g b.w. Values are means ± SEM; asterisks show significant difference. * = P<0.05; ** = P<0.01. Number in parenthesis indicates sample size (Student's 't' test).

Weights of the muscle regenerates in the TP rats were significantly higher at 2- and 4-week stages, than the respective control transplants. Average weights of 2-week EDL muscle regenerates in CV and TP rats turned out as 22.45±0.82 and 29.71±2.81 (mg/100 g bw), respectively, while the corresponding figures for one-month old regenerates were 19.96±1.34 and 32.23±3.64. When grafts were calibrated as % of original mass, the 4-week TP transplants showed a significant increase as compared to the controls (Table I).

Histological observations

One-week EDL muscle grafts in the TP rats, looked quite better than the respective CV transplants (Fig.1A-F). One-week control graft contained a considerable number of centrally located necrotic and peripheral original surviving muscle fibres. Fascicles of regenerating muscle fibres in such grafts were seen well separated from each other with elaborate amount of connective tissue in between them (Fig.1A,C). The hormone supplemented transplants looked entirely different as there were no central necrotic muscle fibres, thus the degeneration phase had already completed its course and the

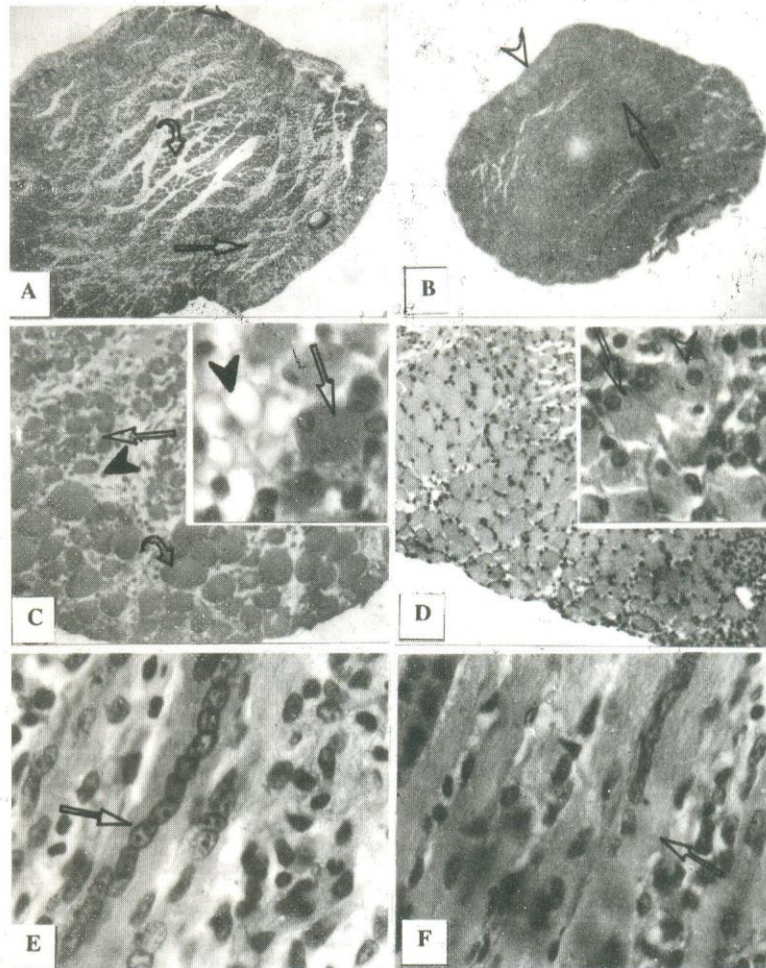


Fig. 1: One-week control (CV) and testosterone propionate supplemented (TP) EDL muscle grafts. **A.** CV graft showing regenerating (arrow), necrotic (curved arrow) and original surviving muscle fibres (o.s.m.f.) (arrow head). C.S. 40X. **B.** TP graft indicating regenerated muscle fibres (r.m.f.) (arrow) and tendon (arrow head), C.S. 40X. **C.** CV graft, showing fascicles of regenerating myotubes (arrow), (o.s.m.f.) (curved arrow) and connective tissue (arrow head), 100X. Inset: A well developed r.m.f. (arrow) and fat deposition (arrow head), C.S. 400X. **D.** TP graft showing fascicles of r.m.f. with very little connective tissue, 100X. Inset: Compactly arranged regenerated (arrow) and regenerating (arrow head) muscle fibres, C.S. 400X. **E.** CV graft, showing r.m.f. (arrow) and connective tissue, L.S. 400X. **F.** TP graft illustrating closely packed mature r.m.f. (arrow) with very little connective tissue, L.S. 400X. *Note:* All the sections were stained with H&E.

regeneration processes were operative well in advance as compared to the situation found in the control regenerates (Fig.1B,D). The muscle grafts in the TP rats were filled with compactly arranged regenerated muscle fibres, with scanty amount of connective tissue in between the fascicles, while regenerated muscle fibres were very thinly distributed and varied greatly in size in the control grafts which also contained extensive amount of connective tissue. Notable amount of adipose tissue formation was also observed in the CV transplants, but the situation was not encountered in the TP regenerates (Fig.1C,D). Longitudinal sections of the grafts also presented the same picture. The CV regenerates contained elaborate amount of connective tissue and the regenerating muscle fibres were observed at an early stage of regeneration; with chain of centrally located nuclei (Fig.1E). On the other hand, in TP grafts there was very little connective tissue and the transplants contained well developed and mature muscle fibres, with peripherally located nuclei (Fig.1F).

At 2-week stage the TP grafts contained relatively lesser amount of connective tissue and appeared to have many more regenerated muscle fibres (hyperplasia) than in the respective controls. These fibres, however, appeared to have cross-sectional areas comparable to the fibres in the control grafts (Fig.2A,B). At 3-week postgrafting the regenerated muscle fibres within the control grafts had undergone further growth and development and connective tissue had correspondingly decreased (Fig.2C). The situation was more or less similar in the TP grafts and the overall quality of muscle regeneration in such grafts did not differ much from the controls (Fig.2D). By the end of 4th week, the control as well as the hormone supplemented grafts were observed to contain developed, mature regenerated muscle fibres, compactly arranged into muscle fascicles. The fibres in both categories of the muscle regenerates at this stage appeared of about same dimensions. However, number of the muscle fibres in the TP grafts looked more than in the controls and they were found compactly arranged with polygonal morphologies in cross-sections. The two types of the grafts also differed in having the amount of connective tissue which was more in the CV transplants (Fig.2E,F).

Morphometric observations

The morphometric data were found in fair agreement with the histological observations. The average cross-sectional area (ACSA) of the regenerated muscle fibres in 1-week TP grafts was about 55% larger than in the control grafts. Except for the significant difference at this stage there were almost no differences between the ACSAs of the regenerated muscle fibres of the CV and TP grafts, for the remaining study periods (Table 2). It appeared that in the latter stages of regeneration the EDL muscle grafts responded to the hormone supply via hyperplasia (Fig.2C,D), while hypertrophy of the regenerated muscle fibres was observed in the earlier phase.

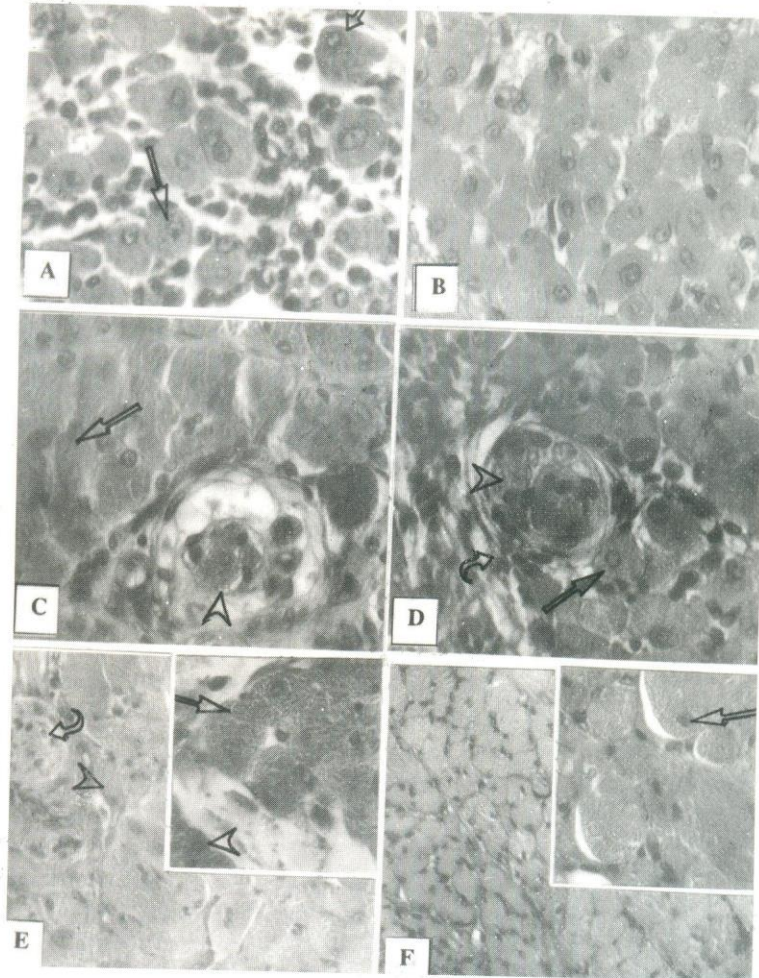


Fig. 2: **A.** Two-week CV graft, showing newly r.m.f. (arrow), some developed ones (curved arrow) and connective tissue, 400X. **B.** Two-week TP graft illustrating r.m.f. with very little connective tissue, 400X. **C.** Three-week CV graft showing r.m.f. (arrow) and a muscle spindle (arrow head), 400X. **D.** Three-week TP graft illustrating r.m.f. (arrow), connective tissue (curved arrow) and a muscle spindle (arrow head), 400X. **E.** Four-week CV graft showing mature r.m.f. fibres of smaller sizes (arrow head) and a nerve (curved arrow), 100X. Inset: A fascicle of developed r.m.f. (arrow) and some with centrally located nuclei (arrow head), 400X. **F.** A four-week TP graft, showing hyperplasia and polygonal shapes of r.m.f., 100X. Inset: Peripheral position of nuclei in mature r.m.f. (arrow) with very little connective tissue in between them, 400X. *Note:* All the photographs represent cross-sections stained with H&E.

Table II: Average cross-sectional areas (μm^2) of regenerated muscle fibres of the EDL muscle grafts in the CV and TP rats.

Type of graft	Stages of regeneration			
	1 week	2 week	3 week	4 week
CV	121.73 ^a ± 17.23 ^b N=567 (3)	213.54 ± 9.00 N=464 (3)	198.82 ± 29.69 N=558 (3)	239.68 ± 9.71 N=605 (4)
TP	189.09* ± 16.34 N=379 (3)	196.87 ± 22.01 N=658 (4)	182.59 ± 40.06 N=467 (3)	215.37 ± 35.56 N=770 (4)

a: Mean \pm SEM; b: total number of the regenerated muscle fibres of all samples taken into account for measurement of cross-sectional areas. Asterisk shows significant difference ($P < 0.05$). Number in parenthesis indicates the sample size (Student's 't' test).

DISCUSSION

Administration of testosterone propionate to normal rats did accelerate the earlier phase of the process of regeneration following orthotopic transplantation of EDL muscles. As at 1-week stage the muscle regenerates in the hormone supplemented animals attained mature regenerated muscle fibres with significantly higher cross-sectional areas than those found in the control grafts. Connective tissue element and fat deposition were much less in the TP grafts and these regenerates did not contain central mass of necrotic muscle fibres. However, the significant hypertrophy of the regenerated muscle fibres in the TP rats at the first sampling period was not observed for the remaining stages. Rather the hormone treated muscle transplants in the later stages indicated hyperplasia and the one-month old regenerates showed significantly higher % recovery in terms of the wet weight than the control grafts.

The results indicate synthesis of androgen receptors in the earlier phase of the muscle fibres' regeneration. It is well known that response of target tissue to steroid hormones is mediated and dependent on variations of cellular content of receptor proteins (Saartok *et al.*, 1984; Baulieu and Master, 1989). Formation of androgen receptors has been reported to occur in regenerating levator ani muscles in rats within few days following crush injuries (Max *et al.*, 1981; Mufti, 1985). Another mode of action of androgens on regeneration of skeletal muscle is mediated through the process of reinnervation: Re-establishment of neural connection with a muscle graft is prerequisite for development, growth and final functional differentiation of the regenerated muscle fibres (Carlson, 1988, 1989; Melone *et al.*, 1990; Sesodia *et al.*, 1994). In this connection it is important to note that the regeneration of axotomized motoneurons has

been shown to be influenced positively by androgens in various experimental animals such as in rats (Kujawa *et al.*, 1993) and in hamsters (Jones and Oblinger, 1994; Kinderman and Jones, 1994).

Apart from the growth promoting effects of testosterone propionate on regenerating muscle fibres, acting via better reinnervation of the muscle grafts the hormone also appeared to enhance the process of revascularization. Breakdown and removal of necrotic muscle fibres within a graft is accomplished by cell-mediated destruction. On the invasion of ingrowing capillaries to the ischaemic zone of a muscle graft, large number of macrophages phagocytize necrotic sarcoplasm of the dead original muscle fibres (Hansen-Smith and Carlson, 1979; Carlson, 1982). And speed of regeneration of muscle fibres in ischaemic EDL muscles in rats has been shown to be directly proportional to the rate of revascularization (Jennische, 1985, 1986). Results of this investigation indicated that the degeneration/ regeneration processes in the hormone supplemented grafts commenced quite earlier and by the end of first week such transplants comprised of developed regenerated muscle fibres. On the other hand, one-week control grafts contained a considerable number of central necrotic muscle fibres still awaiting for the vascular approach for their destruction and subsequent disappearance. To conclude it is stated that anabolic effects of the steroid on the processes of regeneration can be visualized in terms of rapid revascularization and reinnervation, well grown regenerated muscle fibres, and scarce development of adipose and connective tissues within the muscle transplants.

Significant hypertrophy of regenerated muscle fibres in the experimental grafts observed at the first but not for the remaining sample periods could be related to alterations in the levels of growth hormone. There is ample evidence that anabolic effects of androgens are closely associated with the presence of adequate levels of growth hormone (Kawai *et al.*, 1982; Griffin and Wilson, 1987). And it is also well known that circulating growth hormone concentrations are increased after various kinds of injuries including surgical stress (Charters *et al.*, 1969; Carey *et al.*, 1971; Wright and Johnston, 1975). In the light of these findings it is tempting to speculate that increase in the level of growth hormone might had occurred in the rats following the muscle grafting surgery and elevated level of this hormone enhanced the growth promoting effects of the steroid during the initial phase of the muscle fibres' regeneration. It is, therefore, hypothesized that anabolic effects of androgen on regenerating skeletal muscle fibres may be accentuated by enhancing availability of growth hormone.

REFERENCES

- ALI, S.S. AND SHAKOORI, A.R., 1990. Toxicology of aldrin in rats. *Punjab Univ. J. Zool.*, **5**: 1-56.
- ALLEN, R.E., MASAK, K.C., McALLISTER, P.K. AND MARKEL, R.A., 1983. Effect of growth hormone, testosterone and serum concentration on actin synthesis in cultured satellite cells. *J. Animal Sci.*, **56**: 833-837.

- BAKER, J.H. AND POINDEXTOR, C.E., 1991. Muscle regeneration following segmental necrosis in tenotomized muscle fibres. *Muscle Nerve*, **14**: 348-357.
- BAULIEU, EE AND MESTER, J., 1989. Steroid Hormone Receptors. In: *Endocrinology* (ed. DeGroot, L.J.), Vol.1, W.B. Saunders Company, Philadelphia, pp.16-39.
- BISCHOFF, R. AND HEINTZ, C., 1994. Enhancement of skeletal muscle regeneration. *Developmental Dynamics*, **201**: 41-54.
- BROOKS, S.V. AND FAULKNER, J.A., 1990. Contraction-induced injury: Recovery of skeletal muscles in young and old mice. *Am. J. Physiol.*, **258**: C436-C442.
- BULYAKOVA, N.V., 1992. Effect of minced muscle implantation and following laser therapy on guinea pig skeletal muscle regeneration. *Byulleten' Eksperimental noi Biologii i Meditsiny*, **114**: 97-100.
- CAREY, L.C., CLOUTIER, C.T. AND LOWERY, B.D., 1971. Growth hormone and adrenal cortical response to shock and trauma in the human. *Ann. Surg.*, **174**: 451-460.
- CARLSON, B.M., 1982. Development of a free muscle graft. In: *Disorders of the facial nerve* (eds. Graham, M.D. and House, W.F.), pp.487-497. Raven Press, New York.
- CARLSON, B.M., 1985. Reintegration of free muscle grafts in rats. In: *Frey, Freilinger, Proc. 2nd Vienna Muscle Symposium*, (Facultas Universitätsverlag, Vienna), pp.48-51.
- CARLSON, B.M., 1988. Nerve-Muscle interrelationships in mammalian skeletal muscle regeneration. In: *Control of cell proliferation and differentiation during regeneration*. (ed. Anton, H.J.). Karger, Basel, pp.47-56.
- CARLSON, B.M., 1989. Some aspects of regeneration in skeletal and cardiac muscle. In: *Recent trends in regeneration research* (eds. Kiortsis, V., Koussoulakos, S. and Wallace, H.). Plenum Publishing Corporation, pp.147-157.
- CARLSON, B.M. AND FAULKNER, J.A., 1983. The regeneration of skeletal muscle fibres following injury: a review. *Med. Sci. Sports Exercise*, **15**: 187-198.
- CARLSON, B.M. AND FAULKNER, J.A., 1989. Muscle transplantation between young and old rats: age of host determines recovery. *Am. J. Physiol.*, **256**(Cell Physiol. 25): C1262-C1266.
- CARLSON, B.M. AND GUTMANN, E., 1973. Regeneration in freely transplanted intact muscles of the rat. *Anat. Rec.*, **175**: 284 (Abstract).
- CARLSON, B.M., FOSTER, A.H., BADER, D.M., HNIK, P. AND VEJSADA, R., 1983. Restoration of full mass in nerve-intact muscle grafts after delayed reinnervation. *Experientia*, **39**: 171-172.
- CHARTERS, A.C., ODELL, W.D. AND THOMPSON, J.C., 1969. Anterior pituitary function during surgical stress and convalescence. Radioimmunoassay measurement of blood TSH, LH, FSH, and growth hormone. *J. Clin. Endocrinol.*, **29**: 63-71.
- CHUANG, D.C.C., STRAUCH R.J. AND WEI, FC., 1994. Technical considerations in two-stage functioning free muscle transplantation reconstruction of both flexor and extensor functions of the forearm. *Microsurgery*, **15**: 338-343.
- COAN, M.R. AND TOMANEK, R.J., 1981. The growth of regenerating soleus muscle transplants after ablation of the gastrocnemius muscle. *Exp. Neurol.*, **71**: 278-294.
- FAULKNER, J.A. AND CÔTE, C., 1986. Functional deficits in skeletal muscle grafts. *Federation Proc.*, **45**: 1466-1469.

- GIERUP, J. AND HAKELIUS, L., 1978. Free autogenous muscle transplantation in the treatment of urinary incontinence in children: Background, surgical technique and preliminary results. *J. Urol.*, **120**: 223.
- GRIFFIN, J.E. AND WILSON, J.D., 1987. Disorders of the testis. In: *Harrison's principles of internal medicine* (eds. Eugene, B., Kurt, J.I., Robert, G.P., Jean, D.W., Joseph, B.M. and Anthony, S.F.). McGraw-Hill Book Company, Hamburg, pp.1807-1818.
- GRIM, M., MRAZKOVA, O. AND CARLSON, B.M., 1986. Enzymatic differentiation of arterial and venous segments of the capillary bed during the development of free muscle grafts in the rat. *Am. J. Anat.*, **177**: 149-159.
- GROTTING, J.C., BUNCKE, H.J., LINEAWEAVER, W.C., ALPERT, B.S. AND MILLIKEN, R.G., 1990. Functional restoration in the upper extremity using free muscle transplantation. *Ann. Chir. Main. Membre. Super.*, **9**: 98-106.
- GULATI, A.K. AND SWAMY, M.S., 1991. Regeneration of skeletal muscle in streptozotocin-induced diabetic rats. *Anat. Rec.*, **229**: 298-304.
- HAKELIUS, L., GIERUP, J., GROTTING, G. AND JORULF, H., 1978. A new treatment of anal incontinence in children: Free autogenous muscle transplantation. *J. Pediatr. Surg.*, **13**: 77-82.
- HANSEN-SMITH, F.M. AND CARLSON, B.M., 1979. Cellular responses to free grafting of the extensor digitorum longus muscle of the rat. *Jr. Neurol. Sci.*, **41**: 149-173.
- ISLAMOV, R.R., KIYASOV, A.P. AND VAILIULLIN, V.V., 1991. Immunohistochemical study of the rat M. lumbricalis in the different periods of ischemia after allotransplantation to the anterior eye chamber. *Byull. Eksp. Biol., Med.*, **112**: 545-546.
- JENNISCHE, E., 1985. Ischaemia-induced injury in glycogen-depleted skeletal muscle. Selective vulnerability of FG-fibres. *Acta. Physiol. Scand.*, **125**: 722-734.
- JENNISCHE, E., 1986. Rapid regeneration in postischaemic skeletal muscle with undisturbed microcirculation. *Acta. Physiol. Scand.*, **128**: 409-414.
- JONES, K.J. AND OBLINGER, M.M., 1994. Androgenic regulation of tubulin gene expression in axotomized hamster facial motoneurons. *Journal of Neuroscience*, **14**: 3620-3627.
- KAWAI, K., OGATA, E., TAKANO, K., HIZUKA, N., YAMASHITA, K. AND SHIZUME, K., 1982. Effects of testosterone and estradiol on serum somatomedin A and growth rate of rats. *Endocrinol. Jpn.*, **29**: 435-442.
- KINDERMAN, N.B. AND JONES, K.J., 1994. Axotomy-induced changes in ribosomal RNA levels in female hamster facial motoneurons: Differential effects of gender and androgen exposure. *Experimental Neurology*, **126**: 144-148.
- KUHN, F.E. AND MAX, S.R., 1985. Testosterone and muscle hypertrophy in female rats. *J. Appl. Physiol.*, **59**: 24-28.
- KUJAWA, K.A., JACOB, J.M. AND JONES, K.J., 1993. Testosterone regulation of the regenerative properties of injured rat sciatic motor neurons. *J. Neurosci. Res.*, **35**: 268-273.
- MARTIN, T.P., GUNDERSEN, L.A., VAILAS, A.C., EDGERTON, V.R. AND DAS, S.K., 1990. Incomplete normalization of dog gracilis muscle grafts with neurovascular repair despite long-term recovery. *J. Appl. Physiol.*, **68**: 687-692.

- MAX, S.R., MUFTI, S.A. AND CARLSON, B.M., 1981. Cytosolic androgen receptor in regenerating rat levator ani muscle. *Biochem. J.*, **200**: 77-82.
- MELONE, M.A.B., DE-LUCIA, D., FRATTA, M. AND COTRUFO, R., 1990. Regenerated EDL muscle of rats requires innervation to maintain AChE molecular forms. *Muscle Nerve*, **13**: 713-721.
- MIYAMOTO, N., NOMURA, Y., SUEDA, K., KAMBE, F., INOUE, I., MURATA, Y., SEO, H. AND MATSUI, N., 1989. Involvement of corticosterone and testosterone in muscle atrophy of rat hindlimb induced by tail suspension. *Environ. Med. (Nagoya)*, **33**: 59-62.
- MUFTI, S.A., 1985. Autoradiographic analysis of androgen receptor formation in regenerating levator ani muscle of rats. *Pakistan J. Zool.*, **17**: 405-410.
- MUFTI, S.A. AND ALI, R.A., 1977. Tissue regeneration of muscle in frog. *Pakistan J. Zool.*, **9**: 27-33.
- MUFTI, S.A. AND CHABAN, J.B., 1987. Regeneration of levator ani muscle following crush injury in gonadectomized rats. *Pakistan J. Zool.*, **19**: 349-359.
- MUFTI, S.A. AND McNEMAR, T.B., 1986. Morphological and morphometric analysis of overloaded plantaris muscle grafts in rats. *Pakistan J. Zool.*, **18**: 239-246.
- MUFTI, S.A. AND RAOUF, N., 1990. Effect of gonadectomy on the regeneration of intact levator ani muscle grafts. *Pakistan J. Zool.*, **22**: 23-36.
- PHILLIPS, G.D., LU, D., MITASHOV, V.I. AND CARLSON, B.M., 1987. Survival of myogenic cells in freely grafted rat rectus femoris and extensor digitorum longus muscles. *Am. J. Anat.*, **180**: 365-372.
- QAZI, J.I. AND MUFTI, S.A., 1989. Regeneration of testosterone-deprived and testosterone-stimulated extensor digitorum longus muscle grafts. *Sci. Int. (Lahore)*, **1**: 370-375.
- QAZI, J.I. AND MUFTI, S.A., 1990. Regeneration of skeletal muscle grafts in hypoinsulinaemic rats. *Pakistan J. Zool.*, **22**: 263-270.
- QAZI, J.I. AND MUFTI, S.A., 1997. Effects of androgens on nucleic acids and protein contents in regenerating extensor digitorum longus muscle following orthotopic transplantation in rats. *Punjab Univ. J. Zool.*, **12**: 115-125.
- ROBERTSON, T.A., PAPADIMITRIOU, J.M. AND GROUNDS, M.D., 1993. Fusion of myogenic cells to the newly sealed region of damaged myofibres in skeletal muscle regeneration. *Neuropathol. Appl. Neurobiol.*, **19**: 350-358.
- SAARTOK, T., DAHLBERG, E. AND GUSTAFSSON, J.Å., 1984. Relative binding affinity of anabolic and androgenic steroids: comparison of the binding to the androgen receptors in skeletal muscle and in prostate, as well as to sex-hormone binding globulin. *Endocrinol.*, **114**: 2100-2106.
- SCHULTZ, E., 1989. Satellite cell behavior during skeletal muscle growth and regeneration. *Med. Sci. Sports Exerc.*, **21** (Supplement): S181-S186.
- SCHULTZ, E., ALBRIGHT, D.J., JARYSZAK, D.L. AND DAVID, T.L., 1988. Survival of satellite cells in whole muscle transplants. *Anat. Rec.*, **222**: 12-17.
- SESODIA, S., CHOKSI, R.M. AND NEMETH, P.M., 1994. Nerve-dependent recovery of metabolic pathways in regenerating soleus muscles. *Journal of Muscle Research and Cell Motility*, **15**: 573-581.

- THOMPSON, N. AND WYNN-PARRY, C.B., 1981. Restoration of emotional expression to the unilaterally paralysed face. In: *Muscle transplantation*, (eds. Freilinger, G., Holle, J. and Carlson, B.M.), Springer-Verlag, Wien New York, pp.163-183.
- ULLMAN, M. AND OLDFORS, A., 1991. Skeletal muscle regeneration in young rats is dependent on growth hormone. *Neurol. Sci.*, **106**: 67-74.
- WEISS, N. AND ORON, U., 1992. Enhancement of muscle regeneration in the rat gastrocnemius muscle by low energy laser irradiation. *Anat. Embryol.*, **186**: 497-503.
- WOMBLE, M.D., 1983. Acetylcholine receptor clustering and formation of neuromuscular junctions in regenerating rat skeletal muscle. *Ph.D. Thesis*, University of Michigan, Ann. Arbor.
- WRIGHT, P.D. AND JOHNSTON, I.D.A., 1975. The effect of surgical operation on growth hormone levels in plasma. *Surgery*, **77**: 479-486.
- ZACHARIAS, J.M. AND ANDERSON, J.E., 1991. Muscle regeneration after imposed injury is better in younger than older mdx dystrophic mice. *J. Neurol. Sci.*, **104**: 190-196.
- ZAMIR, S. AND ORON, U., 1993. Autografted minced muscle fragments do not affect muscle regeneration in partially excised rat gastrocnemius muscle. *Pathobiology*, **61**: 173-177.

(Received: September 24, 1998)