

Case Report

Upper GIT Bleeding Due to Gastric Stromal Tumor

A. BENDJABALAH MD, Pr. M. TAIEB, Dr. N.NAIT SLIMANE, Pr. H.RABEHI, Dr. S. AMMARI,
Dr. R.KHIALI

Department of General Surgery Ain Taya Hospital Algiers, Algeria

Abstract

Gastrointestinal stromal tumors (GISTs) are the most common mesenchymal neoplasms of the gastrointestinal tract (GIT) and are thought to develop from the smooth muscle pacemaker interstitial cells of Cajal, innervated cells associated with the Auerbach plexus. They are defined as tumors whose behavior is driven by mutations in the *KIT* gene (CD117). *KIT* (CD117) in the tumor cells, as these activating *KIT* mutations are seen in 85-95% of GISTs. 95% of GISTs stain positively for *KIT* (CD117). They are tumors of connective tissue, i.e. sarcomas; unlike most gastrointestinal tumors, they are nonepithelial. About 70% occur in the stomach, 20% in the small intestine and less than 10% in the esophagus. Small tumors are generally benign, especially when cell division rate is slow, but large tumors disseminate to the liver, omentum and peritoneal cavity. They rarely occur in other abdominal organs. We report a case of gastric stromal tumor which was revealed by upper GI bleeding in a young woman.

Keywords: Gastro intestinal stromal tumors, Mesenchymal neoplasms, *KIT* gene (CD117), Stomach, Upper GIT bleeding, Radio chemotherapy

INTRODUCTION

Gastrointestinal stromal tumors (GISTs) account for less than 1% of gastrointestinal tumors, however, it is the most common mesenchymal neoplasms of the gastrointestinal tract. GISTs are usually found in the stomach or small intestine but can occur anywhere along the gastrointestinal tract and rarely have extra gastrointestinal involvement (Zhao and Yue, 2012). GISTs rank a distant third in prevalence behind adenocarcinomas and lymphomas among the histologic types of gastrointestinal tract tumors. GIST was introduced as a diagnostic term in 1983. (Demetri et al., 2011). Until the late 1990s, many non-epithelial tumors of the gastrointestinal tract were called "gastrointestinal stromal tumors". Histopathologists were unable to specifically distinguish between types known to be dissimilar molecularly. About 3-5% of the remainder of *KIT*-negative GISTs contain PDGFR alpha GISTs have a lower malignant potential than tumors found elsewhere in the GI tract (Demetri et al., 2011; Miettinen and Lasota, 2006). Subsequently, CD34, and later

CD117 were identified as DNA markers that could distinguish the various types. Additionally, in the absence of specific therapy, the diagnostic categorization had only a limited influence on prognosis and therapy. The understanding of GIST biology changed significantly with the identification of the molecular basis of GIST (Demetri et al., 2011), particularly c-*KIT*. Historically, literature reviews prior to the molecular definition of GIST, and for a short time thereafter, asserted that 70-80% of GISTs were benign (Burkill et al., 2003; JNishida and Hirota, 2000; Miettinen and Lasota, 2001). The identification of a molecular basis for GIST led to the exclusion of many tumors that had been considered as GIST previously, and also the incorporation of a much larger number of tumors that had been labeled as other types of sarcomas and undifferentiated carcinomas (Demetri et al., 2011).

Case report

A patient of 36 years, without particular history, was admitted for gastrointestinal bleeding, urgently average abundance type of hematemesis. Clinical examination after resuscitation and blood transfusions showed an

*Corresponding Author E-mail: ali_bendjaballah@yahoo.fr;
Tel: +213-551-764-640

average condition with severe cutaneous mucosa pallor. The abdominal palpation revealed epigastric mass, hard and mobile. The numeration blood count revealed microcytic anemia with a hemoglobin 7 g / dl. Gastroscopy showed a lesion looks ulcerated antral mucosa in actively saignant tablecloth. The biopsy showed a chronic gastritis appearance. The ultrasound and abdominal pelvic CT scan revealed a tumor mass 78/54/50 mm dimensions sitting at the small gastric curvature and exoluminale development. The tumor markers were normal. The diagnosis was discussed gastrointestinal stromal tumor. The indication for surgery was successful. The patient was operated by a midline incision and a gastrectomy was performed by 4/5. The postoperative period was simple. CD117 immunostaining and CD 34 were positive.

DISCUSSION

Gastrointestinal stromal tumors (GISTs) are uncommon tumors of the GI tract. These tumors start in very early forms of special cells found in the wall of the GI tract, called the *interstitial cells of Cajal* (ICCs). ICCs are cells of the autonomic nervous system, the part of the nervous system that regulates body processes such as digesting food. ICCs are sometimes called the “pacemakers” of the GI tract because they signal the muscles in the digestive system to contract to move food and liquid through the GI tract. More than half of GISTs start in the stomach. Most of the others start in the small intestine, but GISTs can start anywhere along the GI tract. A small number of GISTs start outside the GI tract in nearby areas such as the omentum (an apron-like layer of fatty tissue that hangs over the organs in the abdomen) or the peritoneum (the layer of tissue that lines the organs and walls of the abdomen) (JNishida and Hirota, 2000).

Not all GISTs are cancerous. Some are benign (not cancerous) and don't grow into other areas or spread to other parts of the body. These are discussed in the section, “GISTs occur in 10-20 per one million people. The true incidence might be higher, as novel laboratory methods are much more sensitive in diagnosing GISTs. The estimated incidence of GIST in the United States is approximately 5000 cases annually (Demetri et al., 2011). This makes GIST the most common form of sarcoma, which constitutes more than 70 types of cancer. The majority of GISTs present at ages 50–70 years. Across most of the age spectrum, the incidence of GIST is similar in men and women (Kantarjian et al., 2011). Adult GISTs are rare before age 40. Pediatric GISTs are considered to be biologically distinct (Zhao and Yue, 2012). Unlike GISTs at other ages, pediatric GISTs are more common in girls and young women. They appear to lack oncogenic activating tyrosine kinase mutations in both KIT and PDGFRA (Kelly et al., 2013).

Pediatric GISTs are treated differently than adult GIST. Although the generally accepted definition of pediatric GIST is a tumor that is diagnosed at the age of 18 years or younger, (Zhao and Yue, 2012) "pediatric-type" GISTs can be seen in adults, which affects risk assessment, the role of lymph node resection, and choice of therapy (Agaimy and Hartmann, 2010). Up to 75% of GISTs are discovered when they are less than 4 cm in diameter and are either asymptomatic or associated with nonspecific symptoms. They are frequently diagnosed incidentally during radiologic studies or endoscopic or surgical procedures performed to investigate the GI tract disease or to treat an emergent condition such as hemorrhage, obstruction, or perforated viscus (Zhao and Yue, 2012). Most GISTs are sporadic. Less than 5% occur as part of hereditary familial or idiopathic multitumor syndrome. These include, in descending order of frequency, neurofibromatosis Recklinghausen (NF-1) Carney's triad (Gastric GIST, pulmonary chondroma and extra-adrenal paraganglioma), germline gain of function mutations in c-Kit/PDGFR α , and the Carney – Stratakis syndrome (Agaimy and Hartmann, 2010). GISTs have no known racial proclivity. However, Cheung et al reported that out of 3795 patients diagnosed with mesenchymal tumors from the Surveillance, Epidemiology, and End Results (SEER) database from 1992-2005, more than 88% of tumors were identified as GIST with patient demographics as follows: 72.2% Caucasians, 15.6% African Americans, and 9.1% Hispanics (Cheung et al., 2009). SEER (Surveillance, Epidemiology, and End Results) data from 1992-2000 report a slightly higher prevalence in males versus females, at 54% and 46%, respectively (Tran et al., 2005). GISTs have been reported in all age groups including infants. It is extremely rare in patients younger than 30 years. In a study of 1765 gastric GISTs, the median age at diagnosis was 63 years (Miettinen et al., 2005). In a series consisting of 906 jejunal and ileal GISTs, the mean age was 59 years. (Miettinen et al., 2006). In the latter 2 series, only 2.7% of gastric GISTs and 0.6% of small bowel GISTs were detected in patients younger than 21 years. GIST's may present with trouble swallowing, gastrointestinal hemorrhage as is the case with younger patient, or metastases (mainly in the liver). Intestinal obstruction is rare due to the tumor's outward pattern of growth. Often there is history of vague abdominal pain or discomfort, and the tumor has become rather large by time the diagnosis is made. The definitive diagnosis is made with a biopsy, which can be obtained endoscopically, percutaneously with CT scan or ultrasound guidance or at the time of surgery. A biopsy sample will be investigated under the microscope by a pathologist physician. The pathologist examines the histopathology to identify the characteristics of GISTs (spindle cells in 70-80%, epithelioid aspect in 20-30%). Smaller tumors can usually be confined to the muscularis propria layer of the intestinal wall. Large ones grow, mainly outward, from the bowel wall until the point

where they outstrip their blood supply and necrose (die) on the inside, forming a cavity that may eventually come to communicate with the bowel lumen. When evaluating patients with suspected GISTs, some differential diagnoses must be raised in the case of epithelioid hemangioendothelioma, Fibromatosis, Lymphoma, Metastatic melanoma and Schwannoma. When GIST is suspected—as opposed to other causes for similar tumors—the pathologist can use immunohistochemistry (specific anti bodies that stain the molecule CD117 “also known as *c-kit*”). 95% of all GISTs are CD117-positive (other possible markers include CD34, DOG-1, desmin, and vimentin). Other cells that show CD117 positivity are mast cells. If the CD117 stain is negative and suspicion remains that the tumor is a GIST, the newer antibody DOG-1 (Discovered on GIST-1) can be used. Also sequencing of Kit and PDGFRA can be used to prove the diagnosis (Pidhorecky et al., 2000). In our case the result of histopathological examination was showing in “Photo 1” a kcd117 and in “Photo 2” a negative caldesmone and finally in “Photo 3” a negative caldesmone.

The aims of radiology and imaging are to locate the lesion, evaluate for signs of invasion and detect metastasis. Features of GIST vary depending on tumor size and organ of origin. The diameter can range from a few millimeters to more than 30 cm, in our case it was so great (78/54/50 mm), we were able to palpate it. Larger tumors usually cause symptoms in contrast to those found incidentally which tend to be smaller and have better prognosis (Burkill et al., 2003; Hersh et al., 2005). Large tumors tend to exhibit malignant behavior but small GISTs may also demonstrate clinically aggressive behavior (Pidhorecky et al., 2000). As the tumor grows it may project outside the bowel (exophytic growth) and/or inside the bowel (intraluminal growth), but they most commonly grow exophytically such that the bulk of the tumor projects into the abdominal cavity. If the tumor outstrips its blood supply, it can necrose internally, creating a central fluid-filled cavity with hemorrhage and cavitations that can eventually ulcerate and communicate into the lumen of the bowel. In that case, barium swallow may show an air, air-fluid levels or oral contrast media accumulation within these areas (Pidhorecky et al., 2000; Lehnert, 1998). CT characteristics of large GISTs (>10 cm) are Irregular margins -Heterogeneous densities- Locally aggressive behavior and Distant and peritoneal metastases (Tran et al., 2005). Mucosal ulcerations may also be present. In contrast enhanced CT images, large GISTs appear as heterogeneous masses due to areas of living tumor cells surrounding hemorrhage, necrosis or cysts, which is radiographically seen as a peripheral enhancement pattern with a low attenuation center (Hersh et al., 2005). In MRI studies, the degree of necrosis and hemorrhage affects the signal intensity pattern. Areas of hemorrhage within the tumor will vary its signal intensity depending on how long ago the

hemorrhage occurred. The solid portions of the tumor are typically low signal intensity on T1-weighted images, are high signal intensity on T2-weighted images and enhance after administration of gadolinium. Signal-intensity voids are present if there is gas within areas of necrotic tumor (Shojaku et al., 1997; Levine et al., 1996; Tervahartiala and Halavaara, 1998). In a CT scan, abnormalities may be seen in 87% of patients and it should be made with both oral and intravenous contrast (Pidhorecky et al., 2000). Among imaging studies, MRI has the best tissue contrast, which aids in the identification of masses within the GI tract (intramural masses). Intravenous contrast material is needed to evaluate lesion vascularity. Preferred imaging modalities in the evaluation of GISTs are CT, MRI (Ulusan et al., 2008; National Comprehensive Cancer Network, 2012) and, in selected situations, endoscopic ultrasound. CT advantages include its ability to demonstrate evidence of nearby organ invasion, ascites and metastases. The ability of MRI to produce images in multiple planes is helpful in determining the bowel as the organ of origin (which is difficult when the tumor is very large), facilitating diagnosis. Magnetic resonance imaging: Like CT scanning, it can depict tumors and yield information about surrounding structures. Can also be used to detect the presence of multiple tumors and metastases and less well studied than CT for diagnosing GISTs, but appears equally sensitive (Nilsson et al., 2005). GISTs may appear hypointense on T2-weighted images (Agaram et al., 2008). Endoscopy: frequently performed early in the workup of patients with GI bleeding, abdominal pain, or GI obstructive symptoms from GISTs. Endoscopic features of GISTs include the suggestion of a smooth submucosal mass displacing the overlying mucosa. However ulceration or bleeding of the overlying mucosa from pressure necrosis may be present. There problematic for biopsy specimen collection because of the submucosal location of GISTs and endoscopic biopsy results yield a diagnosis in less than 50% of cases (Ghanem et al., 2003). Endoscopic ultrasonography (EUS), is a great contribution In GIST's. It allows localization of lesions and their characterization by ultrasonography with fine-needle aspiration biopsy specimens may be obtained under sonographic guidance. GISTs typically appear as a hypoechoic mass in the layer corresponding to the muscularis propria. It is complementary with CT (Zhou et al., 2012) and more accurate than CT in differentiating benign from malignant lesions. The EUS characteristics of malignant GISTs include the size larger than 4 cm (the only independent predictor), heterogeneous echogenicity, internal cystic areas and irregular borders on the extraluminal surfaces (Tateishi et al., 2003). On the other hand the EUS features that may help differentiate gastric GISTs from leiomyomas are: Inhomogeneity, hyperechogenic spots, a marginal halo and higher echogenicity than the surrounding muscle layer (Shojaku et al., 1997). Outcomes in patients with GISTs are highly dependent

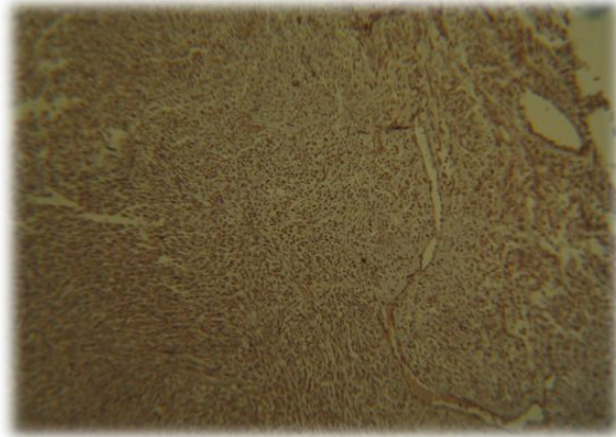


Photo 1. Histopathological image showing a kcd117

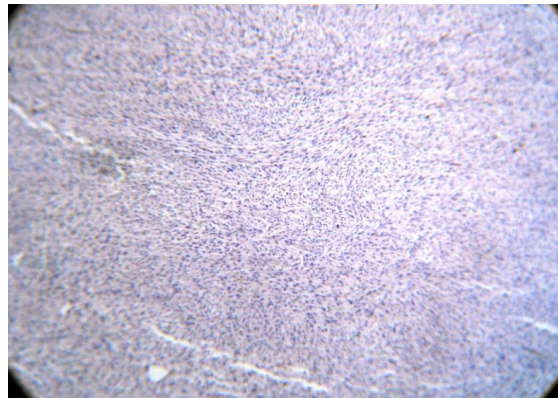


Photo 2. Histopathological image showing a negative caldesmone

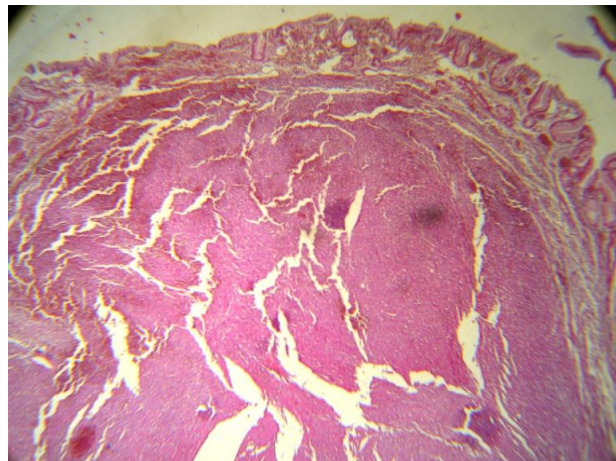


Photo 2. Histopathological image of gastrointestinal stromal tumor of the stomach. (Hematoxylin-eosin stain)

on the clinical presentation and the histopathological features of the tumor. The overall 5-year survival rate ranges from 28-60%. This can be stratified for patients presenting with localized primary disease and those

presenting with metastatic or recurrent disease. The median survival rate in the former group is 5 years, while the median survival rate in the latter group is approximately 10-20 months. Larger GISTs are

associated with complications such as GI hemorrhage, GI obstruction, and bowel perforation. This is discussed further in Surgical Care and Complications. Tumors can be classified into high and low-risk categories based on size, location, and mitotic activity (Joensuu et al., 2012).

Surgery is the primary treatment of choice in localized resectable adults GIST's (National Comprehensive Cancer Network, 2012) Surgery can be potentially curative, but vigilant waiting may be considered in small tumors in carefully selected situations (Casali and Blay, 2010). Post-surgical adjuvant treatment may be recommended (Bamboot, 2012). Lymph node metastases are rare, and routine removal of lymph nodes is typically not necessary. Laparoscopic surgery, a minimally invasive abdominal surgery using telescopes and specialized instruments, has been shown to be effective for removal of these tumors without needing large incisions (Nguyen et al., 2006). The clinical issues of exact surgical indications for tumor size are controversial. The decision of appropriate laparoscopic surgery is affected by tumor size, location, and growth pattern. However, Laparoscopic resection for GISTs is associated with favorable short-term outcomes without compromising oncologic results (Lee, et al., 2012). Surgery was the only option for our patient after resuscitation and correction of anemia 4/5 gastrectomy was performed. "Photo 4, 5 and 6"

Radiotherapy has not historically been effective for GISTs and GISTs do not respond to most chemotherapy medications (Kantarjian et al., 2011) with responses in less than 5%. (Demetri et al., 2011). However, three medications have been identified for clinical benefit in GIST: imatinib, sunitinib, and regorafenib.

Imatinib (Glivec/Gleevec), an orally administered drug initially marketed for chronic myelogenous leukemia based on bcr-abl inhibition, also inhibits both *c-kit* tyrosine kinases mutations and PDGFRA mutations other than D842V, is useful in treating GIST's in several situations, imatinib has been used in selected neoadjuvant settings (National Comprehensive Cancer Network, 2012; Nilsson et al., 2005). In the adjuvant treatment setting, the majority of GIST tumors is cured by surgery, and does not need adjuvant therapy (Joensuu, 2012). However, a substantial proportion of GIST tumors have a high risk of recurrence as estimated by a number of validated risk stratification schemes, and can be considered for adjuvant therapy (Joensuu, 2012; Reichardt et al., 2012). The selection criteria underpinning the decision for possible use of imatinib in these settings include a risk assessment based on pathological factors such as tumor size, mitotic rate, and location can be used to predict the risk of recurrence in GIST patients. Tumors <2 cm with a mitotic rate of <5/50 HPF have been shown to have lower risk of recurrence than larger or more aggressive tumors. Following surgical resection of GISTs, adjuvant treatment with imatinib reduces the risk of disease recurrence in higher

risk groups. In selected higher risk adjuvant situations, imatinib is recommended for 3 years (Cohen et al., 2012). Imatinib was approved for metastatic and unresectable GIST by the US FDA, February 1, 2002. The two year survival of patients with advanced disease has risen to 75–80% following imatinib treatment (Patel Shreyaskumar and Wong Patrick, 2009). If resistance to imatinib is encountered, the multiple tyrosine kinase inhibitor sunitinib (marketed as Sutent) can be considered (National Comprehensive Cancer Network, 2012; Okuno, 2011). The effectiveness of imatinib and sunitinib depend on the genotype (Genetic Engineering and Biotechnology News (2008) cKIT- and PDGFRA-mutation negative GIST tumors are usually resistant to treatment with imatinib (Lehnert, 1998) as is neurofibromatosis-1-associated wild-type GIST (Joensuu, 2012). A specific subtype of PDGFRA-mutations, D842V, is also sensitive to imatinib. (Joensuu, 2012), fenib (Stivarga) was FDA approved in 2013 for advanced GISTs that cannot be surgically removed and that no longer respond to imatinib (Gleevec) and sunitinib (Sutent) (Pazdur, 2007).

The predominant prognostic factors in patients with GISTs include the size of the tumor, location of the tumor, and the mitotic rate. To these may be added the ability or inability to achieve completely negative resection margins.

Reported 5-year disease-specific survival rates are 30-60% according to results reported by many studies (eg, DeMatteo et al, 2000 and 2002; Crosby et al. 2001; Carney, 1999; Conlon et al. 1995). The disparity between patients presenting with localized primary disease (median survival of 5 y) and those presenting with metastasis or recurrent disease (median survival of 10-20 mo) is large. Location is also significant. Patients with gastric GISTs tend to fare better than those with extragastric GISTs. The importance of the mitotic count as a prognostic factor and predictor of malignant behavior was illustrated by Dougherty et al. 1991. Even after curative resections, patients with a mitotic rate of 10 or greater per 50 high-power fields (HPFs) had a median survival rate of 18 months, compared with an 80%, 8-year disease-free survival rate in patients who had curative resections and tumors with a mitotic rate less than 10/50 HPFs. Mutational status has both prognostic significance and impact on response to tyrosine kinase inhibitor therapy. In randomized clinical trials, the presence of a KIT exon 11 mutation was associated with better response, progression-free survival, and overall survival rates than KIT exon 9 mutant GISTs. The risk for progression and death were increased in patients with no detectable KIT or PDGFRA mutations (Agaram et al., 2008).

CONCLUSION

Digestive hemorrhage is a classic complication of gastric

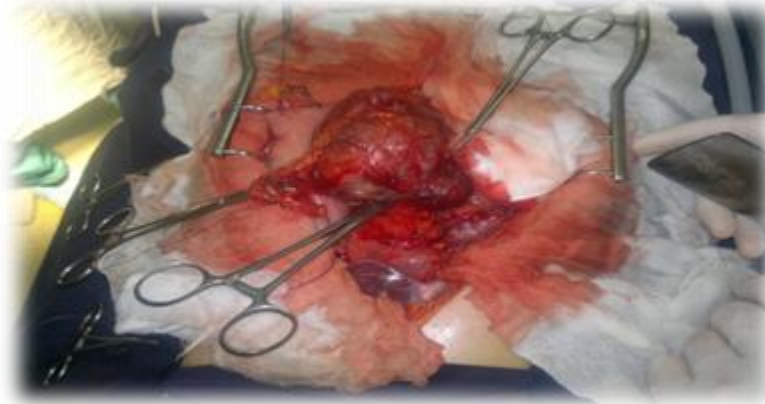
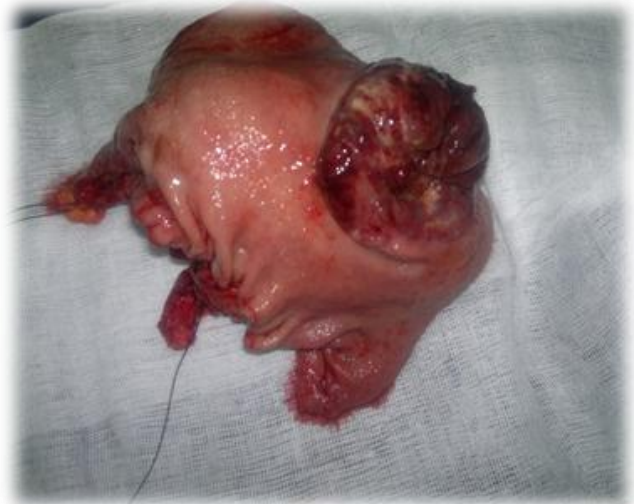
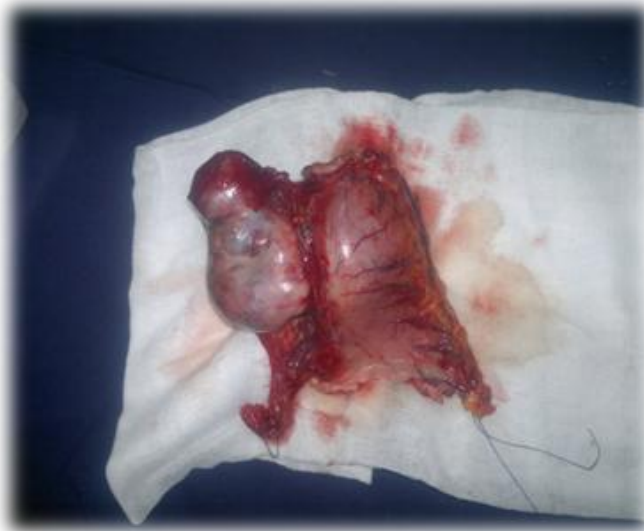
Photo 3. Shown gastric mass (GIST) after midline laparotomy



Photos 4 and 5. Shown gastric tumor after gastrectomy

Stromal Tumors; It represents 10% of all complications of these diseases. Prior to any upper gastrointestinal bleeding associated with a submucosal mass endoscopy is indicated in emergency, the diagnosis of stromal tumor should be mentioned about bearing in mind other differential diagnosis. It should be noted that the gastric location is the most common and is better prognosis. The treatment involves surgery which is the only trustee; well that it is no consensus on the margins of resection, a distance of 1a2cm is sufficient. Radio-chemotherapy has no effect.

REFERENCES

- Agaimy A, Hartmann A (2010). [Hereditary and non-hereditary syndromic gastrointestinal stromal tumours]. [in German] *Pathologie*. Oct;31(6):430-7. doi: 10.1007/s00292-010-1354-6
- Agaram NP1, Wong GC, Guo T, Maki RG, Singer S, Dematteo RP, Besmer P, Antonescu CR (2008). Novel V600E BRAF mutations in imatinib-naive and imatinib. Resistant gastrointestinal stromal tumors. *Genes Chromosomes Cancer*. Oct. 47(10):853-9
- ASCO (2013). ASCO-SEP®, 3rd Edition, Features Digital Formats and Complementary Study Tools
By ASCO April 15, 2013, Volume 4, Issue 6
- Bamboot ZM (2012). "Updates on the management of gastrointestinal stromal tumors". *Surg Oncol Clin N Am* 21 (2): 301–16
- Burkill GJ, Badran M, Al-Muderis O, Meirion Thomas J, Judson IR, Fisher C, Moskovic EC (2003). "Malignant gastrointestinal stromal tumor: distribution, imaging features, and pattern of metastatic spread". *Radiology* 226 (2): 527–32
- Carney JA (1999). Gastric stromal sarcoma, pulmonary chondroma, and extra-adrenal paraganglioma (Carney Triad): natural history, adrenocortical component, and possible familial occurrence. *Mayo Clin Proc*. Jun. 74(6):543-52.
- Casali PG, Blay JY (2010). On behalf of the ESMO/CONTICANET/EUROBONET "Gastrointestinal stromal tumours: ESMO Clinical Practice Guidelines for diagnosis, treatment and follow-up". *Annals of Oncology* 21 (suppl 5): v98–v102.
- Cheung MC, Zhuge Y, Yang R, Koniaris LG (2009). Disappearance of racial disparities in gastrointestinal stromal tumor outcomes. *J Am Coll Surg*. Jul. 209(1):7-16.
- Cohen MH, Johnson JR, Justice R, Pazdur R (2012). "Approval summary: imatinib mesylate for one or three years in the adjuvant

- treatment of gastrointestinal stromal tumors. U.S. Food and Drug Administration, Silver Spring, MD 20993-0002, USA". *Oncologist* 17 (7): 992–997. doi:10.1634/theoncologist.2012-0109.
- Conlon K, Osborne J, Morimoto C, Ortaldo JR, Young HA (1995). Comparison of lymphokine secretion and mRNA expression in the CD45RA+ and CD45RO+ subsets of human peripheral blood CD4+ and CD8+ lymphocytes. *Eur J Immunol.* 1995 Mar;25(3):644-8.
- Crosby JA1, Catton CN, Davis A, Couture J, O'Sullivan B, Kandel R, Swallow CJ (2001). Malignant gastrointestinal stromal tumors of the small intestine: a review of 50 cases from a prospective database. *Ann Surg Oncol.* Jan-Feb. 8(1):50-9.
- Dematteo RP, Heinrich MC, El-Rifai WM, Demetri G (2002). Clinical management of gastrointestinal. stromal tumors: before and after STI-571. *Hum Pathol.* May. 33(5):466-77.
- DeMatteo RP, Lewis JJ, Leung D, Mudan SS, Woodruff JM, Brennan MF. (2000). Two hundred gastrointestinalstromal tumors: recurrence patterns and prognostic factors for survival. *Ann Surg.* 2000Jan;231(1):51-8.
- Demetri G, DeVita L, Lawrence TS, Rosenberg SA (2011). "Chapter 87". *DeVita, Hellman, and Rosenberg's Cancer: Principles and Practice of Oncology (9th ed.)*.
- Dougherty PM, Willis WD (1991a). Modification of the responses of primate spinothalamic neurons to mechanical stimulation by excitatory amino acids and an N-methyl-D-aspartate antagonist. *Brain Res.* 542, 15-22
- Genetic Engineering and Biotechnology News (2008). "News: Genetic Variations in GI Tumors Determine Which Medications Are Efficacious." 13 Nov.
- Ghanem N, Althoefer C, Furtwangler A, Winterer J, Schäfer O, Springer O (2003). Computed tomography in gastrointestinal stromal tumors. *Eur Radiol.* Jul. 13(7):1669-78
- Hersh MR, Choi J, Garrett C, Clark R (2005). "Imaging Gastrointestinal Stromal Tumors". *Cancer Control* 12 (2): 111–115..
- JNishida T, Hirota S (2000). "Biological and clinical review of stromal tumors in the gastrointestinal tract". *Histol Histopathol* 15 (4): 1293–301.
- Joensuu H (2012). Adjuvant therapy for high-risk gastrointestinal stromal tumour: considerations for optimal management. *Drugs.* Oct 22;72(15):1953-63.
- Joensuu H (2012). Adjuvant treatment of GIST: patient selection and treatment strategies. *Nat Rev Clin Oncol.* 2012 Apr 24;9(6):351-8. doi: 10.1038/nrclinonc.7479
- Joensuu H, Eriksson M, Sundby Hall K, Hartmann JT, Pink D, Schutte J (2012). One vs three years of adjuvant imatinib for operable gastrointestinal stromal tumor: a randomized trial. *JAMA.* Mar 28. 307(12):1265-72.
- Kantarjian HM, Wolff RA, Koller CA (2011). *The MD Anderson Manual of Medical Oncology* (2nd ed.). McGraw-Hill.
- Kelly L, Bryan K, Kim SY, Janeway KA, Killian JK, Schildhaus HU, Miettinen M, Helman L, Meltzer PS, van de Rijn M, Debiec-Rychter M, O'Sullivan M (2013). "Post-Transcriptional Dysregulation by miRNAs Is Implicated in the Pathogenesis of Gastrointestinal Stromal Tumor [GIST]". *PLoS ONE* 8 (5): e64102
- Lee, Chung-Ho; Hyun, Myung-Han; Kwon, Ye-Ji; Cho, Sung-Il; Park, Sung-Soo (2012). "Deciding Laparoscopic Approaches for Wedge Resection in Gastric Submucosal Tumors: A Suggestive Flow Chart Using Three Major Determinants". *Journal of the American College of Surgeons* 215: 831–840.
- Lehnert T (1998). "Gastrointestinal sarcoma (GIST)--a review of surgical management". *Ann Chir Gynaecol* 87 (4): 297–305
- Levine MS, Buck JL, Pantongrag-Brown L, Buetow PC, Hallman JR, Sobin LH (1996). "Leiomyosarcoma of the esophagus: radiographic findings in 10 patients". *AJR Am J Roentgenol* 167 (1): 27–32.
- Miettinen M, Lasota J (2001). "Gastrointestinal stromal tumors--definition, clinical, histological, immunohistochemical, and molecular genetic features and differential diagnosis". *Virchows Arch* 438 (1): 1–12.
- Miettinen M, Lasota J (2006). "Gastrointestinal stromal tumors: review on morphology, molecular pathology, prognosis, and differential diagnosis". *Arch Pathol Lab Med* 130 (10): 1466–78
- Miettinen M, Makhlof H, Sobin LH, Lasota J (2006). Gastrointestinal stromal tumors of the jejunum and ileum: a clinicopathologic, immunohistochemical, and molecular genetic study of 906 cases before imatinib with long-term follow-up. *Am J Surg Pathol.* Apr. 30(4):477-89.
- Miettinen M, Sobin LH, Lasota J (2005). Gastrointestinal stromal tumors of the stomach: a clinicopathologic, immunohistochemical, and molecular genetic study of 1765 cases with long-term follow-up. *Am J Surg Pathol.* Jan. 29(1):52-68.
- National Comprehensive Cancer Network (2012). Clinical Practice Guidelines in Oncology Soft Tissue Sarcomas, version 3.
- National Comprehensive Cancer Network (2012). Clinical Practice Guidelines in Oncology Soft Tissue Sarcomas, version 3.
- Nguyen SQ, Divino CM, Wang JL, Dikman SH (May 2006). "Laparoscopic management of gastrointestinal stromal tumors". *Surg Endosc* 20 (5): 713–16.i
- Nilsson B, Bummig P, Meis-Kindblom JM, Oden A, Dortok A, Gustavsson B (2005). Gastrointestinal stromal tumors: the incidence, prevalence, clinical course, and prognostication in the preimatinib mesylate era--a population-based study in western Sweden. *Cancer.* Feb 15. 103(4):821-9
- Okuno S (2011). "The Use of Tyrosine Kinase Inhibitors for Gastrointestinal Stromal Tumors (GIST)". *Contemporary Oncology.*
- Patel Shreyaskumar R, Wong P (2009). "http://www.touchoncology.com/articles/efficacy-imatinib-unresectablemetastatic-gastrointestinal-stromal-tumors". *US Oncology* 5 (1): 61–4.
- Pazdur R (2007). Provide research topic. FDA Approval for Regorafenib. National Cancer Institute
- Pidhorecky I, Cheney RT, Kraybill WG, Gibbs JF (2000). "Gastrointestinal stromal tumors: current diagnosis, biologic behavior, and management". *Ann Surg Oncol* 7 (9): 705–12.
- Reichardt P, Blay JY, Boukovinas I, Brodowicz T, Broto JM, Casali PG, Decatris M, Eriksson M, Gelderblom H, Kosmidis P, Le Cesne A, Pousa AL, Schlemmer M, Verweij J, Joensuu H (2012). "Adjuvant therapy in primary GIST: state-of-the-art". *Annals of Oncology* 23 (11): 2776–2781
- Shojaku H, Futatsuya R, Seto H, Tajika S, Matsunou H (1997). "Malignant gastrointestinal stromal tumor of the small intestine: radiologic-pathologic correlation". *Radiat Med* 15 (3): 189–92.
- Shojaku H, Futatsuya R, Seto H, Tajika S, Matsunou H (1997). Malignant gastrointestinal stromal tumor of the small intestine: radiologic-pathologic correlation. *Radiat Med.* May-Jun. 15(3):189-92
- Tateishi U, Hasegawa T, Satake M, Moriyama N (2003). Gastrointestinal stromal tumor. Correlation of computed tomography findings with tumor grade and mortality. *J Comput Assist Tomogr.* Sep-Oct. 27(5):792-8.[Medline].
- Tervahartala P, Halavaara J (1998). "Radiology of GIST. Gastrointestinal stromal tumours". *Ann Chir Gynaecol* 87 (4): 291–2
- Tran T, Davila JA, El-Serag HB (2005). The epidemiology of malignant gastrointestinal stromal tumors: an analysis of 1,458 cases from 1992 to 2000. *Am J Gastroenterol.* Jan. 100(1):162-8
- Ulusan S, Koc Z, Kayaselcuk F (2008). "Gastrointestinal stromal tumours: CT findings". *Br J Radiol* 81 (968): 618–623.
- Zhao X, Yue C (2012). Gastrointestinal stromal tumor. *J Gastrointest Oncol.* Sep. 3(3):189-208
- Zhou HY, Zhang XM, Zeng NL, Jian SH, Tang W (2012). Use of conventional MR imaging and diffusion-weighted imaging for evaluating the risk grade of gastrointestinal stromal tumors. *J Magn Reson Imaging.* Dec. 36(6):1395-401

How to cite this article: BENDJABALAH A, TAIEB M, NAIT SLIMANE N, RABEHI H, AMMARI S, KHALI R (2016). Upper GIT Bleeding Due to Gastric Stromal Tumor. *Int. Inv. J. Med. Med. Sci.* Vol. 3(1): 14-20