International Invention Journal of Medicine and Medical Sciences (ISSN: 2408-7246) Vol. 2(5) pp. 62-65, May, 2015
Available online http://internationalinventjournals.org/journals/IIJMMS
Copyright ©2015 International Invention Journals

Case Report

Esophageal perforation with fish bone: A case report

Pezhman Alavinejad[1, 2*], Bijan Ahmadi[2], Kambiz Akhavan rezayat[3], Amir houshang bavarsad[4]

[1-]Research institute for infectious diseases of digestive system, School of Medicine, Ahvaz Jundishapur University of Medical Sciences, Ahvaz, Iran
[2-]Assistant professor of gastroenterology, Division of Gastroenterology and Hepatology, Department of Internal Medicine, Ahvaz Jundishapur University of Medical Sciences, Ahvaz, Iran
[3-]Assistant professor of gastroenterology, Division of Gastroenterology and Hepatology, Department of Internal Medicine, Mashhad University of Medical Sciences, Mashhad, Iran
[4-]Resident of internal medicine, Department of Internal Medicine, Ahvaz Jundishapur University of Medical Sciences, Ahvaz, Iran

Abstract

This is a 43 year old man with complain of massive hematemesis. The upper endoscopy identified esophageal penetration by fish bone at mid esophagus and the CT scan also showed a hematoma at mid esophagus. The endoscopy procedure terminated immediately and surgical consultation requested. While the patient was waiting for transfer to operating room, a catastrophic bleeding happens and the patient died.

Keywords: Hematemesis, Upper Endoscopy, Esophageal Perforation.

INTRODUCTION

A 43 year old man has been admitted in the emergency department with complain of hematemesis and rectorrhagia (16:30 PM). He reported 3 times of hematemesis in the morning of same day and the volume of vomited blood was about 4 glasses. He also complained of passing blood per stool. There was no abdominal or epigastric pain. He mentioned consumption of sea food three days ago and was doubtful about swallowing of fish bone.

His vital sign was stable (SBP 140/90, recumbent PR 82, sitting PR 100, RR 15, and T 37.9) and there was not any history of drug or NSAID use. He was a smoker and also recreational opium user. In physical examination, the conjunctiva was pale but sclera was not icteric. There was not any other positive finding and rest of examination was normal.

The laboratory profile include the following results: Hb 7.9, MCV 62, Plt 405000, MCH 19, MCHC 30, PT 15, PTT 30, INR 1, BS 194, BUN 23, Cr 0.9, AST 61, ALT 52 and Alk P 572. After admission, hemodynamic resuscitation achieved with N/S, IV Pantoprazol infusion and transfusion of 2 units PC. An urgent upper endoscopy was requested and the endoscopist reported that there was a large hematoma with a foreign body in the mid esophagus and also there were 2 to 3 small clean based ulcers in duodenal bulb (figure 1). The endoscopy terminated immediately without any intervention and chest CT scan (figure 2) and surgical consultation requested.

On call of surgery have visited him and ordered for transfusion of packed cell, FFP,CT scan and also request to inform him emergently in case of any active bleeding or any change in clinical situation. The CT images showed a large hematoma at mid esophagus beside aortic arch (figure 2). While the patient was waiting to be refer to operation room, a massive GI bleeding took place at early morning which ends to blood pressure drop, decrease in Level of Consciousness (LOC), shock and cardiac arrest. Resuscitation and CPR began but they were unsuccessful and the patient expired at 3.20AM.

* Corresponding Author Email: pezhmanalavinejad@gmail.com; palavinezhad@yahoo.com

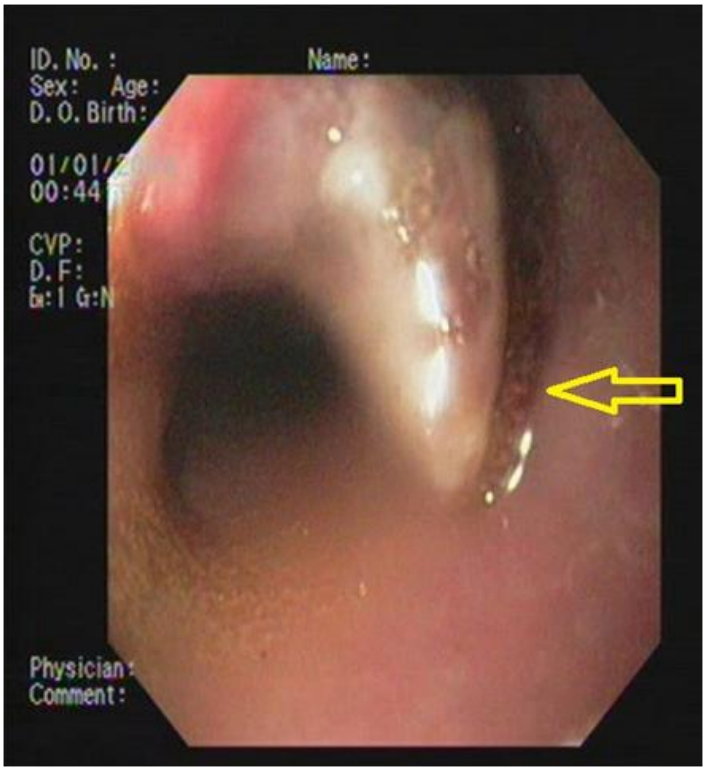

Figure 1. Fish bone in mid esophagus.

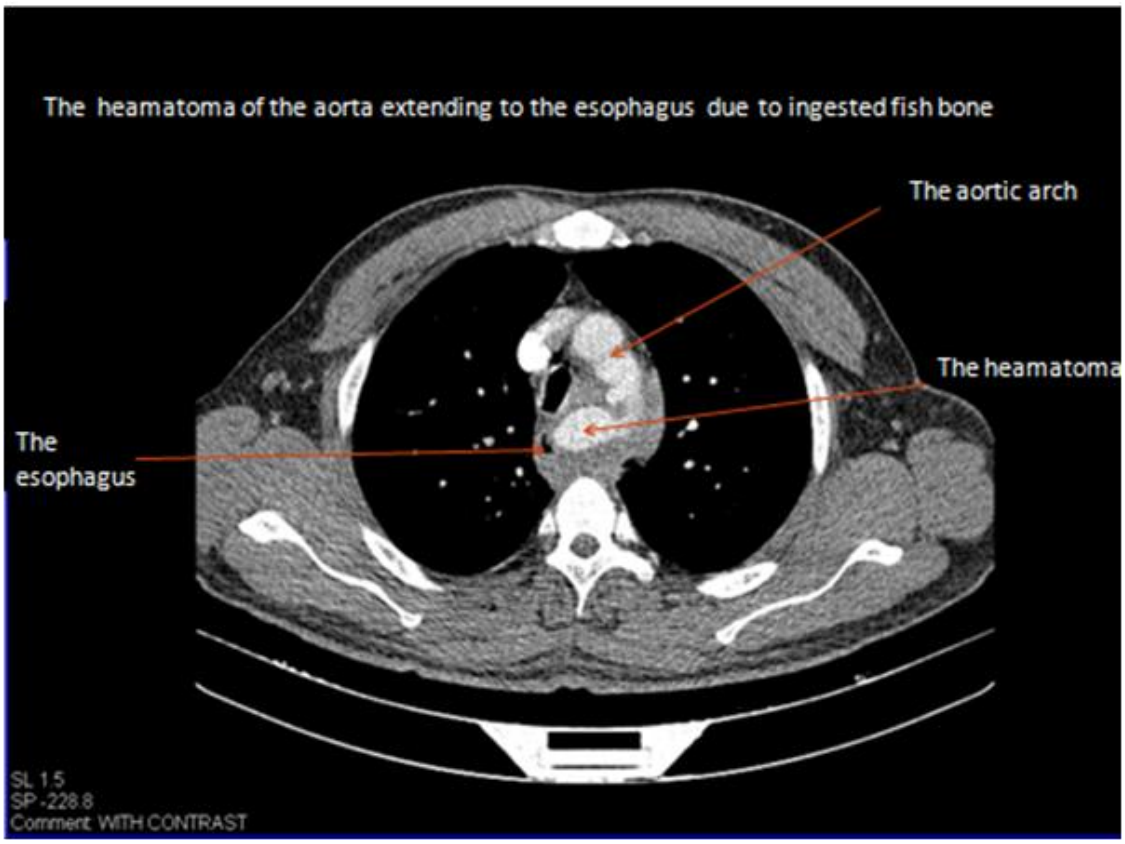

Figure 2. Chest CT scan revealed esophageal hematoma.

DISCUSSION

Esophagus is a muscular tubular structure between oral cavity and stomach to achieve a safe transfer of food and liquids. Structurally the esophageal wall composed of 4 layers: innermost mucosa, submucosa, muscularispropria, and outermost adventitia (Braden and Daniela, 2006; Feldman et al., 2010) and unlike other parts of GI tract, the esophagus has no serosa which makes it prone to perforation (Feldman et al., 2010; Katsetos et al., 2003). In fact the esophagus is the most common site of foreign body impaction in the gastrointestinal (GI) tract (Webb, 1995).

There are areas of anatomical esophageal narrowing, including the cervical esophagus, aorticarch, and gastro esophageal junction which is more prone for foreign body impaction (Eisen et al., 2002). However, adults with food impaction often have an underlying structural esophageal disorder such as a peptic stricture or eosinophilic esophagitis (Panieri and Bass, 1995; Desai et al., 2005).

The clinical presentation of esophageal foreign body impaction is often straightforward and depends upon the size and location of the injury and also time course since injury (Katsetos et al., 2003, Webb, 1995). Dysphagia is the most common symptom and, if the esophagus is obstructed, odynophagia, choking, or drooling could be present (Ginsberg, 1995). Complications usually depend on the characteristics of the impacted object, and may occur with larger sized, irregularly shaped, or sharply pointed objects including fish bones (Katsetos et al., 2003, Eisen et al., 2002).

Our patient was presented with massive hematemesis and the foreign body identified by endoscopy was about mid esophagus which is near to the aortic arch (figure 1). Fistulization to surrounding vasculature such as the aorta or innominate artery may lead to life-threatening hemorrhage (Wu and Lai, 1992; Simic and Budakov, 1998). Equally serious consequences can also occur with fistulization to the airway or pericardium (Rajesh and Goiti, 1993). In these cases, temporary bleeding from the respiratory or digestive tracts is an important signal and could be an alarming sign which can end to a catastrophic and fatal scenario.

The diagnosis of esophageal perforation most often relies on radiologic findings. Once suspected, a posteroanterior and lateral upright chest X-ray should be obtained to identify any cervical or mediastinal emphysema, pneumopericardium or pleural effusion (Katsetos et al., 2003). Contrast films obtained with meglumine diatrizoate (Gastrograffin) are used to confirm the presence of an esophageal perforation. If the gastrograffin study was negative, a barium study may be required (Phillips and Cunningham, 1984). If a thoracoesophageal fistula or free perforation into the lung is suspected, barium should not be used due to the possible risk of barium - induced mediastinal inflammation. In case of negative X-ray, the next step which should be considered is chest CT scan (Dodds et al., 1982). The CT scan is useful in localizing fluid collections (White et al., 1993) and in our patient, the CT scan showed a hematoma around esophagus which was suggestive of aortic penetration (figure 2).

Although conservative management of perforations such as endoscopic closure could be successful, it is only appropriate in contained esophageal perforations in a stable patient without evidence of sepsis (Wewalka et al., 1995; Nozoe et al., 1998). But our patient was presented with massive hematemesis and CT findings was suggestive of aortic penetration and in these cases any endoscopic intervention could potentially lead to abrupt fatal bleeding so the endoscopy terminated immediately without any intervention.

These kinds of esophageal perforation require urgent operative attention. Indications of surgery include clinically unstable patient, signs of sepsis, contamination of mediastinum or plural space and failed medical therapy (Reeder et al., 1995). The overall mortality rate of esophageal perforation is 22% but the survival rose to near 95% when the primary repair is completed within 24 hours of rupture (Duranceau, 1997). Sudden hemodynamic deterioration due to massive bleeding prevented any surgical intervention for our patient and he died before arriving to the operation room.

CONCLUSION

Etiology, time delay between esophageal perforation and diagnosis, and location of esophageal perforation affect management and results. The majority of esophageal perforations require urgent surgical treatment and in these situations every minute is critical and saving every second could be vital.

REFERENCES

Braden K, Daniela U (2006). Esophagus - anatomy and development. GI Motility online. doi: 10.1038/gimo6.

Desai TK, Stecevic V, Chang CH, Goldstein NS, Badizadegan K, Furuta GT. (2005). Association of eosinophilic inflammation with esophageal food impaction in adults.GastrointestEndosc; 61:795.

Dodds WJ, Stewart ET, Vlymen WJ (1982). Appropriate contrast media for evaluation of esophageal disruption. Radiology; 144: 439-441.

Duranceau A (1997). Perforation of the esophagus, in Sabiston DC Jr, Lyerly HK (eds): Textbook of Surgery: The Biological Basis of Modern Surgical Practice. Philadelphia, W.B. Saunders Co., ed 15, p 267.

Eisen GM, Baron TH, Dominitz JA, Faigel DO, Goldstein JL, Johanson JF, Mallery JS, Raddawi HM, Vargo JJ 2nd, Waring JP, Fanelli RD, Wheeler-Harbough J (2002). Guideline for the management of ingested foreign bodies. GastrointestEndosc; 55:802.

Ginsberg GG (1995). Management of ingested foreign objects and foodbolus impactions. GastrointestEndosc 1995; 41:33.

Katsetos MC, Tagbo AC, Lindberg MP, Rosson RS (2003). Esophageal Perforation and Mediastinitis from Fish Bone Ingestion. South Med J; 96(5).

Feldman M, Lawrence SF, Brandt LJ (2010). Sleisenger and Fordtran's

gastrointestinal and liver disease: pathophysiology, diagnosis, management, expert consult premium edition-enhanced online features. Vol. 1. Elsevier Health Sciences, 2010. Chap: 25, 41-45.

Nozoe T, Kitamura M, Adachi Y, Funahashi S, Yoh R, Iso Y, Matsumata T, Sugimachi K. (1998). Successful conservative treatment for esophageal perforation by a fish bone associated with mediastinitis. Hepatogastroenterology; 45: 2190-2192.

Panieri E, Bass DH (1995). The management of ingested foreign bodies in children – a review of 663 cases. Eur J Emerg Med 1995; 2:83.

Phillips LG Jr, Cunningham J (1984). Esophageal perforation. RadiolClin North Am; 22: 607-613.

Rajesh PB, Goiti JJ (1993). Late onset tracheo-oesophageal fistula followinga swallowed dental plate. Eur J CardiothoracSurg 1993; 7:661.

Reeder LB, DeFilippi VJ, Ferguson MK (1995). Current results of therapy for esophageal perforation. Am J Surg; 169: 615-617.

Simic MA, Budakov BM (1998). Fatal upper esophageal hemorrhage caused by a previously ingested chicken bone: case report. Am J Forensic Med Pathol 1998; 19:166.

Webb WA (1995). Management of foreign bodies of the upper gastrointestinal tract: update. Gastro intestEndosc 1995; 41:39.

Wewalka FW, Clodi PH, Haidinger D (1995). Endoscopic clipping of esophageal perforation after pneumatic dilation for achalasia. Endoscopy; 27: 608-611.

White CS, Templeton PA, Attar S (1993). Esophageal perforation: CT findings. AJR Am J Roentgenol; 160: 767-770.

Wu MH, Lai WW (1992). Aortoesophageal fistula induced by foreign bodies. Ann Thorac Surg; 54:155.

How to cite this article: Alavinejad P, Ahmadi B, Rezayat KA, Bavarsad AH (2015). Esophageal perforation with fish bone: A case report. Int. Inv. J. Med. Med. Sci. Vol. 2(5): 62-65