

Unilateral Benign Masseteric Hypertrophy: Surgical Intervention and Case Report

Shipra Singh¹, Anurag Saxena², Saumya Tripathi³, Prashant Singh⁴, Harmurti Singh²,
Amiya Agrawal²

¹Department of Dentistry, Motilal Nehru Medical College, Allahabad, ²Department of Oral and Maxillofacial Surgery, Career Post-graduate Institute of Dental Sciences, Lucknow, Uttar Pradesh, India, ³Consultant, FCLPS Reconstructive Surgeon Meenakshi Mission Hospital and Research Centre, Madurai, Tamil Nadu, India, ⁴Private Practitioner, Department of Oral and Maxillofacial Surgery, Majhgawan, Bareilly, Uttar Pradesh, India

ABSTRACT

Hypertrophy is related to an enlargement caused by a growth in the size but not in the number of cells. Generalized masticatory muscle hypertrophy may affect the temporalis muscle, masseters, and medial pterygoids in a variety of combinations. Masseter hypertrophy is recognized as a rare disorder and persistent asymptomatic enlargement of one or both masseter muscles. Etiology for benign masseteric hypertrophy is unknown in most of the cases so considered as idiopathic. Although numerous factors such as facial asymmetry, trismus, protrusion, bruxism, clenching, malocclusion, or temporomandibular disorders have been reported on the basis of clinical examination and cited previous literatures but have not proven still. This article reports a case of unilateral benign masseter hypertrophy with retrognathic mandible in which surgical intervention was rendered to the patient by using a combination approach.

Key words: Idiopathic, masseteric hypertrophy, masseter muscle, orthognathic surgery

INTRODUCTION

The masseter muscle is thick quadrangle essential muscle for mastication which arises from the zygomatic arch and inserts into the inferior lateral aspect and angle area of the mandibular ramus and is located laterally to the mandibular ramus, and thus plays an important role in facial aesthetics. A hypertrophied masseter will alter facial lines, generating discomfort, and negative cosmetic impacts for many patients.

May be either:

- Congenital
- Functional (acquired).

Hypertrophy may be either:

- Unilateral
- Bilateral.

Responsible features for masseteric hypertrophy:

- Increased muscle function
- Bruxism
- Habitual overuse of masseter during mastication
- Anabolic steroids.

Differential diagnosis:

- Sjogren's syndrome
- Mikulicz's syndrome
- Heerfordt's syndrome
- Cellulitis

Access this article online

Publisher	
	Website: www.renupublishers.com
	DOI: 10.5958/2394-4196.2015.00027.8

Address for Correspondence:

Dr. Anurag Saxena, K-2 Vanasthali Apartment, Sector-1 Gomti Nagar Extension, Lucknow - 226 010, Uttar Pradesh, India.
E-mail: dentist.anurag@gmail.com

Submission: 14 Oct 2015; **Revision:** 10 Nov 2015; **Acceptance:** 04 Dec 2015

- Facial hemihypertrophy
- Neoplasms
- Parotiditis or parotid tumor
- Lipoma.

Idiopathic masseter muscle hypertrophy (IMMH) was first described by Legg in 1880 reporting on the case of a 10-year-old girl with concurrent idiopathic temporalis MH.^[1,2]

In older age groups with dental deterioration, there is an inability to fully activate the masseters and any pre-existing MH tends to recede. Anatomically, most of the masseteric thickness is along the inferior portion of the mandibular ramus, where the facial contour normally tapers. With MH, the patient's face takes on a characteristic rectangular configuration.^[3,4]

The highest incidence for MH is in between second (20 s) and third decades (40 s) of life, with no gender predilection.^[3] A congenital variety also exists, but acquired masseter hypertrophy is more common. The unilateral occurrence can be seen when patients chew or clench primarily on one side. Muscle function may also be impaired, thus causing conditions such as trismus, protrusion, and bruxism. Numerous factors, such as malocclusion, bruxism, clenching, or temporomandibular joint disorders, have been cited. The accurate diagnosis is more difficult in unilateral cases. A hypertrophied masseter will alter facial lines, cause generating discomfort, and negative cosmetic impacts in many patients. Masseter hypertrophy leads to the prominent mandibular angle which is aesthetically unacceptable to the patient. The differential diagnosis includes parotid tumor, lipoma, benign or malignant muscle tumors, and vascular tumors.^[5]

Several treatment options reported for masseter hypertrophy are present, which range from simple pharmacotherapy to more invasive surgical reduction. Keloid scar with unilateral masseter hypertrophy is a rarely seen in clinical practice. To date, the major treatment methods involve surgery, including mandibular angle osteotomy and masseter muscle resection, and there are non-surgical methods, including injection with botulinum toxin (botox) Type A.^[1,2] Park *et al.* 2007 reported on radiofrequency (RF) volumetric reduction for masseteric hypertrophy.^[6] RF-induced tissue coagulation necrosis of the masseter muscle did not lead to any infections or limitations with regard to mouth opening, and the clinical improvement was well-maintained following treatment.^[3] However, thus far, there have been no studies on the efficacy and safety of RF and injection with botox.

This paper reports a case of unilateral masseter hypertrophy with keloid scar in the angle of the mandible for which surgical treatment was rendered to the patient by using a single approach.^[5]

CASE REPORT

A 28-year-old male patient was referred from a private dental clinic complaining of swelling and asymmetry of the face in the mandibular angle region on the left side since 3 years. The patient's chief complaint was the left side facial growth without pain.

The patient had no history of systemic diseases with any history of xerostomia, xerophthalmia, or other symptoms such as fever, etc. Extraoral examination showed an obvious unilateral swelling centered over the mandibular angle. Palpation indicated that the swollen tissue was normal in tone and non-tender. Mandibular movements were in the normal range. When the patient was asked to clench, the swelling became more prominent and firm.

The patient said that he uses the left side of the jaw more while chewing food and skin over the mucosa was normal. There was no history of temporomandibular joint clicking and no family history of masseter hypertrophy. The initial provisional diagnosis was salivary gland disorder, or jaw bone, or muscle disorder on the basis of patient's chief complaints. On physical examination revealed that the patient had unilateral masseter muscle bulging, with a prominent mandibular angle at the lower border. Orthopantomography showed a prominent mandibular angle. Data from clinical and radiographic examination led to the diagnosis of unilateral masseter MH. Non-surgical options such as botox therapy and the advantages and disadvantages of both surgery and botox treatment were discussed with the patient. The patient opted for surgical option as he wanted to get rid of the scar immediately.

A combined reduction of the mandibular angle and shaving of the masseter muscle was planned. The surgery was done under general anesthesia with nasotracheal intubation. Xylocaine 2% with adrenaline was infiltrated in the angle of the mandible. An intra-oral approach incision of approximately 5 cm was given for surgical recontouring of the mandibular angles with an oscillatory saw [Figure 1] was made with proper isolation the mandibular marginal nerve and the facial vessels.

The muscle was incised approximately 5 mm [Figure 2] above the mandibular basilar. The entire ascending branch of the masseter was detached, and a vertical internal muscle band equivalent to 2/3 of the thickness of the muscle was resected. After the muscle was resected, the remaining external third was sutured to its site of origin to the muscle stump inserted in the mandibular basilar. Mandibular movements were checked, and closure was done with 3-0 mersilk suture.

The bed was drained at the end of the procedure, and a compressive dressing was put in place. The drain was removed 24 h after the surgery. Physical therapy was offered between

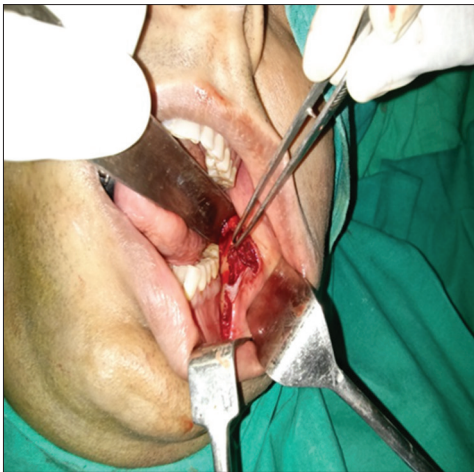

Figure 1: Intra oral incision

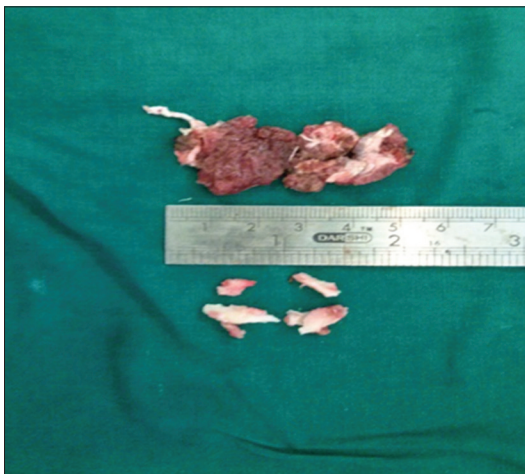


Figure 2: Incised muscle

the 10th and 14th day post-operatively with regular follow-up for next 6 months. The healing went uneventful and at 1-month post-operative patient was satisfied with the outcome.

DISCUSSION

Hypertrophy of the masticatory muscles is characterized by generalized enlargement of the muscular tissue that affects the facial esthetic and may or not be accompanied by pain.^[5] This condition can be congenital, but more often it is acquired. The origin has been attributed to muscle hyperactivity, and para functions originated from a stressful lifestyle that causes bruxing or clenching.^[5]

Masseteric MH is a relative common clinical entity that can affect one or both sides and is also thought to cause secondary enlargement of the mandibular angle as a result of functional remodeling. Temporalis MH is a rare clinical entity, and only a few cases are reported. More often, it presents a bilateral involvement and is usually associated with masseteric hypertrophy.^[5]

Muscular hypertrophy is thought to cause secondary bony enlargement of the mandibular angle from functional remodelling where the muscle inserts on bone.^[1,2] Thus, the natural history of this condition suggests that patients with muscular hypertrophy alone may eventually progress to bony prominence. The accurate diagnosis is more difficult in unilateral cases. A hypertrophied masseter will alter facial lines, cause generating discomfort, and negative cosmetic impacts in many patients. Masseter hypertrophy leads to the prominent mandibular angle which is aesthetically unacceptable to the patient.

Diagnosis of masseter hypertrophy can be achieved from clinical examination, history, panoramic X-ray, and muscle palpation. The best diagnostic test is to palpate the masseter muscle with fingers while the patient clenches his/her teeth, so the muscle is more prominent during contraction. With the muscle is relaxed and the patient's mouth is slightly open, extraoral palpation with both hands will pinpoint the intramuscular location of the hypertrophy. Upon relaxation, the jaw angle may reveal irregularities that on the X-ray image may appear to be a bone increase.

According to Teixeira *et al.*,^[7] there are two types of masseter MH: Congenital or familial and acquired due to the functional hypertrophy. There are various treatment modalities for the management of masseter hypertrophy. This can be categorized into non-surgical and surgical. The management of the idiopathic masseter hypertrophy is based on psychological counseling, use of mouth guards, - muscle relaxant, and anxiolytic drugs, analgesics, physical therapy, dental restorations, and occlusal adjustments to correct premature contacts.^[8-10] A good result can be achieved in the patients with mild hypertrophy, but there is no reliable report on the literature on the success rates of isolated clinical therapy. Injection of botox Type A into the masseter muscle is generally considered a less invasive modality and has been advocated for cosmetic sculpting of the lower face. Injection of botox Type A into the masseter muscle was first introduced by Smyth,^[8] Moore, and Wood in 1994^[11] and considered a less invasive modality for the treatment of MH.

Surgical treatment for masseteric hypertrophy was first proposed by gurney in 1947.^[1] The procedure was consists of a submandibular incision and the removal of 3/4-2/3 of all muscle tissue available from the muscle upper aponeurosis to the lower mandibular border.^[1] Excision of the internal layer of the masseter muscle and reduction of the thickened bone in the region of the mandibular angle via intra-oral approach is the treatment of choice. Complication from surgical incision of masseter muscle includes hematoma, facial nerve paralysis, infection, trismus, and sequelae from general anesthesia.

Bloem and Hoof stated that approximately 20% of normal people have this finding and that it cannot be considered as

diagnostic aid.^[12-14] Guggenheim and Cohen reported that bone spurs are caused by periosteal irritation and new bone deposition responding to increased forces exerted by the muscles bundles.^[15-17] IMMh must be accurately diagnosed, as it may be mistaken for other diseases. Among them are unilateral compensatory hypertrophy (due to hypotrophy or hypoplasia in the contralateral side), masseter tumor, salivary gland disease, parotid tumor, parotid inflammatory disease, and masseter muscle intrinsic myopathy.^[2,7]

CONCLUSION

Therapy for masseteric enlargement is usually unnecessary in cases diagnosed for surgical intervention while, non-surgical modality of treatment include reassurance tranquilizer or muscle relaxant, psychiatric care, and injection of very small dose of botox Type A.

REFERENCES

- Rispoli DZ, Camargo PM, Pires JL Jr, Fonseca VR, Mandelli KK, Pereira MA. Benign masseter muscle hypertrophy. *Braz J Otorhinolaryngol* 2008;74:790-3.
- Al-Ahmad HT, Al-Qudah MA. The treatment of masseter hypertrophy with botulinum toxin type A. *Saudi Med J* 2006;27:397-400.
- Waldhart E, Lynch JB. Benign hypertrophy of the masseter muscles and mandibular angles. *Arch Surg* 1971;102:115-8.
- Yu CC, Chen PK, Chen YR. Botulinum toxin A for lower facial contouring: A prospective study. *Aesthetic Plast Surg* 2007;31:445-51.
- Parente E, Silveiras M, Naegle M, Ribeiro D, Andrade M. Surgical treatment of bilateral temporalis and masseteric hypertrophy: Report of a case. *Open J Stomatol* 2013;3:99-102.
- Jin Park Y, Woo Jo Y, Bang SI, Kim HJ, Lim SY, Mun GH, *et al.* Radiofrequency volumetric reduction for masseteric hypertrophy. *Aesthetic Plast Surg* 2007;31:42-52.
- Teixeira VC, Mejia JE, Estefano A. Surgical treatment of benign masseter by intraoral approach. *Rev Bras Surgery* 1996;86: 165-70.
- Smyth AG. Botulinum toxin treatment of bilateral masseteric hypertrophy. *Br J Oral Maxillofac Surg* 1994;32:29-33.
- Özkan BT, Tabrizi R, Cigerim L. Management of bilateral masseter muscle hypertrophy. *J Craniofac Surg* 2012;23:e14-6.
- Andrade NN, Deshpande GS. Use of botulinum toxin (botox) in the management of masseter muscle hypertrophy: A simplified technique. *Plast Reconstr Surg* 2011;128:24e-6e.
- Moore AP, Wood GD. The medical management of masseteric hypertrophy with botulinum toxin type A. *Br J Oral Maxillofac Surg* 1994;32:26-8.
- Sannomya EK, Gonçalves M, Cavalcanti MP. Masseter muscle hypertrophy: Case report. *Braz Dent J* 2006;17:347-50.
- Klein FH, Brenner FM, Sato MS, Robert FM, Helmer KA. Lower facial remodeling with botulinum toxin type A for the treatment of masseter hypertrophy. *An Bras Dermatol.* 2014;89:878-84.
- Andreadis D, Stylianou F, Tsatsouli L, Markopoulos A. Bilateral masseter and internal pterygoid muscle hypertrophy: A diagnostic challenge. *Med Princ Pract* 2014;23:286-8.
- Huang JL, Chen G, Chen XD, Zhou BR, Luo D. A comparative study of the efficacy and safety of radiofrequency ablation and botulinum toxin A in treating masseteric hypertrophy. *Exp Ther Med* 2014;7:1203-1208.
- Kebede B, Megersa S. Idiopathic masseter muscle hypertrophy. *Ethiop J Health Sci* 2011;21:209-12.
- Kim JH, Shin JH, Kim ST, Kim CY. Effects of two different units of botulinum toxin type a evaluated by computed tomography and electromyographic measurements of human masseter muscle. *Plast Reconstr Surg* 2007;119:711-7.

How to cite this article: Singh S, Saxena A, Tripathi S, Singh P, Singh H, Agrawal A. Unilateral Benign Masseteric Hypertrophy: Surgical Intervention and Case Report. *Int J Dent Med Spec* 2015;2(4):28-31.

Source of Support: None; **Conflict of Interest:** None