

Sebaceous Gland Carcinoma of Upper Eyelid: Resection and Reconstruction using Eyelid Switch and Rotation Flap

Pai VD^{*1}, Babu B², Ravindranath S³ and Manohar V³

¹Department of Surgical Oncology, Kerudi Cancer Hospital and Research Centre, Bagalkot, Karnataka, India

²Department of Plastic Surgery, Kerudi Cancer Hospital and Research Centre, Bagalkot, Karnataka, India

³Department of Pathology, SRL Diagnostics, Bangalore, Karnataka, India

Corresponding author: Pai VD, MS, M Ch (Surgical Oncology), DNB (Surgical Oncology), EBSQ Department of Surgical Oncology, Kerudi Cancer Hospital and Research Centre, Bagalkot 587101, Karnataka, India, Tel: +91-9449333502; **E-mail:** vishpai88@gmail.com

Received date: 12 Dec 2015; **Accepted date:** 23 Dec 2015; **Published date:** 28 Dec 2015.

Citation: Pai VD, Babu B, Ravindranath S, Manohar V (2015) Sebaceous Gland Carcinoma of Upper Eyelid: Resection and Reconstruction using Eyelid Switch and Rotation Flap. *Int J Cancer Res Mol Mech* 1(4): doi <http://dx.doi.org/10.16966/2381-3318.119>

Copyright: © 2015 Pai VD, et al. This is an open-access article distributed under the terms of the Creative Commons Attribution License, which permits unrestricted use, distribution, and reproduction in any medium, provided the original author and source are credited.

Abstract

Sebaceous gland carcinomas are rare malignancies of the eyelid which offer significant challenge for the diagnosis and treatment. They are frequently misdiagnosed in view of their rarity as well as resemblance to common benign pathologies like chalazion. Surgical resection remains the mainstay of treatment. These are highly aggressive histologies with significant risk of local recurrence if not resected completely. Reconstruction of the eyelids needs to be meticulous as protection of the cornea is of paramount importance. Although use of free flaps is considered as a standard method of reconstruction, expertise and equipment required for the same are prohibitive for their adoption in majority of the centers. We are reporting a case of sebaceous gland carcinoma of the upper eyelid which was resected followed by reconstruction using lid switch of the lower eyelid and facial rotation flap as well as buccal mucosal graft.

Keywords: Sebaceous gland carcinoma; Eyelid tumors; Lid switch; Buccal mucosal graft

Introduction

Sebaceous gland carcinomas are rare malignancies of eyelid which are challenging to diagnose and treat [1]. Significant proportion of these tumors are misdiagnosed as they closely resemble benign pathologies such as chalazion [2]. Hence frequently they present in advanced stage with involvement of significant portion of the eyelid. Wide local excision remains the mainstay of treatment although radical radiotherapy may be used as a noninvasive treatment when surgery is not possible [3]. Surgical resection should be wide enough to ensure complete resection with adequate margins, at the same time not too wide to ensure a functional eyelid. Reconstruction is the most challenging part of the management because it is important to ensure a movable eyelid, good corneal protection and acceptable aesthesis. We are presenting a case of sebaceous gland carcinoma of the upper eyelid which was resected and resultant full thickness defect was reconstructed with lid switch along with the facial rotation flap.

Case Report

An 80 year old gentleman presented with an ulceroproliferative growth over right upper eyelid of 6 months duration (Figure 1A). For long, he was treated as chalazion by the local doctors before being referred to our centre. Biopsy of the growth revealed it as sebaceous gland carcinoma (Figure 1B). Metastatic work up revealed no evidence of regional or distant metastasis. Clinical stage of the tumour was T3a N0 M0 [Stage II] [4]. Tumor was resected with adequate margins all around (Figures 1C1 and 1C2). Tumor was 3 cm in diameter and closest margin was medial margin. The resultant defect was involving full thickness of lateral 2/3rd of the upper eyelid (Figure 1D). Lower eyelid was mobilized taking the entire thickness and about 50% of the length of the defect of the upper eyelid (Figure 2A). The defect in the palpebral conjunctiva over the lower portion of the sclera was reconstructed with buccal mucosal graft (Figure 2B). Lateral canthus was recreated with facial rotation flap (Figure 2C).

Figure 2D shows the final reconstruction. Intra and post operative course was uneventful and patient was discharged on post operative day 3. Three weeks after the primary surgery (Figure 2E), flap division was performed under local anesthesia (Figures 3A and 3B). Histopathological report confirmed the pathology as high grade sebaceous gland carcinoma with clear margins (Figures 3C and 3D). There was no pagetoid growth pattern and there was no perineural invasion. At 6 weeks follow up, patient was disease free with normal vision and no evidence of exposure keratitis.

Discussion

Sebaceous gland carcinoma is a high grade malignant neoplasm that arises from the sebaceous glands. It accounts for 0.2-4.7% of the malignant tumors of the eyelid [5]. However the incidence of sebaceous gland carcinoma is much higher in Asian population compared to the west [6,7]. It most commonly affects upper eyelid [8]. Diagnosis is frequently delayed not only because of its rarity but also because of the close resemblance with the more common benign pathologies such as chalazion, conjunctivitis and blepharitis. Surgical resection remains the gold standard treatment. Ideally, tumors have to be excised with a 3-4 mm margin as well as adequate depth in order to ensure long term recurrence free survival [9]. However, for tumors involving the conjunctiva, the safe margin is much smaller than that for tumors involving the skin [10]. Role of adjuvant radiotherapy has not been established although it is recommended for tumors with aggressive histologic subtype, perineural invasion, or nodal metastasis at presentation [11]. For patients who are unfit for surgery or when the tumor is unresectable because of involvement of vital structures, radical radiotherapy is a viable treatment option [3]. Prognosis is worse compared to other malignancies of the eyelid with mortality and morbidity only second to malignant melanoma [12].

In addition to protecting the eyeball, eyelids provide tear film continuity and lacrimal pump. Eyelid defects can lead to corneal irritation, exposure keratopathy and even loss of vision. Hence, the goals of eyelid

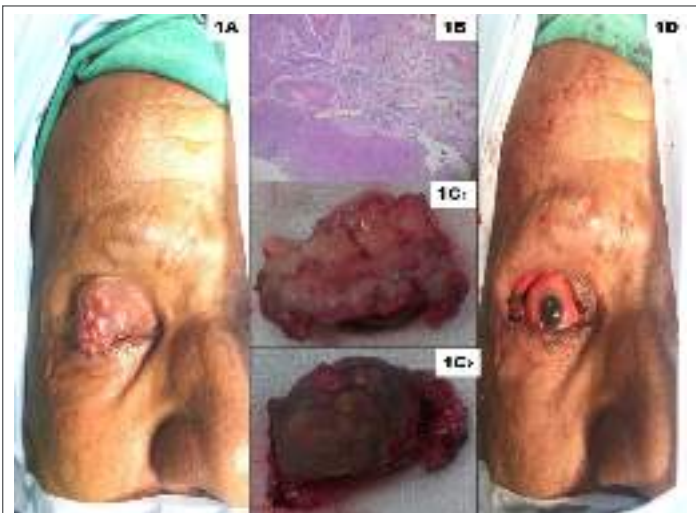

Figure 1: 1A-Patient profile showing tumor arising from the upper eyelid; 1B-Biopsy showing high grade sebaceous gland carcinoma; 1C1 and 1C2-Resected specimen showing the tumor; 1D-Defect in the eyelid after the resection of the tumor of the upper eyelid.

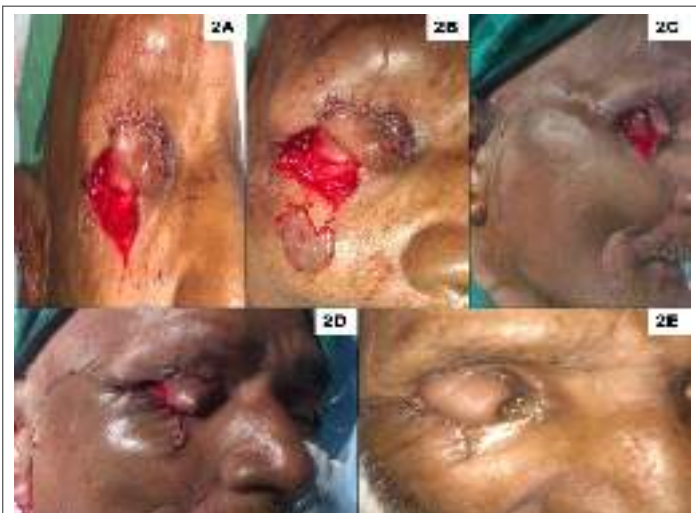

Figure 2: 2A-Defect in the upper eyelid reconstructed with the lower eyelid switch; 2B-Buccal mucosal graft harvested to cover the defect in the conjunctiva; 2C-Facial rotation flap planned; 2D-Completed reconstruction with lid switch and facial rotation flap; 2E-Patient profile 3 weeks after the primary surgery.

reconstruction are to ensure a movable eyelid and reproduce the texture of the eyelid. The reconstruction of the eyelid is complicated by the fact that it is composed of skin, mucosa, muscle tissue, and secretory glands unlike other body parts. In general, partial thickness defects which are limited to skin or conjunctiva can be reconstructed with skin grafts or local flaps. Full-thickness defects that involve less than 25% of the eyelid's width can be closed primarily whereas the wider defects need more meticulous reconstruction techniques [13]. Tissues similar to normal eyelid structure have to be used in these reconstructions which involves both anterior and posterior lamella. Improper reconstruction can result in significant long term complications.

Following techniques have been commonly used for the reconstruction of anterior lamella: Z-plasty, the V-Y glabellar flap, median forehead flap and the Cutler-Beard technique [14-16]. In addition, a number of pedicled as well as free flaps have been used. Following autogenous grafts have been used for reconstruction of the posterior lamella: labial

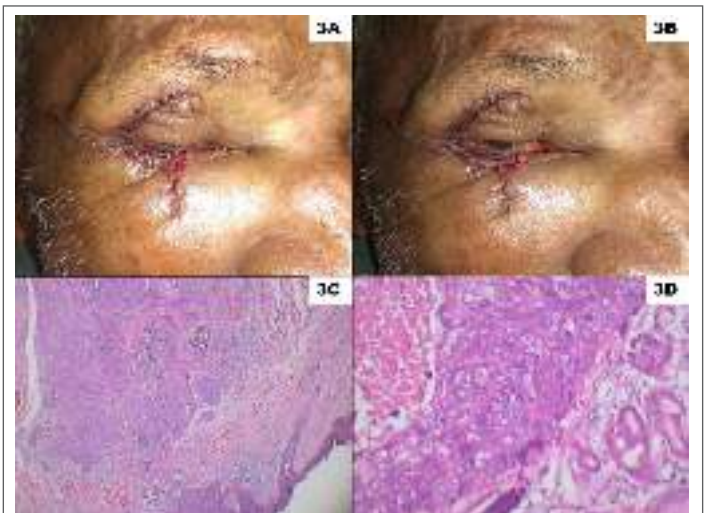


Figure 3: 3A-Results after the flap division with patient's eye completely closed; 3B-Results after the flap division showing the ability of the patient to elevate the eyelid; 3C-Photomicrograph showing partially circumscribed tumor with focally infiltrative margins, arranged in islands, duct-like and cystic spaces. The tumor cells are polygonal to squamoid, with high nucleus:cytoplasmic ratio (hematoxylin and eosin stain [H&E], x40); 3D-Photomicrograph shows tumor in a duct pattern along with central comedo necrosis in the larger duct. The cells show pleomorphic vesicular nuclei, and overlapping with prominent nucleoli (H&E, x400).

mucosa, hard palate mucoperiosteum, auricular and nasoseptal cartilage [16,17]. However, each technique has its advantages and disadvantages. In the present patient, anterior lamella was reconstructed using lid switch with facial rotation flap whereas posterior lamella was reconstructed with buccal mucosal graft. The choice was owing to its simplicity as well as prior experience with using these reconstructive techniques.

Conclusion

The purpose of presenting this case is to highlight the rarity of the sebaceous gland carcinoma of the eyelid, the importance of early diagnosis, and need for thorough understanding of the anatomy to ensure proper reconstruction.

References

1. Coroi MC, Roşca E, Muţiu G, Coroi T, Bonta M (2010) Eyelid tumors: histopathological and clinical study performed in County Hospital of Oradea between 2000-2007. *Rom J Morphol Embryol* 51: 111-115.
2. Lober CW, Fenske NA (1991) Basal cell, squamous cell, and sebaceous gland carcinomas of the periorbital region. *J Am Acad Dermatol* 25: 685-690.
3. Hata M, Koike I, Omura M, Maegawa J, Ogino I, et al. (2012) Noninvasive and curative radiation therapy for sebaceous carcinoma of the eyelid. *Int J Radiat Oncol Biol Phys* 82: 605-611.
4. Ainsbinder DJ, Esmaeli B, Groo SC, Finger PT, Brooks JP (2009) Introduction of the 7th edition eyelid carcinoma classification system from the American Joint Committee on Cancer-International Union Against Cancer staging manual. *Arch Pathol Lab Med* 133: 1256-1261.
5. Doxanas MT, Green WR (1984) Sebaceous gland carcinoma. Review of 40 cases. *Arch Ophthalmol* 102: 245-249.
6. Dasgupta T, Wilson LD, Yu JB (2009) A retrospective review of 1349 cases of sebaceous carcinoma. *Cancer* 115: 158-165.

7. Imko-Walczuk B, Kryś A, Lizakowski S, Dębska-Ślizień A, Rutkowski B, et al. (2014) Sebaceous carcinoma in patients receiving long-term immunosuppressive treatment: case report and literature review. *Transplant Proc* 46: 2903-2907.
8. Shields JA, Demirci H, Marr BP, Eagle RC Jr, Shields CL (2004) Sebaceous carcinoma of the eyelids: personal experience with 60 cases. *Ophthalmology* 111: 2151-2157.
9. Choi YJ, Jin HC, Lee MJ, Kim N, Choung HK, et al. (2014) Prognostic value of clinical and pathologic T stages defined by the American Joint Committee on Cancer for eyelid sebaceous carcinoma in Korea. *Jpn J Ophthalmol* 58: 327-333.
10. Yin VT, Merritt HA, Sniogowski M, Esmaeli B (2015) Eyelid and ocular surface carcinoma: diagnosis and management. *Clin Dermatol* 33: 159-169.
11. Hsu A, Frank SJ, Ballo MT, Garden AS, Morrison WH, et al. (2008) Postoperative adjuvant external-beam radiation therapy for cancers of the eyelid and conjunctiva. *Ophthal Plast Reconstr Surg* 24: 444-449.
12. Zürcher M, Hintschich CR, Garner A, Bunce C, Collin JR (1998) Sebaceous carcinoma of the eyelid: a clinicopathological study. *Br J Ophthalmol* 82: 1049-1055.
13. Madge SN, Khine AA, Thaller VT, Davis G, Malhotra R, et al. (2010) Globe-sparing surgery for medial canthal Basal cell carcinoma with anterior orbital invasion. *Ophthalmology* 117: 2222-2228.
14. Rahmi D, Mehmet B, Ceyda B, Sibel O (2014) Management of the large upper eyelid defects with cutler-beard flap. *J Ophthalmol* 2014: 424567.
15. Rubino C, Farace F (2006) A large lower eyelid reconstruction: nasojugal flaps plus V-Y advancement flap. *Acta Chir Plast* 48: 3-4.
16. Cheng JX, Zuo L, Huang XY, Cui JZ, Wu S, et al. (2015) Extensive full-thickness eyelid reconstruction with rotation flaps through "subcutaneous tunnel" and palatal mucosal grafts. *Int J Ophthalmol* 8: 794-799.
17. Acikel C, Celikoz B, Yildiz TF (2004) Y-shape hard palate mucoperiosteal graft and V-Y advancement flap in the reconstruction of a combined defect involving lateral canthus and upper and lower eyelids. *Ann Plast Surg* 52: 97-101.