

HOSTED BY



ELSEVIER

Contents lists available at ScienceDirect

Journal of Acute Disease

journal homepage: [www.jadweb.org](http://www.jadweb.org)Case report <http://dx.doi.org/10.1016/j.joad.2016.08.026>

## A rare case of acute posterior reversible encephalopathy syndrome involving brainstem in a child

Olfa Chakroun-Walha<sup>1\*</sup>, Ichrak Bacha<sup>1</sup>, Mehdi Frikha<sup>2</sup>, Kheireddine Ben Mahfoudh<sup>2</sup>, Noureddine Rekik<sup>1</sup><sup>1</sup>Emergency Department, Habib Bourguiba University Hospital, Sfax, Tunisia<sup>2</sup>Department of Radiology, Habib Bourguiba University Hospital, Sfax, Tunisia

### ARTICLE INFO

#### Article history:

Received 11 Aug 2016

Accepted 27 Aug 2016

Available online 21 Sep 2016

#### Keywords:

Posterior reversible encephalopathy syndrome

Brainstem

Emergency

Imaging

### ABSTRACT

Posterior reversible encephalopathy syndrome (PRES) is a rare entity involving brainstem in very rare reported cases. We describe here the case of a boy who presented to the emergency department for headaches and strabismus. Diagnosis of PRES was retained by magnetic resonance imaging. The causes were blood pressure urgency and renal failure. Location of lesions was very rarely reported in literature and neurological troubles were persistent. Emergency physicians should evocate PRES each time there is a clinical context associated with neurological troubles by a normal brain CT scan. Early diagnosis is very important to treat its causes and improve prognosis.

## 1. Introduction

Posterior reversible encephalopathy syndrome (PRES) is a clinico-radiological entity, which could affect children. The rarest locations are brainstem and cerebellum. We describe here a case of a persistent PRES involving brainstem and cerebellum.

## 2. Case report

It was a 14-year-old boy who presented to the emergency department for persistent headaches. He had no personal or family medical history and also no toxic consumption. His symptoms began one week ago. He began to have low-intensity headaches with no other complaints. After four days of headaches, he had vision disorders (hemianopsia) and bilateral strabismus with hyperemesis and gait difficulty.

The patients received examinations at admission in the emergency intensive care unit consciously. His pupils were equal in miosis and reactive to light. He had a bilateral paralysis of muscles innervated by the third, fourth and sixth cranial pairs.

He could stand up without aid, but he had a waddling gait. No other neurological troubles had been noted. His respiratory state was stable. Though his blood pressure was 200/150 mmHg, his heart rate was 126 beats per minute. His electrocardiogram showed a sinus tachycardia. Besides, the boy had no fever. There were no other abnormalities at examination.

Laboratory exams on admission showed a high serum level of creatine (974.0 mmol/L) and urea (48.7 μmol/L) with an anaemia (8.4 g/dL) and a low prothrombin time (50%). An abdominal ultrasound showed two little kidneys (7 cm) suggesting a chronic renal failure. Ocular fundus examination noted signs of hypertensive retinopathy grade III. The head CT scan was performed urgently. It showed an oedema in brainstem. The patient was treated for his hypertensive urgency by continuous perfusion of nicardipine. A brain magnetic resonance imaging (MRI) was performed at 24 h after admission. It showed a T2 and fluid-attenuated inversion recovery imaging. Hyperintense lesions of the brain stem were partially extended to the cerebellum without contrast enhancement after intravenous contrast administration or anomalous diffusion disorders (Figure 1).

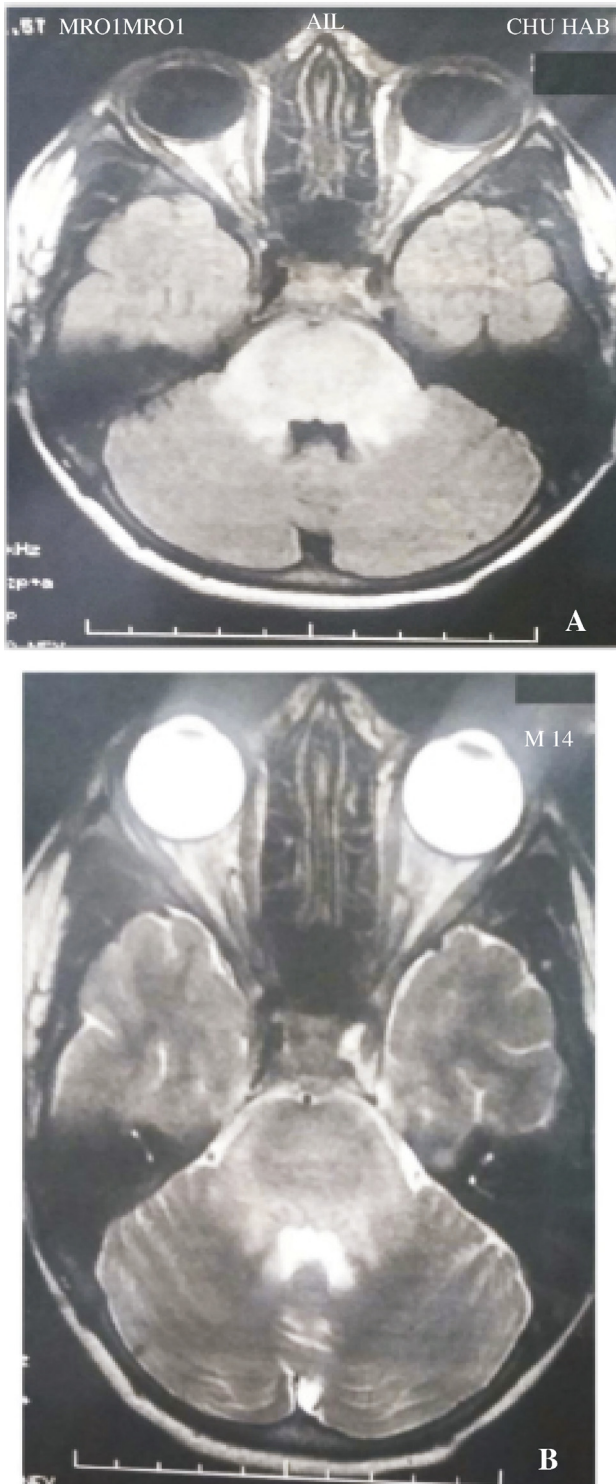
The patient was transferred to a nephrology ward. He presented a single episode of generalized tonic-clonic seizures. Haemodialysis was performed every three days. Headaches and vomiting disappeared after blood pressure normalization and haemodialysis. Gait disturbances were less important, but all other neurological troubles such as vision troubles, hemianopsia and strabismus were persistent. A brain CT scan was performed

\*Corresponding author: Olfa Chakroun-Walha, Emergency Department, Habib Bourguiba University Hospital, Sfax, Tunisia.

Tel: +216 58127693

E-mail: [chakroun\\_olfa@medecinesfax.org](mailto:chakroun_olfa@medecinesfax.org)

Peer review under responsibility of Hainan Medical College. The journal implements double-blind peer review practiced by specially invited international editorial board members.



**Figure 1.** Brain MRI at admission showing fluid-attenuated inversion recovery imaging (A) and T2 sequences (B) hyper intensities in brainstem and cerebellum.

again when seizures appeared. It showed the same lesions on brainstem. The boy was discharged one week after transferred with hypertension treatment and programmed haemodialysis sessions.

### 3. Discussion

PRES was first described by Hinchey *et al.*<sup>[1]</sup>. Now, it is described more and more frequently because of the improved

available brain imaging<sup>[2,3]</sup>. Its incidence rate in paediatric population is estimated to be 0.4%<sup>[4]</sup>. This clinico-radiological entity is mainly explained by hypertensive encephalopathy. As it is reported in literature, our patient described headaches, vision disturbances and visual fields deficits with a continued progression for many days<sup>[2,3,5]</sup>. Clinical features of PRES are not specific. The most reported clinical signs are headaches, confusion, vomiting, seizures and visual troubles<sup>[2,6–9]</sup>. Thus, it is usually important to evaluate the clinical context like eclampsia, blood pressure fluctuation, renal failure and autoimmune disorders<sup>[7,10]</sup>. Brain imaging by a CT scan is useful to exclude alternative diagnosis at emergency department. Nevertheless, diagnosis of PRES is retained on MRI and emergency physicians should evocate PRES each time there is a clinical context associated to neurological troubles with a normal brain CT scan. Vasogenic oedema can be visualized using non-contrast CT in some patients, but MRI is much more sensitive<sup>[2,11]</sup>. Classic locations of lesions are parietooccipital areas in 98% of cases<sup>[5,12,13]</sup>, but the presence of oedema in other regions is possible<sup>[2,5,10,14]</sup>. Oedema can affect the basal ganglia, brainstem and cerebellum<sup>[7,15–18]</sup>. However, oedema in these locations is most frequently accompanied by concomitant involvement of the parietooccipital regions. The particularity of our patient is that all lesions were involving exclusively brainstem and cerebellum with no other lesions in parietooccipital areas. In literature, exclusively cerebellar or brainstem location seems to be more frequent among children and is usually associated with renal failure<sup>[19,20]</sup>. As it was in our reported case, PRES is not always fully reversible despite its name<sup>[2,7,12]</sup>. Intracranial haemorrhage is thought to be the cause of these persistent forms<sup>[2,8,9,21,22]</sup>, but it is not confirmed in our case. Persistent neurological troubles are probably explained in our case by later presentation at the emergency department.

This case is important for the rarity of lesions' location and for persistent neurological disturbances. It is important for physicians in the emergency departments to be aware of this entity to treat its causes early in order to improve prognosis.

### Conflict of interest statement

The authors report no conflict of interest.

### References

- [1] Hinchey J, Chaves C, Appignani B, Breen J, Pao L, Wang A, et al. A reversible posterior leukoencephalopathy syndrome. *N Engl J Med* 1996; **334**(8): 494-500.
- [2] Fugate JE, Rabinstein AA. Posterior reversible encephalopathy syndrome: clinical and radiological manifestations, pathophysiology, and outstanding questions. *Lancet Neurol* 2015; **14**(9): 914-25.
- [3] McCoy B, King M, Gill D, Twomey E. Childhood posterior reversible encephalopathy syndrome. *Eur J Paediatr Neurol* 2011; **15**(2): 91-4.
- [4] Raj S, Overby P, Erdfarb A, Ushay HM. Posterior reversible encephalopathy syndrome: incidence and associated factors in a pediatric critical care population. *Pediatr Neurol* 2013; **49**(5): 335-9.
- [5] Furtado A, Hsu A, La Colla L, Zuccoli G. Arterial blood pressure but not serum albumin concentration correlates with ADC ratio values in pediatric posterior reversible encephalopathy syndrome. *Neuroradiology* 2015; **57**(7): 721-8.
- [6] Bartynski WS. Posterior reversible encephalopathy syndrome, part 2: controversies surrounding pathophysiology of vasogenic edema. *AJNR Am J Neuroradiol* 2008; **29**(6): 1043-9.

- [7] Schusse CM, Peterson AL, Caplan JP. Posterior reversible encephalopathy syndrome. *Psychosomatics* 2013; **54**(3): 205-11.
- [8] Yamamoto H, Natsume J, Kidokoro H, Ishihara N, Suzuki M, Tsuji T, et al. Clinical and neuroimaging findings in children with posterior reversible encephalopathy syndrome. *Eur J Paediatr Neurol* 2015; **19**(6): 672-8.
- [9] Pavlakis SG, Frank Y, Chusid R. Hypertensive encephalopathy, reversible occipitoparietal encephalopathy, or reversible posterior leukoencephalopathy: three names for an old syndrome. *J Child Neurol* 1999; **14**(5): 277-81.
- [10] Siebert E, Spors B, Bohner G, Endres M, Liman TG. Posterior reversible encephalopathy syndrome in children: radiological and clinical findings – a retrospective analysis of a German tertiary care center. *Eur J Paediatr Neurol* 2013; **17**(2): 169-75.
- [11] Dandoy CE, Linscott LL, Davies SM, Leach JL, Myers KC, El-Bietar J, et al. Clinical utility of computed tomography and magnetic resonance imaging for diagnosis of posterior reversible encephalopathy syndrome after stem cell transplantation in children and adolescents. *Biol Blood Marrow Transplant* 2015; **21**(11): 2028-32.
- [12] Daniel NJ, Hernandez CL, Walker RA. Recurrent posterior reversible encephalopathy syndrome in a pediatric patient with end-stage renal disease. *J Emerg Med* 2014; **46**(2): e39-42.
- [13] Kastrop O, Schlamann M, Moeninghoff C, Forsting M, Goericke S. Posterior reversible encephalopathy syndrome: the spectrum of mr imaging patterns. *Clin Neuroradiol* 2015; **25**(2): 161-71.
- [14] Tari Capone F, Candela S, Bozzao A, Orzi F. A new case of brainstem variant of posterior reversible encephalopathy syndrome: clinical and radiological features. *Neurol Sci* 2015; **36**(7): 1263-5.
- [15] Fugate JE, Claassen DO, Cloft HJ, Kallmes DF, Kozak OS, Rabinstein AA. Posterior reversible encephalopathy syndrome: associated clinical and radiologic findings. *Mayo Clin Proc* 2010; **85**(5): 427-32.
- [16] Mueller-Mang C, Mang T, Pirker A, Klein K, Prchla C, Prayer D. Posterior reversible encephalopathy syndrome: do predisposing risk factors make a difference in MRI appearance? *Neuroradiology* 2009; **51**(6): 373-83.
- [17] Liman TG, Bohner G, Heuschmann PU, Endres M, Siebert E. The clinical and radiological spectrum of posterior reversible encephalopathy syndrome: the retrospective Berlin PRES study. *J Neurol* 2012; **259**(1): 155-64.
- [18] McKinney AM, Short J, Truwit CL, McKinney ZJ, Kozak OS, SantaCruz KS, et al. Posterior reversible encephalopathy syndrome: incidence of atypical regions of involvement and imaging findings. *AJR Am J Roentgenol* 2007; **189**(4): 904-12.
- [19] Etinger N, Pearson M, Lamb FS, Wellons JC 3rd. Pediatric posterior reversible encephalopathy syndrome presenting with isolated cerebellar edema and obstructive hydrocephalus. *J Neurosurg Pediatr* 2014; **14**(4): 344-7.
- [20] Ishikura K, Ikeda M, Hamasaki Y, Hataya H, Shishido S, Asanuma H, et al. Posterior reversible encephalopathy syndrome in children: its high prevalence and more extensive imaging findings. *Am J Kidney Dis* 2006; **48**(2): 231-8.
- [21] Moon SN, Jeon SJ, Choi SS, Song CJ, Chung GH, Yu IK, et al. Can clinical and MRI findings predict the prognosis of variant and classical type of posterior reversible encephalopathy syndrome (PRES)? *Acta Radiol* 2013; **54**(10): 1182-90.
- [22] Shaharir SS, Remli R, Marwan AA, Said MS, Kong NC. Posterior reversible encephalopathy syndrome in systemic lupus erythematosus: pooled analysis of the literature reviews and report of six new cases. *Lupus* 2013; **22**(5): 492-6.