

HOSTED BY



ELSEVIER

Contents lists available at ScienceDirect

Journal of Acute Disease

journal homepage: www.jadweb.orgOriginal article <http://dx.doi.org/10.1016/j.joad.2016.08.021>

Treatment of acute proximal humeral fractures in children with modular external fixator

Michele Bisaccia¹, Luigi Meccariello^{2*}, Mattia Manni¹, Gabriele Falzarano², Antonio Medici², Giuseppe Rinonapoli¹, Salvatore Di Giacinto³, Giovanni Colleluori¹, Cristina Ibáñez Vicente¹, Paolo Ceccarini¹, Olga Bisaccia⁴, Auro Caraffa¹

¹Department of Orthopaedics and Traumatology, S.M. Misericordia Hospital, University of Perugia, Perugia, Italy

²U.O.C. Orthopedics and Traumatology, Azienda Ospedaliera “Gaetano Rummo”, Benevento, Italy

³SOC Pediatric Orthopaedic and Traumatology, Azienda Ospedaliero-Universitaria Meyer, Firenze, Italy

⁴Department of Radiology, San Donato Hospital, University of Milano, Milano, Italy

ARTICLE INFO

Article history:

Received 10 Aug 2016

Received in revised form 18 Aug 2016

Accepted 25 Aug 2016

Available online 15 Oct 2016

Keywords:

Proximal humeral fractures

Children

Modular external fixator

Hoffmann II

ABSTRACT

Objective: To evaluate the follow-up of the fractures treated by external fixator.

Methods: A total of 31 children aged 6–15 years with proximal humeral fractures Grade IV according to Neer–Horowitz classification were treated. The medium follow-up was 24 months.

Results: In all cases, a good stability of the fracture and a quick healing process were obtained. The mean time of follow-up was 24 months. The external fixation was removed after 6 weeks (5–8 weeks) on average. Constant shoulder score was proposed to all patients and the average result was 97.5 (84–100).

Conclusions: Advantages of the external fixation are rapid mobilization of the joint, low invasiveness, a single surgery and the possibility to correct any secondary displacement. It is important to underline that the positioning of external fixator should be implanted by expert surgeons and that the patients must cooperate during the entire process up to the time of the removal of the fixator.

1. Introduction

Proximal humeral fractures represent less than 1% of all the pediatric fractures and they include between 3% and 6% of slipped epiphyseal fractures^[1,2]. Considering children aged between 5 and 12 years, these fractures are found mainly in teenagers. In the infant period, they are secondary only to clavicle fractures^[3]. The mechanism of trauma differs according to the age of the patients. In infants, these fractures occur during passage through the birth canal, while in children, they occur as a consequence of falls on the hands in outstretched

position. This kind of fracture usually does not cause a bone deformity, because the periosteum is thicker and has a high potential of remodeling in this region^[4,5].

Pavone *et al.* proposed a classification based on the displacement of the fracture^[6]. In the first grade, the displacement is up to 5 mm. In the second grade, the displacement is up to 1/3 of the diameter of humeral diaphysis. In the third grade, the displacement is up to 2/3. And in the fourth grade, it is over 2/3. The limit of this classification is that it does not considerate the angulation and the malrotation of the fragments.

The clinical evaluation is also correlated to the age of patients. In infants, there is crying with pseudoparalysis of the affected limb and in children, there are pain, swelling and decreased or absent motility with shortening of the limb. It is important to take into account the state of peripheral vessels and nerves^[1].

The radiographic evaluation is done by RX images in two projections comparing the contralateral limb. In this study, only Grade IV fractures were included, as a consequence of an important grade of breakdown of the fracture. In many cases, a surgical treatment is necessary. The aim of this paper is to

*Corresponding author: Luigi Meccariello, U.O.C. Orthopedics and Traumatology, Azienda Ospedaliera “Gaetano Rummo”, Benevento, Italy.

Tel: +39 3299419574

Fax: +39 0823713864

E-mail: drlordmec@gmail.com

The study protocol was performed according to the Helsinki Declaration. Informed written consent was obtained from all patients.

Peer review under responsibility of Hainan Medical College. The journal implements double-blind peer review practiced by specially invited international editorial board members.

evaluate the results of the external fixators in the treatment of these types of fractures.

2. Materials and methods

From January 2000 to January 2013, 31 children were treated with external fixation Hoffman II for proximal humeral fractures in Department of Orthopaedics and Traumatology, S.M. Misericordia Hospital in Perugia and U.O.C. Orthopedics and Traumatology, Azienda Ospedaliera “Gaetano Rummo” in Benevento. All these fractures belonged to Grade IV according to Neer and Horowitz classification.

Exclusion criteria were the following: pathological fractures, exposed fractures, fractures with vessel and nerve damage, Grade I, II and III according to Neer classification and poly-trauma patients.

We did not lose any patients during the follow-up.

In all cases mentioned above, surgery was carried out within 24 h from the trauma with general anesthesia and beach chair position.

First, we performed a reduction through a longitudinal traction with abduction and extra-rotation of the limb under control of the brilliance amplification. In cases which the reduction was not acceptable, a proximal fiche was placed as a joystick. Open reduction and internal fixation were not necessary.

After the successful reduction of the fractures, two proximal fiches were first placed, then two distal ones connected with bars and clamps were placed. The fluoroscopy was checked in that there was no breakdown of the fracture, but there was passive mobilization of the shoulder and the R.O.M. was complete.

From the first day, post-operative patients were asked to perform active and passive mobilization of the shoulder. Radiographic controls were carried out on the day after the surgery, after 2 weeks and at the time to remove the external fixator (on average after 6 weeks). The removal of fiches was carried out with a mild sedation. For the evaluation of the results, the Constant score was used. The study was conducted in accordance with the ethical standards of the declaration of Helsinki and informed consent was obtained from all patients.

3. Results

Among 31 patients, 19 were males and 12 were females. In 18 cases, the right shoulder was involved, whereas in 14 of them, the left one was involved. The age was between 6 and 15 years (on average 10.6). The average surgical time was 38 min (25–61 min).

In none of the cases, an open reduction and an internal fixation were necessary (Figures 1–10). The hospital stay after the surgery was 2 days on average and the mean time of follow-up was 24 months (13–36 months). In all cases, an arm sling tutor which was removed many times a day was applied, in order to allow active and passive mobilization of the shoulder and active mobilization of the elbow from the first day after surgery (Figures 8 and 9). No any complications appeared such as neurovascular damages, loss of reduction and loss of grip of the fiches. Only in three cases, a superficial infection of a fiche appeared, resolved with local antibiotic therapy.

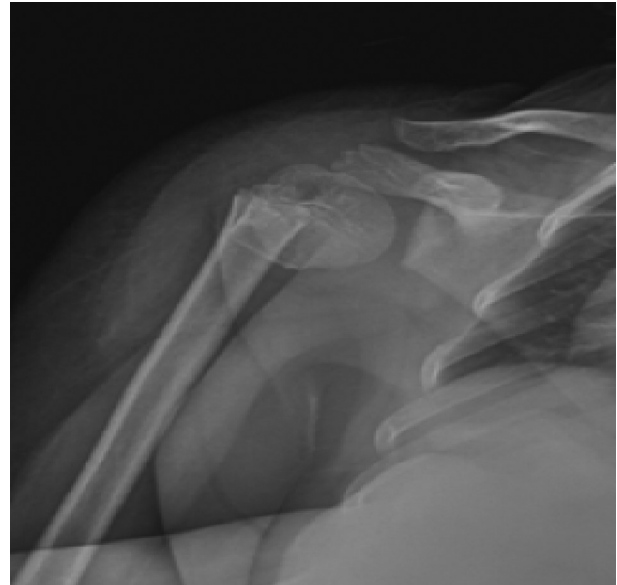

Figure 1. Proximal humeral fracture.

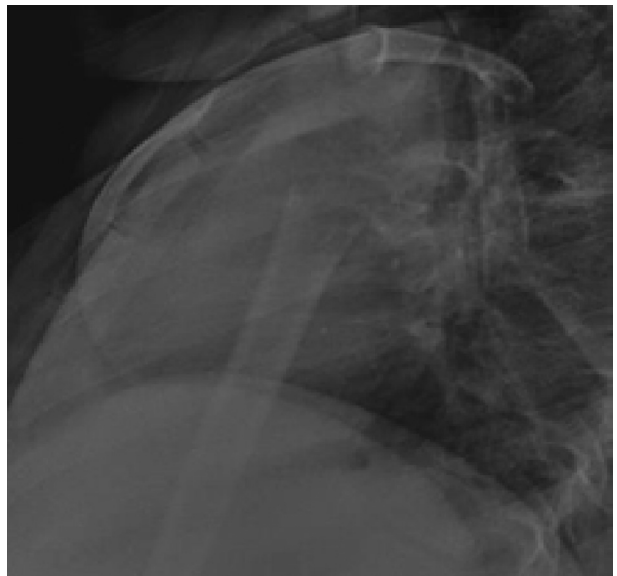


Figure 2. The important grade of displacement of the fracture.

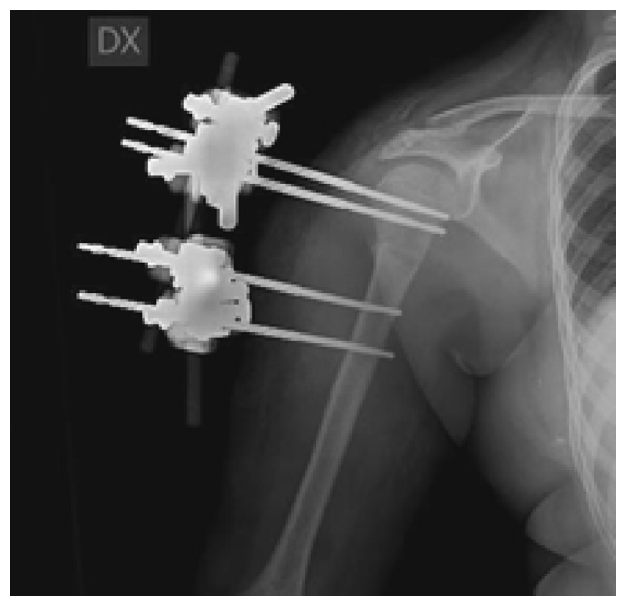


Figure 3. Post-operative image after the external fixation.

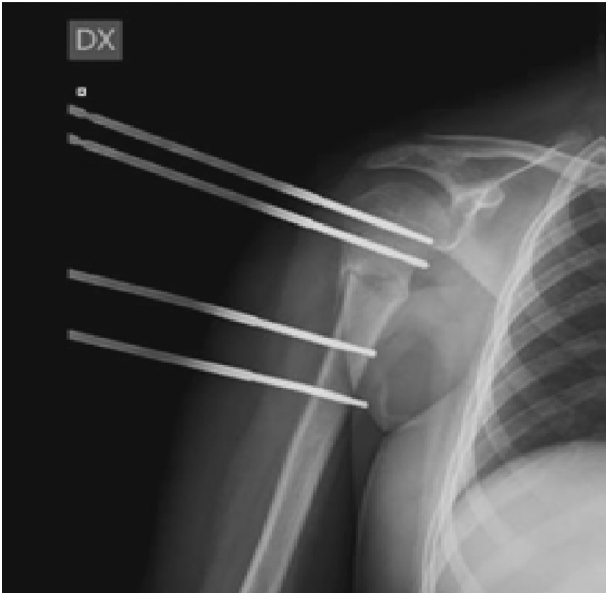


Figure 4. RX image in 6th weeks after the surgery, at the same time of removing the external fixator.

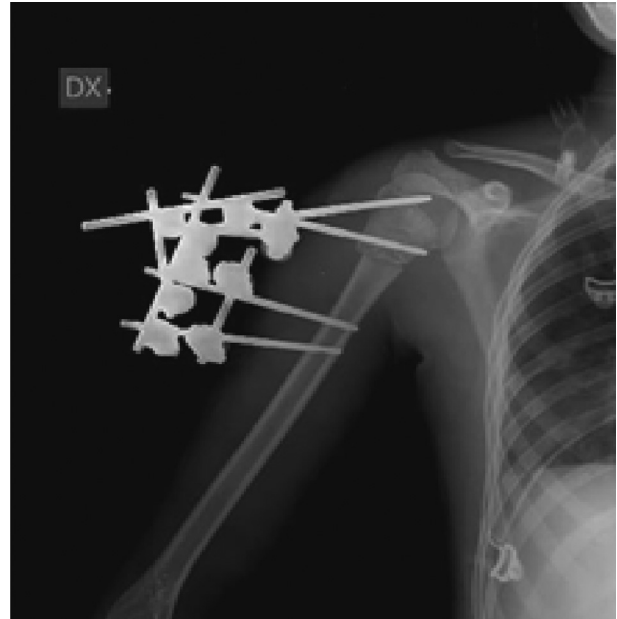


Figure 6. RX image after reduction and external fixation.

The external fixation was removed after 6 weeks (5–8 weeks) on average. And in all cases, there was a quick return to complete range of motion of shoulder and elbow, equal to the contralateral, 2 months on average after the surgery.

Constant shoulder score was proposed to all patients and the average result was 97.5 (84–100) (Table 1)^[7]. About 6 months later, all patients were asked whether they felt satisfied with the results and shoulder movements. A total of 27 patients were very satisfied and four of them were satisfied. All patients were able to once again perform all daily activities and sports as they had done before the injury. In all cases, a good stability of the fracture and a rapid consolidation were obtained (Figure 10). The external fixation was well tolerated by all children.

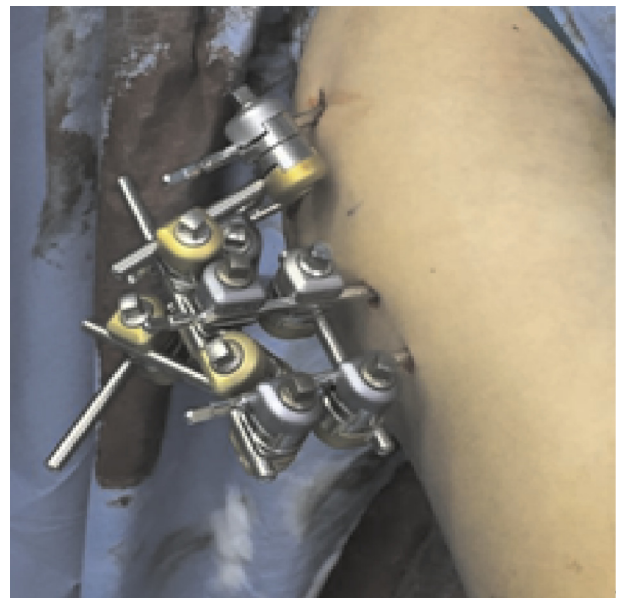


Figure 7. Intra-operative image.

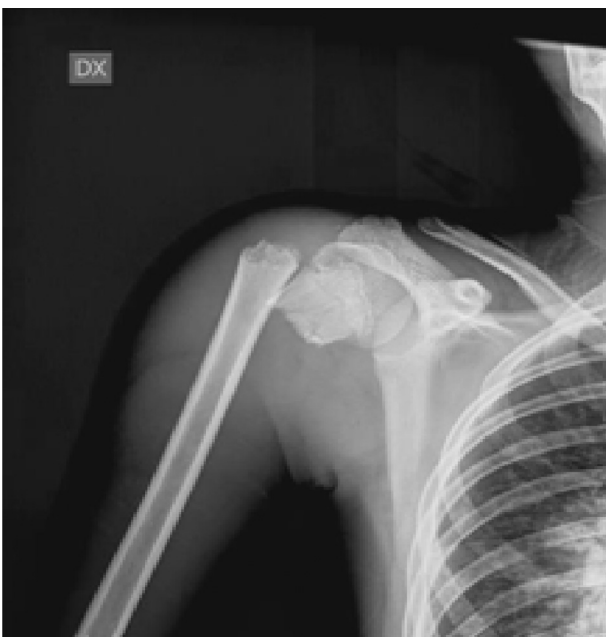

Figure 5. A displaced proximal humeral fracture (Neer IV).

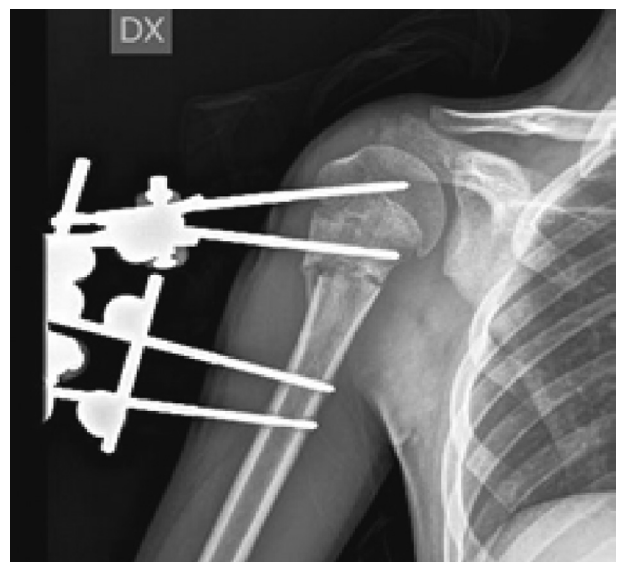


Figure 8. RX image in 6th weeks after the surgery.




Figure 9. Active mobilization of the shoulder.

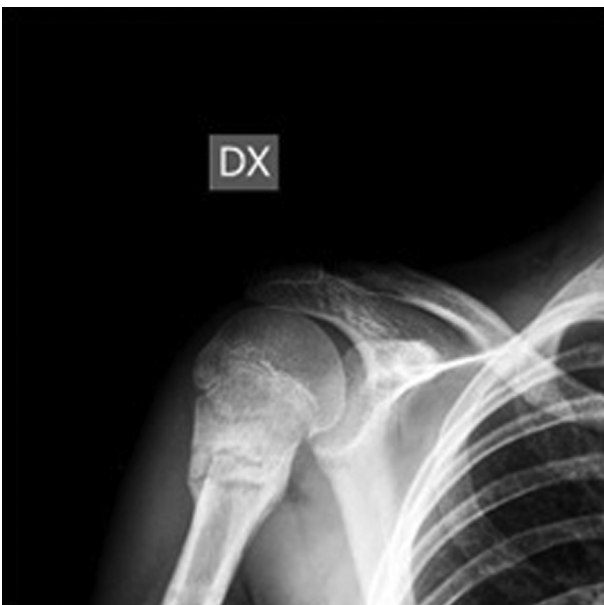

Figure 10. Results after the surgery in 2 months with the consolidation of the fracture.

Table 1

Sex, age, side, classification, traumatic mechanism and Constant scores of each patient.

Progressive number of patients	Sex	Age	Side	Neer and Horowitz classification	Traumatic mechanisms	Constant scores
1	M	8	R	IV	Sport injury	100
2	M	15	L	IV	Accidental fall	84
3	F	11	R	IV	Sport injury	100
4	M	10	R	IV	Traffic accident	100
5	M	13	L	IV	Sport injury	96
6	M	12	R	IV	Sport injury	96
7	M	6	L	IV	Accidental fall	100
8	F	9	R	IV	Sport injury	96
9	F	10	R	IV	Traffic accident	96
10	M	9	R	IV	Traffic accident	100
11	M	11	L	IV	Accidental fall	100
12	F	8	R	IV	Unknown	94
13	M	13	L	IV	Accidental fall	100
14	M	11	L	IV	Accidental fall	92
15	F	9	R	IV	Sport injury	96
16	M	10	R	IV	Sport injury	95
17	M	9	R	IV	Sport injury	100

Table 1 (continued)

Progressive number of patients	Sex	Age	Side	Neer and Horowitz classification	Traumatic mechanisms	Constant scores
18	F	12	L	IV	Sport injury	100
19	F	10	R	IV	Accidental fall	98
20	M	9	R	IV	Unknown	100
21	M	8	L	IV	Sport injury	96
22	M	14	L	IV	Traffic accident	100
23	F	12	L	IV	Accidental fall	98
24	F	9	R	IV	Sport injury	96
25	M	13	R	IV	Sport injury	95
26	M	15	L	IV	Traffic accident	100
27	F	9	R	IV	Sport injury	100
28	M	10	R	IV	Accidental fall	98
29	F	8	L	IV	Accidental fall	100
30	F	12	R	IV	Unknown	97
31	M	14	L	IV	Traffic accident	100

M: Male; F: Female; R: Right side; L: Left side.

4. Discussion

Due to the high capacity for remodelling potential, the vast majority of humeral fractures in children can be treated conservatively^[8,9]. This happens because of a thick periosteum and because it is closer to a physis.

In the case of perinatal fractures, a simple pinning of the sleeve to the body is sufficient. In these cases, closed reduction is rarely needed and ultrasound is sufficient to check the alignment. Healing is extremely rapid and occurs within 2–3 weeks.

As a consequence, in this type of fracture, angulations are tolerable up to 50° before adolescence and 20° after adolescence^[10]. Remodelling potential decreases with age and consequently increases the surgical indication.

Many authors recommend surgical stabilization in older children and in cases of a high displacement^[9-11]. In these cases, the percutaneous fixation represents the best treatment for these fractures reserving the open reduction and internal fixation in selected cases^[12,13].

In cases where surgery is required, the most described techniques in literature are percutaneous pins and elastic nails^[10,14]. In the first approach, there is a possibility of damaging the axillary nerve and in the second, it is possible to damage the ulnar nerve^[15,16]. If you follow these steps, you need a second surgery in general anesthesia in order to remove pins and elastic nails, whereas a light sedation is necessary to remove the external fixation^[2,12,17].

The aim of our work is to analyze the results obtained with the external fixation in the treatment of this type of fractures. External fixation, all things consistent with the other techniques described in the literature, allows a good reduction of the fracture and excellent healing. It also has the advantage of being minimally invasive, does not require a second surgery for removal of synthetic means and allows quick mobilization of joints and in case of secondary displacement of the fracture. It is possible to modify the external fixator to correct the displacement without the need for a second surgical intervention. Another advantage referring to elastic nails is the possibility of avoiding the passage through the physis.

Also, this method shows a very low risk of infection, even considering a short duration of treatment in these cases^[18,19]. In our cases, we had only three cases of superficial infection of a fice when solved with local antibiotic therapy, but no case of deep infection.

The disadvantage of external fixation implant could be the risk of a poor tolerance of this procedure, especially in young patients and that a greater rate of compliance by the patient as compared to other synthetic means is required. In our patients, there weren't any reports of complaints during daily activities or medication of fices^[20]. During the positioning of proximal fices, it is very important to pay attention to the axillary nerve^[14]. Some authors recommend to place the distal fices, 8 cm far from the superior margin of the humeral head^[15]. However, we first placed the proximal fice in the humeral head and then, after control of the alignment by intensifier, we placed the second proximal fice and the two distal ones.

As regards the radiographic controls, after 2 weeks we made them to check that there was no secondary fracture breakdown and around 6 weeks at the time of removal of the fixator. Comparing the data in the literature, it can be stated that the external fixation in proximal humeral fractures in children can be a valid alternative to the other surgical techniques. There are a lot of benefits, such as a quick mobilization of the joint, low invasiveness, only one surgery and the possibility to correct any secondary displacement.

It is important to underline that the positioning of the external fixation could be implanted by experienced surgeons and that the patients should be cooperative to handle it until removal.

Conflict of interest statement

The authors report no conflict of interest.

References

- [1] Topor LS, Borus JS, Aspinwall S, Gilbert CL, Gordon CM, Huh SY. Fractures among inpatients in a pediatric hospital. *Hosp Pediatr* 2016; **6**(3): 143-50.
- [2] Shore BJ, Hedequist DJ, Miller PE, Waters PM, Bae DS. Surgical management for displaced pediatric proximal humeral fractures: a cost analysis. *J Child Orthop* 2015; **9**(1): 55-64.
- [3] Wegmann H, Orendi I, Singer G, Eberl R, Castellani C, Schalamon J, et al. The epidemiology of fractures in infants – which accidents are preventable? *Injury* 2016; **47**(1): 188-91.
- [4] Schneidmueller D, von Räden C, Friederichs J, Bühren V. [Transitional fractures: epiphyseal injuries in adolescence]. *Unfallchirurg* 2016; **119**(6): 517-26. German.
- [5] Chaus GW, Carry PM, Pishkenari AK, Hadley-Miller N. Operative versus nonoperative treatment of displaced proximal humeral physal fractures: a matched cohort. *J Pediatr Orthop* 2015; **35**(3): 234-9.
- [6] Pavone V, de Cristo C, Cannavò L, Testa G, Buscema A, Condorelli G, et al. Midterm results of surgical treatment of displaced proximal humeral fractures in children. *Eur J Orthop Surg Traumatol* 2016; **26**(5): 461-7.
- [7] Bahrs C, Zipplies S, Ochs BG, Rether J, Oehm J, Eingartner C, et al. Proximal humeral fractures in children and adolescents. *J Pediatr Orthop* 2009; **29**(3): 238-42.
- [8] Caviglia H, Garrido CP, Palazzi FF, Meana NV. Pediatric fractures of the humerus. *Clin Orthop Relat Res* 2005; **432**: 49-56.
- [9] Lefèvre Y, Journeau P, Angelliaume A, Bouty A, Dobremez E. Proximal humerus fractures in children and adolescents. *Orthop Traumatol Surg Res* 2014; **100**(1 Suppl): S149-56.
- [10] Di Gennaro GL, Spina M, Lampasi M, Libri R, Donzelli O. Fractures of the proximal humerus in children. *Chir Organi Mov* 2008; **92**(2): 89-95.
- [11] Kraus T, Hoermann S, Ploder G, Zoetsch S, Eberl R, Singer G. Elastic stable intramedullary nailing versus Kirschner wire pinning: outcome of severely displaced proximal humeral fractures in juvenile patients. *J Shoulder Elbow Surg* 2014; **23**(10): 1462-7.
- [12] Hutchinson PH, Bae DS, Waters PM. Intramedullary nailing versus percutaneous pin fixation of pediatric proximal humerus fractures: a comparison of complications and early radiographic results. *J Pediatr Orthop* 2011; **31**(6): 617-22.
- [13] Keskin D, Sen H. The comparative evaluation of treatment outcomes in pediatric displaced supracondylar humerus fractures managed with either open or closed reduction and percutaneous pinning. *Acta Chir Orthop Traumatol Cech* 2014; **81**(6): 380-6.
- [14] Rowles DJ, McGrory JE. Percutaneous pinning of the proximal part of the humerus. An anatomic study. *J Bone Joint Surg Am* 2001; **83-A**(11): 1695-9.
- [15] Mehin R, Mehin A, Wickham D, Letts M. Pinning technique for shoulder fractures in adolescents: computer modelling of percutaneous pinning of proximal humeral fractures. *Can J Surg* 2009; **52**(6): E222-8.
- [16] Wang X, Shao J, Yang X. Closed/open reduction and titanium elastic nails for severely displaced proximal humeral fractures in children. *Int Orthop* 2014; **38**(1): 107-10.
- [17] Sénès FM, Catena N. Intramedullary osteosynthesis for metaphyseal and diaphyseal humeral fractures in developmental age. *J Pediatr Orthop B* 2012; **21**(4): 300-4.
- [18] Chilakamary VK, Lakkireddy M, Koppolu KK, Rapur S. Osteosynthesis in distal radius fractures with conventional bridging external fixator; tips and tricks for getting them right. *J Clin Diagn Res* 2016; **10**(1): RC05-8.
- [19] Parikh SN, Lykissas MG, Roshdy M, Mineo RC, Wall EJ. Pin tract infection of operatively treated supracondylar fractures in children: long-term functional outcomes and anatomical study. *J Child Orthop* 2015; **9**(4): 295-302.
- [20] Bisaccia M, Manni M, Colleluori G, Falzarano G, Medici A, Meccariello L, et al. The management of pin-care in external fixation technique: povidone-iodine versus sodium hypochlorite 0.05% (Amukina-Med®) medications. *EuroMediterr Biomed J* 2016; **11**(10): 81-7.