



HOSTED BY



ELSEVIER

Contents lists available at ScienceDirect

Journal of Acute Disease

journal homepage: www.jadweb.orgCase report <http://dx.doi.org/10.1016/j.joad.2016.08.013>

Refractory thrombotic thrombocytopenic purpura following acute pancreatitis

Ebisa Bekele^{1*}, Bethel Shiferaw¹, Alexandra Sokolova¹, Arpan Shah¹, Phillip Saunders¹, Alida Podrumar², Javed Iqbal³¹Department of Medicine, Nassau University Medical Center, East Meadow, New York, USA²Department of Medicine, Division of Hematology and Oncology, Nassau University Medical Center, East Meadow, New York, USA³Department of Medicine, Division of Pulmonary and Critical Care, Nassau University Medical Center, East Meadow, New York, USA

ARTICLE INFO

Article history:

Received 13 May 2016

Received in revised form 13 Jul 2016

Accepted 31 Jul 2016

Available online 11 Aug 2016

Keywords:

Thrombotic thrombocytopenic purpura

Acute pancreatitis

Refractory

Plasmapheresis

ABSTRACT

Thrombotic thrombocytopenic purpura (TTP) is a rare blood disorder with an estimated incidence of 4–5 cases per million people per year. It is characterized by small-vessel platelet-rich thrombi that cause thrombocytopenia, microangiopathic hemolytic anemia and organ damage. There are reports in literature that TTP and acute pancreatitis are associated, indicating each can be the cause of the other. However, acute pancreatitis triggering TTP is very rare. A 71 years old female presented with abdominal pain of 3 days, followed by dark urine. She had icteric sclera, petechial rash and mild epigastric tenderness. Lab findings were significant for hemolytic anemia, thrombocytopenia and elevated lipase. CT of abdomen showed evidence of pancreatitis and cholelithiasis. After admission, patient developed symptoms of stroke. Further investigation showed elevated lactate dehydrogenase and normal coagulation studied with peripheral blood smear showed 5–6 schistocytes/high power field. Disintegrin and metalloproteinase with thrombospondin motifs-13 (ADAMTS13) activity showed less than 3% with high ADAMTS13 inhibitor 2.2. Patient required 6–7 weeks of daily plasmapheresis until she showed complete response. Our patient presented with clinical features of pancreatitis prior to having dark urine and petechial rash. Therefore, we strongly believe that our patient had pancreatitis which was followed by TTP. Patient's ADAMTS13 activity was 6% after 10 plasma exchanges, signifying refractory TTP and higher risk for morbidity and mortality. There are limited data and consensus on the management of refractory TTP. TTP and acute pancreatitis are associated. However, refractory TTP following acute pancreatitis is rarely mentioned in the literature. We would like to emphasize the importance of having higher clinical suspicion of the association of both disease entities.

1. Introduction

Thrombotic thrombocytopenic purpura (TTP) is a rare blood disorder with an estimated incidence of about 4–5 cases per million people per year^[1]. It is characterized by small-vessel platelet-rich thrombi that cause thrombocytopenia, microangiopathic hemolytic anemia and sometimes organ damage (neurologic dysfunction or kidney failure).

There are reports in literature that TTP and acute pancreatitis are associated, indicating each can be the cause of the other. However, acute pancreatitis triggering TTP is very rare^[2]. TTP is a medical emergency that is almost always fatal if appropriate treatment is not initiated promptly. We report a case of treatment of refractory TTP following acute pancreatitis.

2. Case presentation

A 71 years old Pakistani female presented with abdominal pain of 3 days. The pain was mid epigastric, intermittent, radiating to her back. The patient complained of bright red blood in the stool. She also noticed dark urine but no dysuria, frequency or urgency. The patient denied any other symptoms. She had a past medical illness of hypertension. On physical exam, vital signs were within normal range. Patient had mildly icteric sclera and petechial rash

*Corresponding author: Ebisa Bekele, MD, Nassau University Medical Center, An Affiliation of North Shore Long Island Jewish Health Care System, East Meadow, New York, USA.

Tel: +1 571 471 7325

E-mail: ebekele@numc.edu

Peer review under responsibility of Hainan Medical College. The journal implements double-blind peer review practiced by specially invited international editorial board members.

on the upper extremities. There was mild tenderness on the epigastric area by deep palpation without guarding.

Laboratory investigation showed white blood cell of 9.39 K/mm^3 , hemoglobin of 9.4 mg/dL , platelet of 28 K/mm^3 and total bilirubin of 5.1 mg/dL (indirect bilirubin of 4.5 mg/dL). Renal function tests were within normal range. Patient had elevated the level of lipase (2463) and CT of abdomen showed peripancreatic fat stranding and small volume ascites suggestive of pancreatitis and cholelithiasis.

Few hours after admission, patient developed slurred speech that lasted for 10 min for which head CT was done and indicated focal hypodensity in the left cerebral peduncle of the midbrain. Further investigation showed elevated lactate dehydrogenase (LDH) (1564) and normal coagulation studies included prothrombin time/international normalized ratio, partial thromboplastin time, d-dimer and fibrinogen. Peripheral blood smear was done to evaluate the cause of thrombocytopenia and hemolytic anemia, which revealed 5–6 schistocytes per high power field (Figure 1).

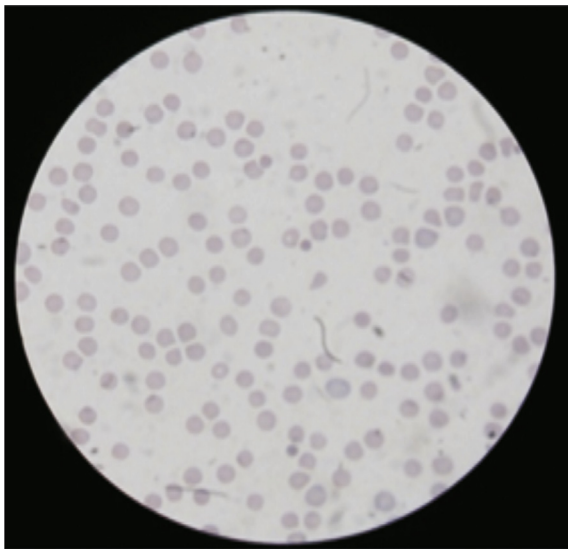


Figure 1. Peripheral blood smear showing schistocytes.

Plasmapheresis was urgently started with possible diagnosis of TTP with findings of peripheral blood smear, thrombocytopenia, hemolytic anemia and neurological symptoms. Later on, disintegrin and metalloproteinase with thrombospondin motifs-13 (ADAMTS13) activity showed less than 3% (range: 68%–163%) with high ADAMTS13 inhibitor 2.2 (range: < 0.4). Patient did not show initial response to daily plasma exchanges and steroid, and then weekly rituximab was started. Only 2 cycles of rituximab was given due to infection and other similar therapies could not also be given for the same reason. Patient continued to have low platelet with elevated LDH and indirect bilirubin and ADAMTS13 post exchange also showed only 6%.

During her stay in the hospital, she received daily plasma exchanges (regular and cryopoor plasma) for 6–7 weeks, until she showed complete response (normal platelet, LDH, indirect bilirubin and ADAMTS13 activity). However, patient's entire stay was complicated with subdural hematoma (SDH), sepsis and respiratory failure.

3. Discussion

Acquired thrombotic thrombocytopenic purpura is a primary thrombotic microangiopathy caused by severe ADAMTS13

deficiency (typically, activity $< 10\%$) due to an inhibitory autoantibody directed against ADAMTS13. The events that actually trigger acute episodes of TTP are often unclear.

The pancreas is frequently involved in patients with TTP and this was explained by platelet/fibrin rich thrombi, causing pancreatic ischemia and leading to pancreatitis^[3]. Pancreatitis can also trigger TTP due to inflammatory response, mediated by cytokines, causing endothelial damage^[4,5].

Our patient first presented with sign and symptoms of pancreatitis prior to having dark urine and petechial rash. The etiology of pancreatitis in our patient is cholelithiasis which was supported by CT scan findings. Therefore, we strongly believe that our patient had pancreatitis which was followed by TTP. The median interval between pancreatitis and developing TTP is estimated to be 3 days^[5], which was also seen in our patient.

Plasma exchange is the mainstay of treatment that has reduced the mortality rate from 90% to as low as 10%^[6], by removing the autoantibody and restoring the ADAMTS13 activity. The number of plasma exchange required to achieve remission is highly variable (range: 0–50), and is longer in patients with detectable inhibitory anti-ADAMTS13 antibodies, which was also reflected in our case^[7]. ADAMTS13 response to early plasma exchange therapy in patients with acquired TTP has prognostic value. Patients whose ADAMTS13 level failed to exceed 10% by Day 7 tended to experience treatment of refractoriness or death^[8]. Our patient's ADAMTS13 activity was 6% after 10 plasma exchanges, signifying refractory TTP and higher risk for morbidity and mortality.

TTP for which treatment with plasma exchange and steroids fails to produce a satisfactory response is considered refractory TTP. There are limited data and consensus on the management of refractory TTP patient. Our patient was started with rituximab on the 2nd week of her stay while continuing plasma exchange and steroid to patient who did not show response. Patients whose disease does not respond to plasma exchange, high-dose steroids and rituximab are rare.

Rituximab, a monoclonal antibody targeting the CD20 antigen that presents on B lymphocytes, is often used in treating refractory TTP with good response rates^[9]. Increasing evidence supports the use of rituximab in cases of refractory TTP and recommends considering rituximab as part of first-line therapy, along with plasma exchange and steroids, in acute TTP with neurological/cardiac pathology^[10].

The patient developed SDH while in the hospital. Any condition that results in a low platelet count could predispose a patient to bleeding, including intracranial hemorrhage. The true incidence of intracranial hemorrhage is unknown in thrombocytopenic patients^[11]. However, the presence of SDH in our patient could be a rare complication of TTP.

Patient's platelet numbers started to rise and sustained above 150 K/mm^3 (with normal range indirect bilirubin and LDH), and ADAMTS13 level increased to 71% after 6–7 weeks of plasma exchange indicating slow response.

4. Conclusion

TTP and acute pancreatitis are associated. However, refractory TTP following acute pancreatitis is rarely mentioned in the literature. We describe a case of a woman of 71 years old who developed TTP after an acute pancreatitis episode, which was refractory to plasma exchange, steroids and rituximab. We would like to emphasize the importance of having higher clinical

suspicion of the association of both disease entities. The role of rituximab as part of the initial treatment along with plasma exchange should be further investigated especially in TTP patient like ours with acute neurological symptoms.

Conflict of interest statement

The authors report no conflict of interest.

References

- [1] Terrell DR, Williams LA, Vesely SK, Lämmle B, Hovinga JA, George JN. The incidence of thrombotic thrombocytopenic purpura-hemolytic uremic syndrome: all patients, idiopathic patients, and patients with severe ADAMTS-13 deficiency. *J Thromb Haemost* 2005; **3**(7): 1432-6.
- [2] Ali MA, Shaheen JS, Khan MA. Acute pancreatitis induced thrombotic thrombocytopenic purpura. *Indian J Crit Care Med* 2014; **18**(2): 107-9.
- [3] Hosler GA, Cusumano AM, Hutchins GM. Thrombotic thrombocytopenic purpura and hemolytic uremic syndrome are distinct pathologic entities. A review of 56 autopsy cases. *Arch Pathol Lab Med* 2003; **127**: 834-9.
- [4] Bhatia M, Wong FL, Cao Y, Lau HY, Huang J, Puneet P, et al. Pathophysiology of acute pancreatitis. *Pancreatology* 2005; **5**: 132-44.
- [5] Swisher KK, Doan JT, Vesely SK, Kwaan HC, Kim B, Lämmle B, et al. Pancreatitis preceding acute episodes of thrombotic thrombocytopenic purpura-hemolytic uremic syndrome: report of five patients with a systematic review of published reports. *Hematologica* 2007; **92**: 936-43.
- [6] Scully M, Hunt BJ, Benjamin S, Liesner R, Rose P, Peyvandi F, et al. Guidelines on the diagnosis and management of thrombotic thrombocytopenic purpura and other thrombotic microangiopathies. *Br J Haematol* 2012; **158**(3): 323-35.
- [7] Coppo P, Wolf M, Veyradier A, Bussel A, Malot S, Millot GA, et al. Prognostic value of inhibitory anti-ADAMTS13 antibodies in adult-acquired thrombotic thrombocytopenic purpura. *Br J Haematol* 2006; **132**(1): 66-74.
- [8] Wu N, Liu J, Yang S, Kellett ET, Cataland SR, Li H, et al. Diagnostic and prognostic values of ADAMTS13 activity measured during daily plasma exchange therapy in patients with acquired thrombotic thrombocytopenic purpura. *Transfusion* 2015; **55**(1): 18-24.
- [9] Sayani FA, Abrams CS. How I treat refractory thrombotic thrombocytopenic purpura. *Blood* 2015; **125**(25): 3860-7.
- [10] Froissart A, Buffet M, Veyradier A, Poullin P, Provôt F, Malot S, et al. Efficacy and safety of first-line rituximab in severe, acquired thrombotic thrombocytopenic purpura with a suboptimal response to plasma exchange. Experience of the French Thrombotic Microangiopathies Reference Center. *Crit Care Med* 2012; **40**(1): 104-11.
- [11] Estcourt LJ, Stanworth SJ, Collett D, Murphy MF. Intracranial haemorrhage in thrombocytopenic haematology patients – a nested case-control study: the InCiTe study protocol. *BMJ Open* 2014; **4**(2): e004199.