

HOSTED BY



ELSEVIER

Contents lists available at ScienceDirect

Journal of Acute Disease

journal homepage: www.jadweb.orgCase report <http://dx.doi.org/10.1016/j.joad.2015.09.001>

A case of acute hangman's fracture

Alexander John Scumpia^{1*}, Daniel Michael Aronovich¹, Megan Dekok², Katrina Lopez³, Donny Perez¹¹Memorial Regional Hospital, Department of Emergency Services, 3501 Johnson Street, Hollywood, FL 33021, USA²University of Florida, Gainesville, FL 32611, USA³Kirkville College of Osteopathic Medicine, 800 W Jefferson Street, Kirkville, MO 63501, USA

ARTICLE INFO

Article history:

Received 11 Mar 2015

Received in revised form 11 Jun 2015

Accepted 5 Sep 2015

Available online 13 Jun 2016

Keywords:

Atypical hangman's fracture

Cervical spine fracture

Motor vehicle collision

ABSTRACT

Hangman's fracture classically results from hyperextension/distraction of the upper cervical spine, causing the axis to break symmetrically across its pedicles or lateral masses and may involve the body of the vertebrae. Interestingly, Starr and Eismont described an atypical hangman's fracture where fracture lines are not parallel and may pass through the foramen transversarium unilaterally from a hyperextension and lateral side-bending injury, as the mechanism described herein. We present a case of an atypical hangman's fracture in a 73-year-old Caucasian female after being involved in a low-speed motor vehicle collision.

1. Introduction

We present a case of an atypical hangman's fracture in a 73-year-old female after being involved in a low-speed motor vehicle collision. Neck pain following motor vehicle collisions is a common chief complaint, especially at our Level-1 Trauma Center. Although most cases do not have serious injury, cervical spine fracture remains high on the clinician's differential diagnoses^[1,2]. This includes, but not limited to, muscle strain/sprain, ligamentous injury, osseous and neurological injury^[3,4]. There are numerous previous studies that have demonstrated the superiority of computed tomography scans to that of plain film X-rays. This remains true when one must consider the patient's complaint, mechanism of injury, physical examination, body habitus limitations (as the case herein) and other limiting factors of plain films^[5,6]. Furthermore, the clinician must be diligent in obtaining immediate spinal immobilization, specialty consultations and additional imaging such as magnetic resonance imaging (MRI) (when warranted)

to significantly reduce the morbidity and mortality in the patients we care for^[3].

2. Case report

The patient had a significant past medical history of type-2 diabetes, hypertension and obesity without a significant past surgical history. She presented to the emergency department (ED) via ambulance with a chief complaint of neck pain. She was a restrained driver and was struck on the front passenger side of her motor vehicle while at a stoplight just prior to arrival. Her car sustained minimal front-right damage and no air bags were deployed, nor did she require a lengthy extrication. In the field, emergency services achieved complete spine immobilization including cervical collar and rigid backboard as well as intravenous access.

Upon ED arrival, the patient's vital signs were as follows: blood pressure 129/63 mmHg, heart rate 75 bpm, respiratory rate of 15 breaths per minute, afebrile and oxyhemoglobin saturation 100% on 2 L nasal cannula. On physical examination, she was short at 157 cm height and at 75 kg obesity (body mass index of 30.2). Additionally, the patient was neurologically intact, without focal deficits or any signs of obvious trauma. The patient stated moderate and sharp left-sided paraspinal muscle tenderness without radiation. No midline tenderness of the cervical spine or step-off sign was appreciated. The rest of the physical examination was non-focal. An

*Corresponding author: Alexander John Scumpia, Memorial Regional Hospital, Department of Emergency Services, 3501 Johnson Street, Hollywood, FL 33021, USA.

Tel: +1 917 371 3796

E-mail: ascumpia@yahoo.com

Peer review under responsibility of Hainan Medical College. The journal implements double-blind peer review practiced by specially invited international editorial board members.

additional peripheral line was placed and cardiac monitoring, pulse oximetry, lactated ringer's infusion were provided. The cervical collar was continued and basic labs including coagulation profile were ordered. Radiographic imaging included portable chest and pelvis X-rays and a CT scan of the cervical spine without contrast.

Plain film X-rays and blood work were non-contributory. However, a CT of cervical spine surprisingly revealed an acute fracture of the axis (C2) involving the lateral arch (Figure 1), mass, body and foramen transversarium on the left (Figure 2), along with the right lateral mass fracture (Figure 3). No significant displacement of bony/ligamentous elements or cord compression was seen. Immediate neurosurgical consultation was obtained. Additional MRI of the head and neck with contrast was ordered through the ED to rule out vertebral artery compromise/dissection. The patient was later admitted to the hospital and discharged home after 2 days. She made an uneventful, non-surgical recovery after wearing a rigid cervical collar for 3 months.

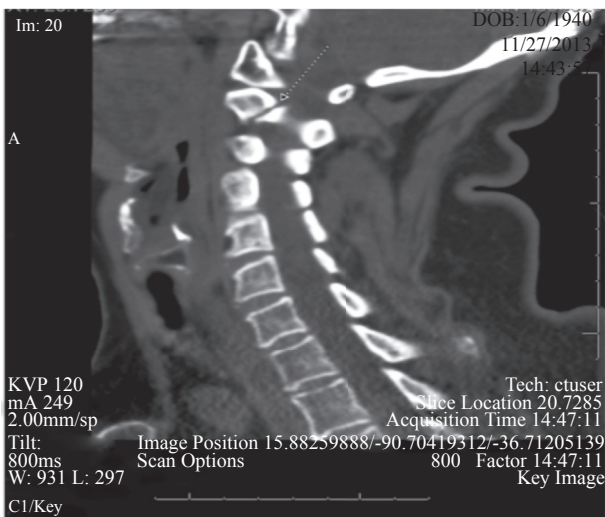


Figure 1. Non-contrast CT (sagittal view) demonstrating left lateral arch fracture (arrow).

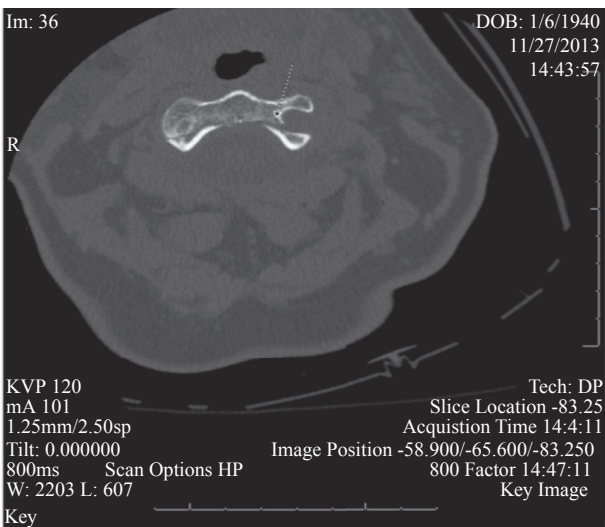


Figure 2. Non-contrast CT (axial view) demonstrating left lateral mass, arch and body C2 fracture with foramen transversarium involvement (arrow).

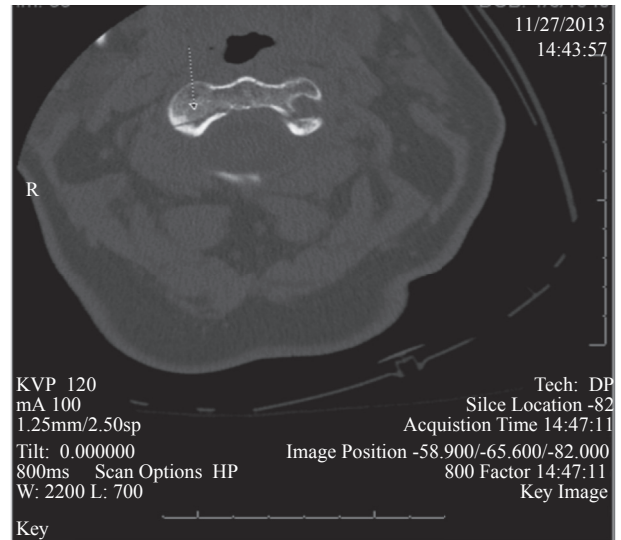


Figure 3. Non-contrast CT (axial view) demonstrating right lateral mass C2 fracture (arrow).

3. Discussion

Starr and Eismont described an atypical hangman's fracture where fracture lines are not parallel and may pass through the foramen transversarium unilaterally from a hyperextension and lateral side-bending injury, as the mechanism described herein^[3]. Interestingly, this atypical hangman's fracture may have a 33% incidence of paralysis, in contrast to a typical hangman's fracture where neurological deficits are not evident^[3,4,7]. Classically, the hangman's fracture, albeit from execution/suicide or trauma (motor vehicle collisions/athletic trauma *etc.*) is due to hyperextension/distraction with axial loading of the upper cervical spine, causing the axis to break symmetrically across its pedicles or lateral masses^[2,5,8,9]. Non-surgical management with immediate external immobilization (8–14 weeks) via rigid cervical collar or halo (if warranted by neurosurgery) produces adequate reduction in 97%–100% cases and results in osseous fusion rates of 93%–100%^[1,2,6]. This case illustrates the importance of high suspicion of injury secondary to clinical gestalt, mechanism of injury, and early specialty consultation. It additionally demonstrates the vitality of appropriate radiographic imaging, in this case of CT/MRI vs. X-ray in an obese female where plain films may have missed possible neurologic/osseous/vascular injuries.

Conflict of interest statement

The authors report no conflict of interest.

References

- [1] Sonntag VK, Hadley MN. Nonoperative management of cervical spine injuries. *Clin Neurosurg* 1988; **34**: 630-49.
- [2] Rehtine GR 2nd. Nonoperative management and treatment of spinal injuries. *Spine (Phila Pa 1976)* 2006; **31**: S22-7.
- [3] Starr JK, Eismont FJ. Atypical hangman's fractures. *Spine (Phila Pa 1976)* 1993; **18**(14): 1954-7.
- [4] Effendi B, Roy D, Cornish B, Dussault RG, Laurin CA. Fractures of the ring of the axis. A classification based on the analysis of 131 cases. *J Bone Joint Surg Br* 1981; **63-B**: 319-27.

- [5] Williams TG. Hangman's fracture. *J Bone Joint Surg Br* 1975; **57**: 82-8.
- [6] Coric D, Wilson JA, Kelly DL Jr. Treatment of traumatic spondylolisthesis of the axis with nonrigid immobilization: a review of 64 cases. *J Neurosurg* 1996; **85**: 550-4.
- [7] Chaudhary SB, Martinez M, Shah NP, Vives MJ. Traumatic atlantoaxial dislocation with hangman fracture. *Spine J* 2015; **15**: e15-8.
- [8] Rayes M, Mittal M, Rengachary SS, Mittal S. Hangman's fracture: a historical and biomechanical perspective. *J Neurosurg Spine* 2011; **14**: 198-208.
- [9] Kukreja S, Kalakoti P, Murray R, Nixon M, Missios S, Guthikonda B, et al. National trends of incidence, treatment, and hospital charges of isolated C-2 fractures in three different age groups. *Neurosurg Focus* 2015; **38**(4): E19.