

Case report <http://dx.doi.org/10.1016/j.joad.2015.11.009>

Case of spontaneous tubal stump pregnancy after adnexectomy

Konrad Futyma*, Andrzej Wróbel, Aleksandra Filipczak, Tomasz Rechberger

2nd Department of Gynecology, Medical University of Lublin, Lublin, Poland

ARTICLE INFO

Article history:

Received 8 Apr 2015

Received in revised form 19 Jun 2015

Accepted 15 Nov 2015

Available online 8 Jan 2016

Keywords:

Ectopic pregnancy

Fallopian tube

Tubal stump

Adnexectomy

ABSTRACT

Ectopic pregnancy is a significant problem in women of childbearing potential and affects up to 2% of them. The most common ectopic pregnancy localization is the ampullary area of the Fallopian tube. Patient with spontaneous ectopic pregnancy located in the tubal stump after an ipsilateral adnexectomy performed with a laparotomy due to mucinous cystadenoma was operated by laparoscopy. Remnant of Fallopian tube with ectopic pregnancy was removed. The most important lecture from this case is when adnexectomy or salpingectomy is performed, it should be done in the isthmic part, without leaving any remnant.

1. Introduction

Ectopic pregnancy (EP) is a significant problem in women of childbearing potential. The incidence of EP is up to 2% of all reported pregnancies and the incidence has increased because of the greater prevalence of assisted reproductive technologies (ART), other surgical procedures on genital tract, sexually transmitted diseases and delayed childbearing^[1,2]. An EP can be localized at the different pelvic and abdominal locations but the most common site for EP occurrence is the ampullary area of the tubular portion^[3]. EP in tubal stump after salpingectomy has been sporadically reported and usually it concerns the patients after ART procedures^[2,4,5]. Repeat ectopic pregnancy occurred is observed in up to 8% of women after salpingotomy and in 5% of women after salpingectomy^[6].

2. Case report

In this article, we report a case of a 30-year-old woman, gravida two, para one, with a spontaneous ectopic pregnancy that was located in the remnant tube after an ipsilateral adnexectomy performed with a laparotomy due to mucinous cystadenoma in 2012. She was admitted at the 2nd Department of Gynecology of Medical University of Lublin on October 30, 2014 with a mild

abdominal pain of two days' duration, and a positive pregnancy test (β -hCG level on admission = 3 046 mIU/mL and the next day 3 274 mIU/mL). On pelvic examination, the cervix was closed and the uterus was mobile and had normal size. On the transvaginal ultrasonography, uterus was empty with homogenous texture and endometrial thickness was 16.75 mm. GS without fetus was noted on the right side of the uterus (Figure 1).

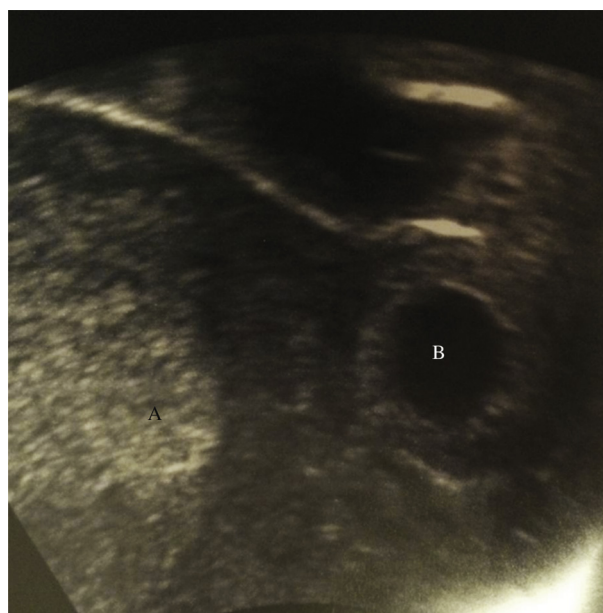

Figure 1. Transvaginal scan.
A: Uterine cavity; B: Ectopic pregnancy structures in tubal stump.

*Corresponding author: Konrad Futyma, 2nd Department of Gynecology, Medical University of Lublin, Lublin, Poland.

Tel: +48 81 7244268

Fax: +48 81 7244849

E-mail: futymakonrad@mp.pl

Peer review under responsibility of Hainan Medical College.

A corpus luteum was noted in the left ovary. We did not find free fluid in the Douglas pouch. Hematological examination showed: WBC 9.94×10^3 cells/ μ L, RBC 4.13×10^6 cells/ μ L, hemoglobin 12.8 g/dL, and hematocrit 37.6%.

Laparoscopy with general anesthesia was performed. Intra-umbilical opening with laparoscopic optics had been introduced and two accessory openings on the left and right side lateral to the epigastric vessels. Ectopic pregnancy was found in the right tubal stump, which was removed (Figures 2 and 3). The postoperative course proved normal, with discharge on the third day, followed by outpatient controls. The pathology report

confirmed the presence of chorionic villi, trophoblastic tubal implantation.

3. Conclusions

Considering different theories and causes of ipsilateral ectopic pregnancy, in this case, there is no other possibility except that the oocyte ovulated by the left ovary fecundated in the left tube passed through the uterine cavity and implanted in the right tubal stump. This case is the example that the prevention of pregnancy in the tubal remnants after almost complete resection of the fallopian tube during adnexectomy is impossible. Even if the remaining tubal stump is closed and covered by peritoneum, it can be a possible place for ectopic pregnancy. We have to remember that a delay in diagnosis in this acute condition could cause serious complications including life-threatening situation. The most important conclusion is that when adnexectomy or salpingectomy is performed, it should be done in the isthmic part, without leaving any remnant.

Conflict of interest statement

The authors report no conflict of interest.

References

- [1] Perkins KM, Boulet SL, Kissin DM, Jamieson DJ, National ART Surveillance (NASS) Group. Risk of ectopic pregnancy associated with assisted reproductive technology in the United States, 2001-2011. *Obstet Gynecol* 2015; **125**: 70-8.
- [2] Stulberg DB, Cain LR, Dahlquist I, Lauderdale DS. Ectopic pregnancy rates and racial disparities in the Medicaid population, 2004-2008. *Fertil Steril* 2014; **102**: 1671-6.
- [3] Bouyer J, Coste J, Fernandez H, Pouly JL, Job-Spira N. Sites of ectopic pregnancy: a 10-year population-based study of 1800 cases. *Hum Reprod* 2002; **17**: 3224-30.
- [4] Ko PC, Liang CC, Lo TS, Huang HY. Six cases of tubal stump pregnancy: complication of assisted reproductive technology? *Fertil Steril* 2011; **95**: 2432-4.
- [5] Sturlese E, Retto G, Palmara V, De Dominicis R, Lo Re C, Santoro G. Ectopic pregnancy in tubal remnant stump after ipsilateral adnexectomy for cystic teratoma. *Arch Gynecol Obstet* 2009; **280**: 1015-7.
- [6] Mol F, van Mello NM, Strandell A, Strandell K, Jurkovic D, Ross J, et al. Salpingotomy versus salpingectomy in women with tubal pregnancy (ESEP study): an open-label, multicentre, randomised controlled trial. *Lancet* 2014; **383**: 1483-9.

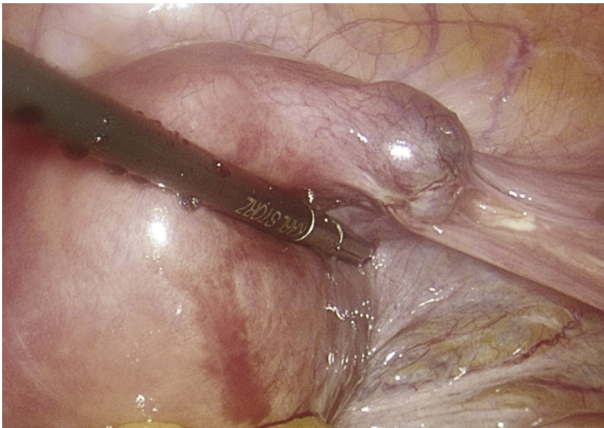


Figure 2. Laparoscopic view of tubal stump pregnancy.

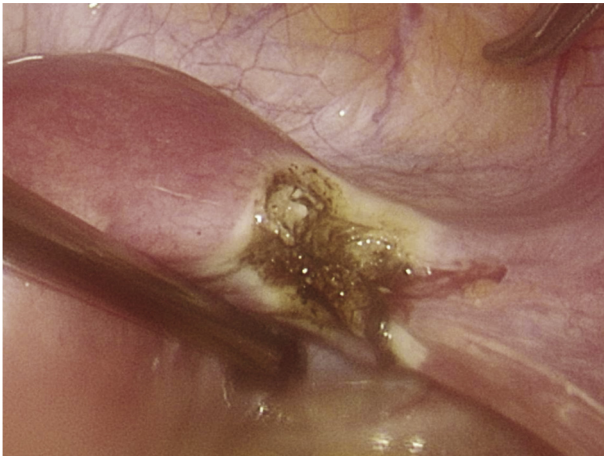


Figure 3. Operated site after complete excision.