

HOSTED BY



ELSEVIER

Contents lists available at ScienceDirect

Journal of Acute Disease

journal homepage: www.jadweb.orgCase report <http://dx.doi.org/10.1016/j.joad.2015.06.013>

Acute Mallory–Weiss syndrome after cardiopulmonary resuscitation by health care providers in the emergency department

Dae Hee Kim¹, Dong Yoon Rhee¹, Seon Hee Woo^{1*}, Woon Jeong Lee¹, Seung Hwan Seol¹, Won Jung Jeong²¹Department of Emergency Medicine, Incheon St. Mary's Hospital, College of Medicine, the Catholic University of Korea, Incheon, Republic of Korea²Department of Emergency Medicine, St. Vincent's Hospital, College of Medicine, the Catholic University of Korea, Suwon, Republic of Korea

ARTICLE INFO

Article history:

Received 14 Feb 2015

Received in revised form 21 May 2015

Accepted 1 Jun 2015

Available online 29 Jul 2015

ABSTRACT

A report of a 62-year-old female patient with severe Mallory–Weiss syndrome after successful cardiopulmonary resuscitation (CPR) by health care providers in the emergency department is presented. The bleeding continued for five days, and the patient's total blood loss was estimated to be approximately 3000 mL. After 7 days, the patient died due to respiratory distress syndrome. Severe Mallory–Weiss syndrome after CPR may occur and should be considered as a potentially serious complication after CPR.

Keywords:

Death

Cardiac

Complications

Mallory–Weiss syndrome

Cardiopulmonary resuscitation

1. Introduction

Gastric mucosal tear, or Mallory–Weiss tear, is a rare complication following cardiopulmonary resuscitation (CPR) in the emergency department in Korea. Distension of the stomach due to mouth-to-mouth ventilation or bag-mask ventilation during CPR can increase gastric pressure^[1]. Additionally, chest compressions during basic life support in a cardiac arrest patient can increase intragastric pressure and induce gastric mucosal tear or Mallory–Weiss syndrome^[2].

These complications rarely occur, but when they do, they can be life-threatening in the resuscitated patients. A case of a severe Mallory–Weiss tear following CPR is presented in this paper.

2. Case report

A 62-year-old woman with no prior medical history was admitted to the emergency department after cardiac arrest caused

by midazolam sedation and lidocaine injection for blepharoplasty at a private clinic. Bag-mask ventilation and compression were continued during the 7-min transport to the emergency department by health care providers. Upon arrival at the emergency department, the patient's initial rhythm was asystole, and cardiac massage was continued. Return of spontaneous circulation was achieved after a further 8-min advanced life support and injection of a total of 3 mg epinephrine. During endotracheal intubation, no blood was found in the mouth or pharynx. After resuscitation, her initial blood pressure was 140/110 mmHg, and her pulse rate was 94 beats per minute. The heart rhythm was sinus tachycardia with a right bundle branch block. Physical examination showed a 3 cm open wound of the right eyelid and abdominal distension. After resuscitation, a 16 F nasogastric tube was inserted to decompress the patient's distended abdomen. No resistance during the advancement of the nasogastric tube was felt during the first attempt. When gastric fluid drained after successful insertion of the nasogastric tube, fresh blood flowed out of the tube. A chest radiograph was immediately performed. It showed insertion of the nasogastric tube into the stomach (Figure 1).

A digital rectal examination showed no bloody stool. The patient had no recent history of vomiting or upper gastrointestinal bleeding. Her initial hemoglobin level was measured as

*Corresponding author: Seon Hee Woo, M.D., Department of Emergency Medicine, Incheon St. Mary's Hospital, College of Medicine, the Catholic University of Korea, #665-8 Bupyeong 6-dong, Bupyeong-gu, Incheon, 403-720, Republic of Korea.

Tel: +82 32 280 6116

E-mail: drme@catholic.ac.kr

Peer review under responsibility of Hainan Medical College.

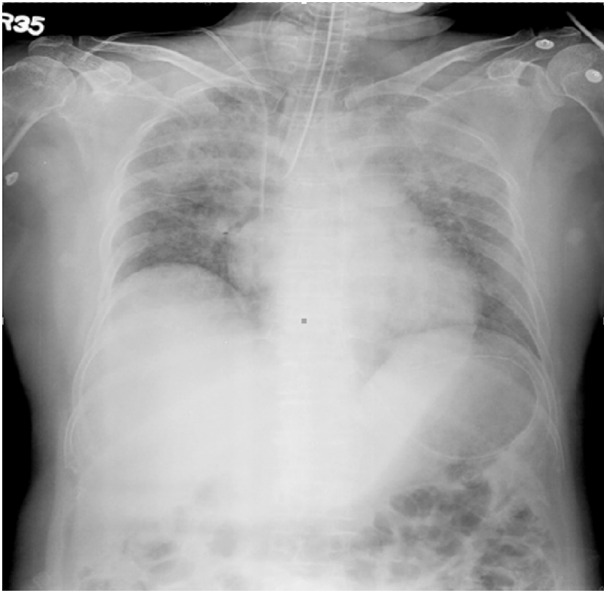


Figure 1. Initial chest X-ray of the patient showing insertion of the nasogastric tube into the stomach.

12.6 g/dL. Emergency endoscopy was performed, and she was diagnosed with a severe Mallory–Weiss tear with a freshly bleeding lesion at the gastro-esophageal junction (Figure 2). After 1 h, her hemoglobin level was 9.5 g/dL. Bleeding continued, and the total amount of blood drainage on the first day was 1120 mL. On the second day, 350 mL of blood continued to flow out of the nasogastric tube. Surgical treatment for continuous bleeding was considered but not performed because of the patient's unstable vital signs and complications of pneumonia.

On the fifth day, bleeding from the nasogastric tube stopped, and the patient's total blood loss was estimated to be approximately 3000 mL. After 7 days, the patient died due to respiratory distress syndrome.

3. Discussion

Mallory–Weiss syndrome is a rare complication after CPR. Mallory–Weiss syndrome represents approximately 3%–10% of cases of upper gastrointestinal bleeding, and it frequently heals spontaneously^[3]. It is caused by a sudden increase in intragastric pressure, which can be caused by nausea, vomiting or severe coughing, and occurred on the lesser curved side of the stomach and the esophagogastric junction^[4].

Previous reports have indicated that the probability of gastric rupture is 0.1%^[5]; however, the frequency of Mallory–Weiss syndrome due to gastric mucosal injury might be higher than that due to gastric rupture. In most cases, incorrect hyperventilation during CPR has been cited as the main cause of gastric rupture and mucosal injury^[1,6,7]. Hyperventilation during mouth-to-mouth ventilation, distension of the stomach due to bag-mask ventilation, and chest compressions can all lead to higher intragastric pressure. The increased pressure can lead to a gastric mucosal tear. Factors of gastric injury after CPR were reported to include the patient's position (*i.e.* non-supine), the use of the cardio pump, the location of arrest (*i.e.* outside the hospital), and the paramedics' CPR technique^[1,2,6–8].

Yet, in this case, bag-mask ventilation combined with chest compressions were performed for approximately 10 min by health care providers; CPR without endotracheal intubation was performed for a relatively short time. Yet, a chest X-ray after return of spontaneous circulation showed stomach distension and the nasogastric tube insertion into the stomach.

Thus, excessive bag-mask ventilation without endotracheal intubation and chest compressions by the paramedics or health care providers might lead to dilatation of the stomach and increased intragastric pressure, which may subsequently induce the Mallory–Weiss tear.

In some cases, complications associated with nasogastric tube insertion have been reported, including intracranial malposition, tube knotting around a tracheal tube, misplacement

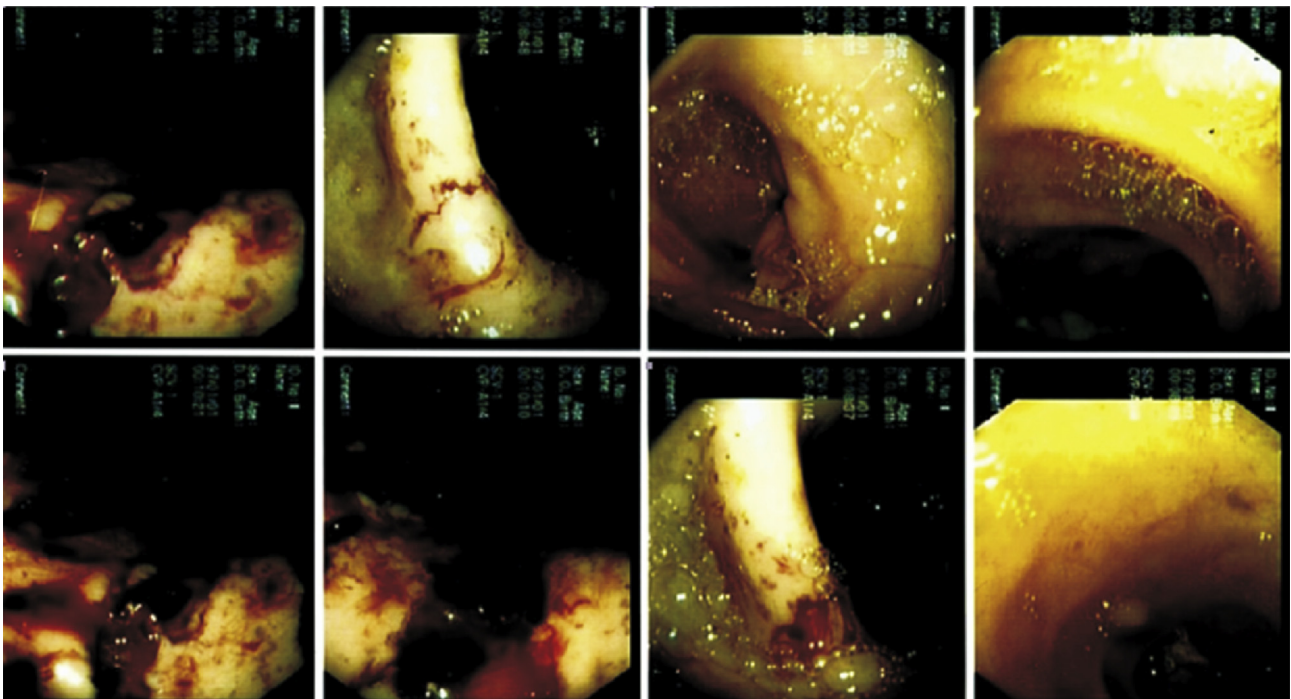


Figure 2. Emergency endoscopy showing severe Mallory–Weiss tear in the patient.

into the bronchus causing pneumothorax, arterial-esophageal fistula, and bladder perforation^[9–11].

Yet, the Mallory–Weiss syndrome in this case was not thought to be caused by a nasogastric tube because of the smooth insertion of nasogastric tube on the first attempt and the immediate draining of a large amount of blood after its insertion. A previous study reported the rupture of a cadaver's stomach after mouth-to-mouth ventilation and the gastric rupture following bag-valve-mask ventilation^[12,13]. In this case, we believe that hyperventilation during the bag-mask ventilation caused the distension of the stomach, and chest compressions without endotracheal intubation might lead to higher intragastric pressure.

4. Conclusions

Generally, Mallory–Weiss syndrome heals spontaneously, but it can cause severe damage in an unstable post-resuscitation patient. Thus, excessive bag-mask ventilation during CPR should be avoided, and severe Mallory–Weiss syndrome after CPR should be considered in the emergency department. Therefore, early recognition of gastric mucosal injury after CPR and the active management of complications are necessary to ensure a positive patient outcome.

Conflict of interest statement

The authors report no conflict of interest.

References

- [1] Spoomans I, Van Hoorenbeeck K, Balliu L, Jorens PG. Gastric perforation after cardiopulmonary resuscitation: review of the literature. *Resuscitation* 2010; **81**(3): 272-80.
- [2] Buschmann CT, Tsokos M. Frequent and rare complications of resuscitation attempts. *Intensive Care Med* 2009; **35**(3): 397-404.
- [3] Yin A, Li Y, Jiang Y, Liu J, Luo H. Mallory–Weiss syndrome: clinical and endoscopic characteristics. *Eur J Intern Med* 2012; **23**(4): e92-6.
- [4] Kinoshita Y, Furuta K, Adachi K, Amano Y. Asymmetrical circumferential distribution of esophagogastric junctional lesions: anatomical and physiological considerations. *J Gastroenterol* 2009; **44**(8): 812-8.
- [5] Paradis NA, Halperin HR, Nowak RM. *Cardiac arrest: the science and practice of resuscitation medicine*. Baltimore: Williams & Wilkins; 1996.
- [6] Reiger J, Eritscher C, Laubreyter K, Trattnig J, Sterz F, Grimm G. Gastric rupture—an uncommon complication after successful cardiopulmonary resuscitation: report of two cases. *Resuscitation* 1997; **35**(2): 175-8.
- [7] Da Broi U, Moreschi C, Castellani M, Antonella B. Gastric mucosal tears and wall micro perforations after cardiopulmonary resuscitation in a drowning case. *J Forensic Leg Med* 2009; **16**(1): 24-6.
- [8] Reichardt JA, Casey GD, Krywko D. Gastric rupture from cardiopulmonary resuscitation or seizure activity? A case report. *J Emerg Med* 2010; **39**(3): 309-11.
- [9] Isik A, Firat D, Peker K, Sayar I, Idiz O, Soytürk M. A case report of esophageal perforation: complication of nasogastric tube placement. *Am J Case Rep* 2014; **15**: 168-71.
- [10] Hanna AS, Grindle CR, Patel AA, Rosen MR, Evans JJ. Inadvertent insertion of nasogastric tube into the brain stem and spinal cord after endoscopic skull base surgery. *Am J Otolaryngol* 2012; **33**(1): 178-80.
- [11] Hensel M, Marnitz R. [Pneumothorax following nasogastric feeding tube insertion: case report and review of the literature]. *Anaesthesist* 2010; **59**(3): 229-32. 234. German.
- [12] Smally AJ, Ross MJ, Huot CP. Gastric rupture following bag-valve-mask ventilation. *J Emerg Med* 2002; **22**(1): 27-9.
- [13] Cassebaum WH, Carberry DM, Stefko P. Rupture of the stomach from mouth-to-mouth resuscitation. *J Trauma* 1974; **14**(9): 811-4.