



HOSTED BY



ELSEVIER

Contents lists available at ScienceDirect

Journal of Acute Disease

journal homepage: www.jadweb.orgPharmacology <http://dx.doi.org/10.1016/j.joad.2015.06.008>

Research on garlic capsule and selenium-vitamin A, vitamin B, vitamin C applied in therapy of acute hepatocellular damage in a rat model

Jacob Kehinde Akintunde*, Olakunle Enock Bolarin

Drug Metabolism and Molecular Environmental Toxicology Research Laboratory, Biochemistry Unit, Department of Biosciences and Biotechnology, College of Pure and Applied Sciences, Kwara State University, Malete, P.M.B 1530, 340001, Ilorin, Nigeria

ARTICLE INFO

Article history:

Received 1 Jun 2015
 Received in revised form 5 Jun,
 2nd revised form 12 Jun 2015
 Accepted 15 Jun 2015
 Available online 5 Aug 2015

Keywords:

Lisinopril
 Garlic capsule
 Selenium
 Angiotensin-converting enzyme
 inhibitors
 Sub-acute
 Hepatic cell damage
 Adenosine triphosphate
 Rat

ABSTRACT

Objectives: To evaluate the toxicity of lisinopril in liver of male rats and its reversal effect of garlic capsule (GAR) and selenium-vitamin A, vitamin B, vitamin C (SACE).

Methods: Thirty five adult male wistar rats were randomly assigned into 5 groups of 7 animals per group. Group I serves as the control, animals in Groups II, III, IV and V received 28 mg/kg body weight of lisinopril via oral route. Group III was co-treated with GAR at therapeutic dose of 250 mg/kg body weight per day. Group IV was co-treated with SACE at dose of 500 mg/kg body weight. Lastly, group V was co-treated with GAR and SACE at doses of 250 and 500 mg/kg body weight respectively, and the experiment last for 8 days.

Results: Administration of lisinopril caused systemic toxicity in liver as well as adverse histopathologic changes in the tested tissue. While GAR and SACE significantly ($P < 0.05$) reversed the toxic effects induced by lisinopril.

Conclusions: Collectively, the results suggest that therapeutic dose of lisinopril elicits toxicity in male rats through induction of oxidative damage and depletion of cellular adenosine triphosphate. The reversal effects of GAR and SACE during lisinopril treatment suggest that these antioxidants may find clinical application in cellular damage involving ROS and adenosine triphosphate.

1. Introduction

Lisinopril is one of the antihypertensive medications that belong to the angiotensin-converting enzyme (ACE) inhibitor group. The ACE inhibitors are considered first line drugs for the therapy of hypertension and are considered particularly helpful in preventing the renal complications of diabetes and high blood pressure^[1]. ACE inhibitors are sometimes used even in patients with relatively normal blood pressure for treatment of heart failure and prevention of diabetic neuropathy^[2,3]. Lisinopril works by inhibiting a chemical process involving high amount of salt and water in the body. It has been reported that less salt and water decrease the blood volume, thereby making blood arteries and veins flow smoother^[4-6]. Lisinopril,

paradigm of ACE inhibitors acts on the mechanism that narrows blood vessels, so that by blocking it, lisinopril causes blood vessels to relax, allowing more blood to flow in the body^[7,8]. However, patients who suffer from hypertension can bring their blood pressure back to normal by recommending the drug. This is imperative because excessive pressure will damage the blood vessels and lead to cardiovascular diseases (e.g. heart attack). Lisinopril is a commonly prescribed ACE inhibitor and this type of medication is commonly used to decrease blood pressure by the renin-angiotensin-aldosterone system^[9,10]. These inhibitors block the conversion of angiotensin I to angiotensin II, which ultimately leads to the reduction of blood pressure^[11]. Other enzymes besides that which converts angiotensin I to II may also be inhibited. This may account for some of the side effects of the ACE inhibitors.

Lisinopril was approved for use by the Food and Drug Administration in the United States and is currently one of the most widely prescribed medications in clinical practice, with more than 60 million prescriptions filled yearly^[12-14]. Despite its wide scale use, cases of clinically apparent acute liver injury and deaths attributed to lisinopril complications have been

*Corresponding author: Jacob Kehinde Akintunde, Drug Metabolism and Molecular Environmental Toxicology Research Laboratory, Biochemistry Unit, Department of Biosciences and Biotechnology, College of Pure and Applied Sciences, Kwara State University, Malete, P.M.B 1530, 340001, Ilorin, Nigeria.

Fax: +234 08064156056

E-mail: akintundejacob@yahoo.com

Peer review under responsibility of Hainan Medical College.

published^[15,16]. Strikingly, lisinopril have been associated with instances of acute liver injury after 1–4 years of therapy, a distinctly unusual pattern of drug induced liver injury^[17–19]. Other common side effects of lisinopril therapy include dizziness, fatigue, headache, cough, gastrointestinal upset and skin rash^[20,21]. In addition, previous study had shown immunological manifestations (rash, fever, eosinophilia) in patients treated with lisinopril, in which; they develop no auto-antibodies^[22]. Lisinopril might cause mild hepatitis^[23,24] and it was also reported that lisinopril therapy showed sexual dysfunction in hypertensive male patients therapeutically administered^[13,25].

Several xenobiotics enter the body through gastrointestinal tract and after absorption are transported by the hepatic portal vein to the liver; thus the liver is the first organ perfused by drugs that are absorbed in the gut. To date, research has largely concentrated on hepatic cells, since the liver plays a major role in the metabolism of xenobiotics and consequently the primary target of most toxic responses. More so, GAR and selenium ACE might be useful in treatment of liver damage. Thus, the aim of the present study was (a) to validate the evidence whether therapeutic dose of lisinopril induces hepatotoxicity in rats (b) to investigate the combination therapy of garlic capsule (GAR) and selenium-vitamin A, vitamin B, vitamin C (SACE) against lisinopril sub-acute induced hepatic damage (c) and possibly to validate the underlying biochemical mechanisms of lisinopril toxicity in liver as well as its prevention by GAR and/SACE.

2. Materials and methods

2.1. Chemicals and reagents

Lisinopril, GAR, SACE, epinephrine, glutathione (GSH), 5,5-dithio-bis-2-nitrobenzoic acid, hydrogen peroxide, trichloroacetic acid and thiobarbituric acid were purchased from Sigma (St Louis, MO, USA). All other reagents were of analytical grade and were obtained from the British Drug Houses (Poole, Dorset, UK).

2.2. Experimental protocol

Thirty five adult male wistar rats weighing approximately 200–220 g obtained from the Department of Biochemistry, University of Ilorin, Nigeria were randomly assigned into 5 groups of 7 animals per group. They were housed in a plastic suspended cage placed in a well ventilated rat house, provided rat pellets and water *ad libitum*, and subjected to a natural photoperiod of 12 h light and 12 h dark cycle. All the animals received humane care according to the criteria outlined in the Guide for the Care and Use of Laboratory Animals prepared by the National Academy of Science and published by the National Institute of Health. Ethic regulations have been followed in accordance with National and institutional guidelines for the protection of animal welfare during experiments^[26].

Rats in Group I served as control and were administered distilled water. Animals in Groups II, III, IV and V received 28 mg/kg body weight of lisinopril via oral route. Group III was co-treated with GAR at therapeutic dose of 250 mg/kg body weight per day. Group IV was co-treated with ACE at dose of 500 mg/kg body weight. Lastly, group V was co-treated with GAR and ACE at doses of 250 and 500 mg/kg body weight respectively, and the experiment last for a week. The animals

were fasted overnight and sacrificed by decapitation 24 h after the last treatment, livers were removed and cleared of adhering tissues, washed in ice-cold 1.15% potassium chloride and dried with blotting paper.

2.3. Biochemical assay

The livers were homogenized in 50 mmol/L Tris–HCl buffer (pH 7.4) containing 1.15% KCl and the homogenate was centrifuged at 10000 r/min for 15 min at 4 °C. The supernatant was collected for the estimation of catalase activity using hydrogen peroxide (H₂O₂) as substrate according to the method of Clairborne^[27]. Also, H₂O₂ level was estimated using the method described by Clairborne^[27]. Superoxide dismutase (SOD) activity was determined by measuring the inhibition of autoxidation of epinephrine at pH 10.2 at (30 ± 1) °C according to Misra and Fridovich^[28]. Protein concentration was determined by the method of Lowry *et al.*^[29].

2.4. Reduced GSH assay

GSH was determined at 412 nm using the method described by Jollow *et al.*^[30].

2.5. Lipid peroxidation assay

Lipid peroxidation was quantified as malondialdehyde (MDA) according to the method described by Ohkawa *et al.*^[31] and expressed as μmol/mg tissue.

2.6. Lactate dehydrogenase (LDH) assay

The liver homogenate was assayed for LDH activity using commercially available kit (Randox Laboratories, UK). Assay was carried out according to the manufacturer's instructions^[32].

2.7. Histopathological evaluation

The livers were fixed in 10% formalin. They were directly dehydrated in a graded series of ethanol and embedded in paraffin. Thin sections, 5–6 μm, were cut by using a microtome, mounted on albumenized glass slides and stained with eosin and hematoxylen. Morphological examination of liver was done by using an ocular micrometer scale under light microscope.

2.8. Statistical analysis

The results of the replicates were pooled and expressed as mean ± SE. One-way ANOVA was used to analyze the results and Duncan multiple tests was used for the *post hoc*^[33]. SPSS 17.0 for windows was used for the analysis and the least significance difference was accepted at *P* < 0.05.

3. Results

3.1. Hepatic biochemical indices

The effect of lisinopril, lisinopril plus GAR, lisinopril plus SACE, and lisinopril plus SACE plus GAR on hepatic biochemical indices were presented in Figures 1–3. Lisinopril

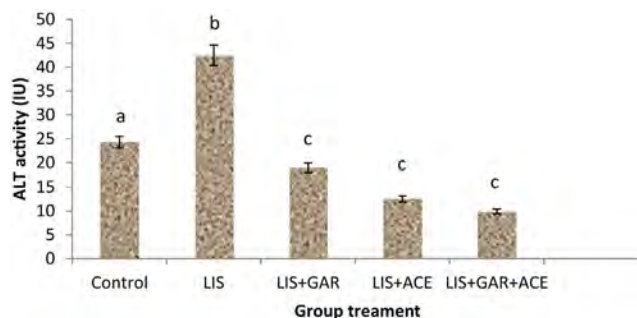


Figure 1. Effect of GAR and SACE on lisinopril-induced toxicity on ALT activity. Results are expressed as mean \pm SEM; $n = 7$; Bars with different superscript letters are significant ($P < 0.05$) different; LIS: Lisinopril.

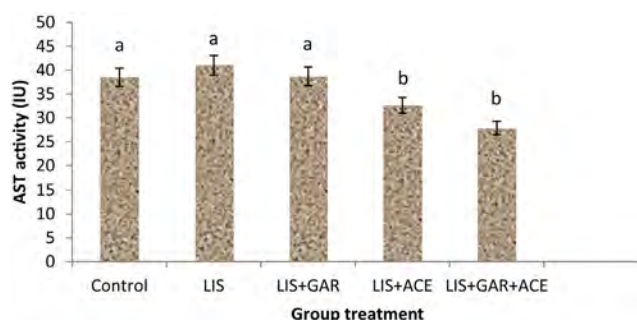


Figure 2. Effect of GAR and SACE on lisinopril-induced toxicity on AST activity. Results are expressed as mean \pm SEM; $n = 7$; Bars with different superscript letters are significant ($P < 0.05$) different; LIS: Lisinopril.

significantly ($P < 0.05$) increased the plasma activity of alanine aminotransferase (ALT) by 75% compared with the control group (Figure 1). Co-administrations of lisinopril with GAR, SACE and GAR plus SACE significantly ($P < 0.05$) decreased the activity of ALT by 57%, 71% and 83.3% respectively (Figure 1). In addition, lisinopril caused an increase in the plasma activity of aspartate aminotransferase (AST) when compared with the control group (Figure 2). Co-treatment of lisinopril with SACE or GAR plus SACE significantly ($P < 0.05$) decreased the activity of this enzyme by 22.5% and 37.5% respectively (Figure 2). Similarly, co-administration with GAR caused a decrease in the activity of plasma AST (Figure 2). Furthermore, group of animals treated with lisinopril markedly ($P < 0.05$) increased the plasma activity of alkaline phosphatase (ALP) (Figure 3) by 54.2%, when compared with the control

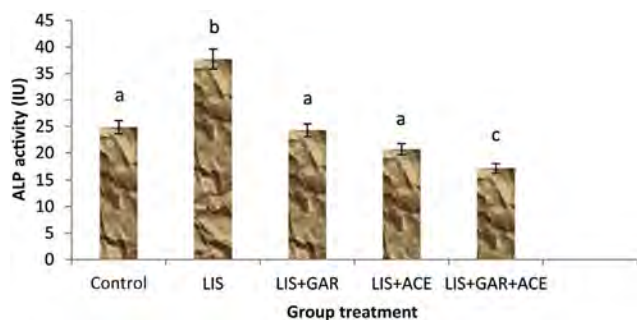


Figure 3. Effect of GAR and SACE on lisinopril-induced toxicity on ALP activity. Results are expressed as mean \pm SEM; $n = 7$; Bars with different superscript letters are significant ($P < 0.05$) different; LIS: Lisinopril.

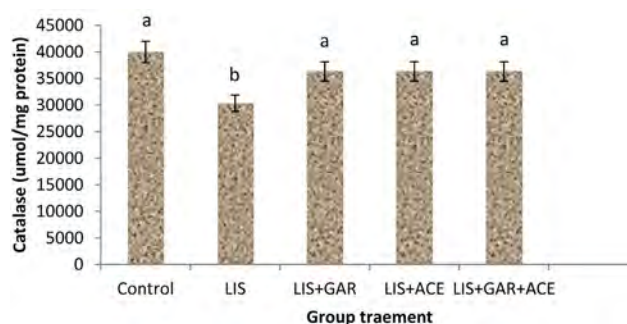


Figure 4. Effect of GAR and SACE on lisinopril-induced toxicity on activity of catalase in liver cells. Results are expressed as mean \pm SEM; $n = 7$; Bars with different superscript letters are significant ($P < 0.05$) different; LIS: Lisinopril.

group. Conversely, co-management of lisinopril with GAR, SACE and GAR plus SACE significantly ($P < 0.05$) decreased the activity of ALP by 37.5%, 48.6%, and 59.5% respectively (Figure 3).

3.2. Antioxidant status in the liver

In order to explore the possibility that lisinopril interferes with antioxidant defense system and thereby induces oxidative damage to rat liver, the antioxidant level and markers of oxidative stress were evaluated. The activity of catalase in the post-mitochondrial fraction of rat liver was decreased significantly in the lisinopril-treated rats ($P < 0.05$) by 25% (Figure 4). Co-administration of GAR or SACE significantly ($P < 0.05$) increased the activity of catalase by 20% and 16.67%, respectively (Figure 4). Correspondingly, co-treatment with GAR plus ACE increased the activity of catalase by 13.3%. The activity of SOD decreased significantly by 88.2% in the animals treated with lisinopril compared with the corresponding group of control animals (Figure 5). This decrease was prevented by 400% on co-administration with SACE. Treatment with GAR did not show reversal effect on the activity of SOD (Figure 5). Whereas, co-management with GAR plus SACE remarkably ($P < 0.05$) reversed the activity of SOD by 561.8% increase (Figure 5).

3.3. Markers of oxidative damage

Administration of lisinopril caused a significant decrease ($P < 0.05$) by 60% in liver GSH, antioxidant protein, when compared with the corresponding group of control animals

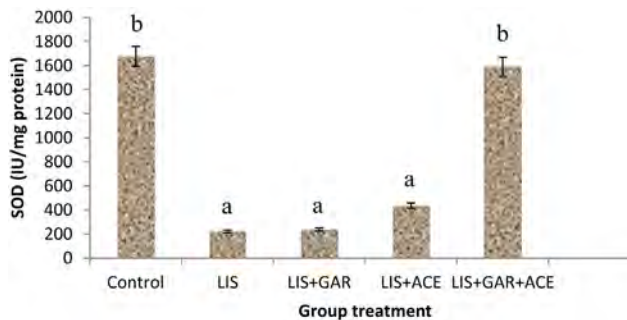


Figure 5. Effect of GAR and SACE on lisinopril-induced toxicity on activity of SOD in the liver. Results are expressed as mean \pm SEM; $n = 7$; Bars with different superscript letters are significant ($P < 0.05$) different; LIS: Lisinopril.

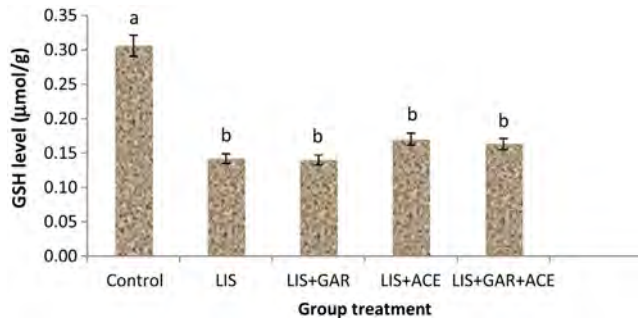


Figure 6. Effect of GAR and SACE on lisinopril-induced toxicity on GSH level of the liver cells. Results are expressed as mean \pm SEM; $n = 7$; Bars with different superscript letters are significant ($P < 0.05$); LIS: Lisinopril.

(Figure 6). Whereas co-treatment of lisinopril with SACE or GAR plus SACE non-significantly ($P > 0.05$) elevated the GSH to normal by 50%. GAR administration did not significantly modulate the level of this protein following treatment with lisinopril. The levels of MDA, a maker of lipid peroxidation, in the liver increased significantly ($P < 0.05$) in rats treated with lisinopril by 700%, relative to the control group (Figure 7). Increased MDA levels were markedly ($P < 0.05$) reversed by the administration of both GAR and SACE to the lisinopril-treated rats (Figure 7) by 62% and 25% respectively. Also, co-treatment with GAR plus SACE remarkably ($P < 0.05$) reversed the increased oxidative damage (MDA level) by 43.8%.

3.4. Cellular adenosine triphosphate (ATP) in the liver

Lisinopril-treated group of animals significantly ($P < 0.05$) depleted the activity of LDH, key marker attributed to the production of ATP in the liver by 26.67%, when compared to the corresponding control group (Figure 8). The depleted activities of LDH were increased by co-administration of GAR and SACE to the lisinopril-treated animals (Figure 8) by 27.27% and 36.36% respectively. In the same vein, GAR plus SACE administration noticeably ($P < 0.05$) modulate the activity of this enzyme by 163.64% increase following treatment with lisinopril (Figure 8).

3.5. Histopathology of the hepatic cells

Figure 9 illustrates the different histopathologic changes that were observed in the liver of animals that were given various

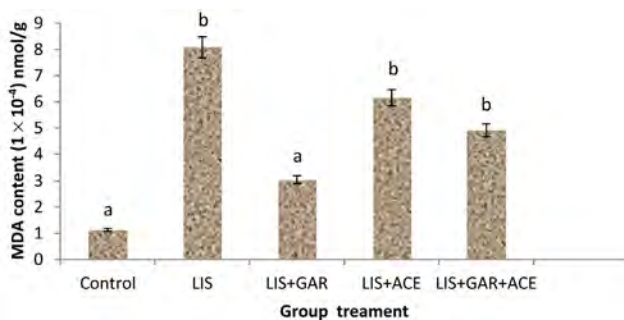


Figure 7. Effect of GAR and SACE on lisinopril-induced toxicity on MDA content of the liver cells. Results are expressed as mean \pm SEM; $n = 7$; Bars with different superscript letters are significant ($P < 0.05$) different; LIS: Lisinopril.

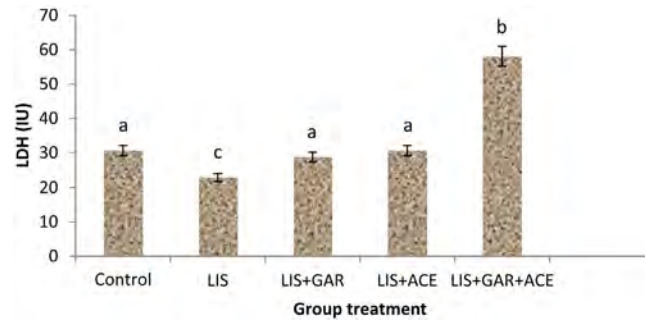


Figure 8. Effect of GAR and SACE on LDH level of lisinopril-induced hepatotoxicity rats. Results are expressed as mean \pm SEM; $n = 7$; Bars with different superscript letters are significant ($P < 0.05$) different; LIS: Lisinopril.

treatments in this study. The hepatic cells were arranged regularly and showed no visible lesions (Figure 9a). Administration of lisinopril showed fewer hepatocytes with large, dark, single nucleus (Figure 9b). Co-treatments with GAR and GAR plus SACE were able to reverse these histopathologic changes induced by lisinopril (Figure 9c–e). As such, showed no visible lesions whereas, co-administration with SACE was unable to entirely protect the histopathologic changes induced by lisinopril.

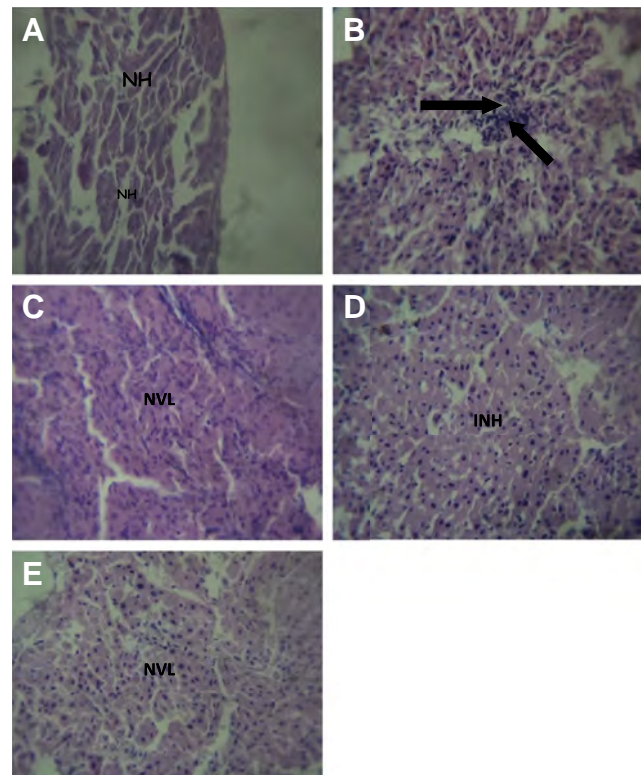


Figure 9. Representative photomicrographs of liver from lisinopril, lisinopril plus GAR, lisinopril plus SACE and lisinopril plus GAR plus SACE-treated animals. (Magnification: 400 \times).

A: Control rat showing normal hepatic morphology; B: Rat treated with lisinopril showing fewer hepatocytes with large, dark, single nucleus as indicated by arrows; C: Rat treated with lisinopril plus GAR; D: Rat treated with lisinopril plus SACE showing locally extensive foci of moderate thinning of hepatic cords [cord atrophy], INH with very large, dark, single nucleus; E: Rat treated with lisinopril plus GAR plus SACE; NH: Normal hepatocytes; NVL: No visible lesions; INH: Increase in numbers of hepatocytes.

4. Discussion

Lisinopril is prescribed as ACE inhibitor to decrease blood pressure by the renin-angiotensin-aldosterone system, but suspected to induce a number of biochemical disorders in animals and humans^[16,19,21,24]. The lisinopril-treated rats showed a decrease in the total protein content of their hepatic supernatant (data not shown). Co-administration of lisinopril with GAR and SACE did not significantly improve the protein content. This in part shows that the decrease in protein content in rats treated with lisinopril may not be due to oxidative stress, but through the direct inhibitory effect of lisinopril on protein synthesis^[34].

The rats administered with lisinopril had a significant ($P < 0.05$) increase in the plasma activities of AST, ALT and ALP compared with their corresponding control groups. The increased level of hepatic enzymes may indicate degenerative changes and hypofunction of the liver^[35,36]. In addition, a rise in plasma level of hepatic enzymes is an indication of liver damage especially when hepatic cells have undergone necrosis^[37,38]. These enzymes are localized in periportal hepatocytes, reflecting their role in oxidative phosphorylation and gluconeogenesis and their plasma activities presumably increase as a result of cellular membrane damage and leakage^[39]. They may also escape from parenchyma cells into the blood stream where their presence can be detected in the plasma. Thus, elevated levels of AST, ALT and ALP as observed in blood circulation were indicative that anti-hypertensive drug could mediate hepatic injury. This observation is consistent with the previous study, where patients that were administered with lisinopril had elevation in serum aminotransferases and was linked to a case of acute liver injury^[15,16,24]. Conversely, co-treatment with GAR, SACE and GAR plus ACE caused a significant decrease in the plasma ALT, AST and ALP suggesting that the drugs were able to protect the liver from oxidative damage.

The animals treated with lisinopril in this study exhibited decreased activities of antioxidant enzymes-SOD and catalase, and also decreased levels of GSH in the liver. This decrease in the antioxidant defense molecules led to a concomitant increase in the level of MDA, a maker of hepatic lipid peroxidation. The inactivation of the antioxidant enzymes may be caused by excess ROS generated in the system^[35]. SOD generally dismutates the superoxide anion radicals into H_2O_2 , which is readily degraded by catalase and GSH peroxidase using reduced GSH. Reactive oxygen metabolites such as singlet oxygen, hydroxyl radicals, superoxide and H_2O_2 are known to be cytotoxic agents because of their ability to induce lipid peroxidation in tissue and membranes^[40]. In the biological system, the antioxidant enzymes catalase and peroxidases protect against SOD inactivation by H_2O_2 , while the SOD reciprocally protects catalase and peroxidase against inhibition by superoxide anion. Our data show that co-administration of GAR, SACE or GAR plus SACE with lisinopril significantly attenuated the effects of this drug on the antioxidant enzymes and further suggest that lisinopril could cause impairment to hepatocytes through induction of oxidative stress. GSH plays a central role in the detoxification of xenobiotics and maintenance of the redox status of the cells^[36]. A decline in its cellular level has been considered to be indicative of oxidative stress. This observation is in agreement with the results of the present study, where there was a decrease in GSH level in the liver of lisinopril-treated rats. Furthermore, the protective effect of

selenium ACE may be attributed to the presence of selenium (co-factor) which functions at the active site of seleno-enzyme GSH peroxidase. GSH peroxidase not only allows the removal of the toxic radicals but also permits the regeneration of lipid molecules through re-acylation in the cellular membrane^[41]. However, SACE may play an important role in the preventive indication of hepatic cellular injury induced by lisinopril therapy.

Hepatocytes have been considered to be highly vulnerable to lipid peroxidation in the presence of elevated ROS levels, due to the abundance of polyunsaturated fatty acids in their membrane^[35,36]. Increased lipid peroxidation and reduced level of antioxidant capacity of the liver in lisinopril-treated rats indicates an increased free radical generation and could be linked to its effect on the hepatic cells. Increased ROS formation due to lipid peroxidation and compromised antioxidant defense system has been shown to be associated with hepatocellular damage^[35,36]. Co-administration of the antioxidants, GAR, SACE and GAR plus SACE, significantly prevented the increase while treatment with GAR exhibited better and more significant protection on hepatic lipid peroxidation. The high hepatoprotective properties of the GAR might not be unconnected to the presence of sulfur compounds (thiosulfonates), including allicin, as the established active components in the root bulb of the garlic plant. This active substance had been implicated as hepatic cells restorer and/or healer^[42,43]. In addition, garlic has long been used medicinally, most recently for its cardiovascular, anti-neoplastic, and clinical antimicrobial activities^[44,45]. Studies had also shown its significant lipid-lowering effects in the liver and anti-platelet activity^[46,47]. Further study suggested that garlic has no effect on drug metabolism^[48,49].

LDH is an oxido-reductase enzyme that catalyses the inter-conversion of pyruvate and lactate. Cells release LDH into the bloodstream after hepatic damage. The level of cellular ATP during anaerobic conditions could be assessed using LDH activity because it is a fairly stable enzyme^[50]. As observed in the study, administration of lisinopril significantly depleted the activity of liver LDH. Our data speculates that lisinopril would slow down the metabolic pathways responsible for ATP energy production. This finding supports the previous discovery that patients with hepatic dysfunctions showed low levels of ATP^[51,52]. Co-administration of the antioxidants GAR, SACE and GAR plus SACE significantly prevented the decrease in LDH, while treatment of lisinopril with GAR plus SACE showed a better therapeutic cure. This may be attributed to the additive and/or synergistic two-fold performance of the antioxidants-GAR and SACE. More so, high level of ATP production in the liver by selenium ACE corroborated the finding of Schnell *et al.*^[53] which reported that selenium pre-treatment decreased the *in vivo* covalent binding of acetaminophen metabolites to hepatic protein. This caused increase in the activity of gamma-glutamylcysteine synthetase which might account for the increased GSH availability in selenium-treated animals. Therefore, increase in the activities of GSH S-transferase and glucose-6-phosphate dehydrogenase will eventually cause high ATP generation via glycolytic pathway^[54–56].

Adverse histopathologic changes showing fewer hepatocytes with large, dark, single nucleus were observed following lisinopril administration to the experimental rats. Co-treatments with GAR and GAR plus SACE were able to reverse these histopathologic changes induced by lisinopril. But, co-administration with SACE was unable to entirely protect the histopathologic changes.

Taken together, the present study reveals that administration of therapeutic dose of lisinopril to male rats induced oxidative stress by decreasing the antioxidant system. The lipid peroxidation was increased with concomitant liver dysfunctions. The mechanism is not unlinked to the lowering of cellular ATP content and damage to the hepatic epithelial cells. GAR, SACE and GAR plus SACE exhibited similarities in their capability to alleviate the toxic responses of lisinopril, which suggests that the adverse effects of lisinopril on the liver are at least in part due to impairment of the antioxidant defense system, depleted cellular ATP and further enhancement of lipid peroxidation. The inability of these antioxidants to fully protect the liver against lisinopril-induced toxicity suggests that the anti-hypertensive drug could mediate hepatic damage through other mechanisms apart from oxidative stress and oxidative phosphorylation. In view of the importance of this drug in clinical practice, the relevance of our study to humans merits further investigation on other mechanisms (especially molecular mechanisms) by which lisinopril induces hepatic damage.

Conflict of interest statement

The authors report no conflict of interest.

References

- [1] Michel T, Hoffman BB. Angiotensin converting enzyme inhibitors. Treatment of myocardial ischemia and hypertension. In: Brunton LL, Chabner BA, Knollman BC, editors. *Goodman and Gilman's the pharmacological basis of therapeutics*. 12th ed. New York: McGraw-Hill; 2011, p. 745-88.
- [2] Hilal-Dandan R. Renin and angiotensin. In: Brunton LL, Chabner BA, Knollman BC, editors. *Goodman and Gilman's the pharmacological basis of therapeutics*. 12th ed. New York: McGraw-Hill; 2011, p. 721-44.
- [3] De Marzio DH, Navarro VJ. Angiotensin-converting enzyme inhibitors. Hepatotoxicity of cardiovascular and antidiabetic drugs. In: Kaplowitz N, DeLeve LD, editors. *Drug-induced liver disease*. 3rd ed. Amsterdam: Academic Press; 2013, p. 523.
- [4] Malacco E, Santonastaso M, Vari NA, Gargiulo A, Spagnuolo V, Bertocchi F, et al. Comparison of valsartan 160 mg with lisinopril 20 mg, given as monotherapy or in combination with a diuretic, for the treatment of hypertension: the blood pressure reduction and tolerability of valsartan in comparison with lisinopril (PREVAIL) study. *Clin Ther* 2014; **26**: 855-65.
- [5] Powers BJ, Coeytaux RR, Dolor RJ, Hasselblad V, Patel UD, Yancy WS Jr, et al. Updated report on comparative effectiveness of ACE inhibitors, ARBs, and direct renin inhibitors for patients with essential hypertension: much more data, little new information. *J Gen Intern Med* 2012; **27**: 716-29.
- [6] Li EC, Heran BS, Wright JM. Angiotensin converting enzyme (ACE) inhibitors versus angiotensin receptor blockers for primary hypertension. *Cochrane Database Syst Rev* 2014; <http://dx.doi.org/10.1002/14651858.CD009096.pub2>.
- [7] Musini VM, Nazer M, Bassett K, Wright JM. Blood pressure-lowering efficacy of monotherapy with thiazide diuretics for primary hypertension. *Cochrane Database Syst Rev* 2014; <http://dx.doi.org/10.1002/14651858.CD003824.pub2>.
- [8] Chaturvedi S, Lipszyc DH, Licht C, Craig JC, Parekh R. Pharmacological interventions for hypertension in children. *Cochrane Database Syst Rev* 2014; <http://dx.doi.org/10.1002/14651858.CD008117.pub2>.
- [9] Blood pressure in Acute Stroke Collaboration (BASC). Interventions for deliberately altering blood pressure in acute stroke. *Cochrane Database Syst Rev* 2014; <http://dx.doi.org/10.1002/14651858.CD000039>.
- [10] Xue H, Lu Z, Tang WL, Pang LW, Wang GM, Wong GW, et al. First-line drugs inhibiting the renin angiotensin system versus other first-line antihypertensive drug classes for hypertension. *Cochrane Database Syst Rev* 2015; <http://dx.doi.org/10.1002/14651858.CD008170.pub2>.
- [11] Sharma P, Blackburn RC, Parke CL, McCullough K, Marks A, Black C. Angiotensin-converting enzyme inhibitors and angiotensin receptor blockers for adults with early (stage 1 to 3) non-diabetic chronic kidney disease. *Cochrane Database Syst Rev* 2011; <http://dx.doi.org/10.1002/14651858.CD007751.pub2>.
- [12] *Drugs for hypertension. Treat Guidel Med Lett* 2009; **7**: 1-10.
- [13] Dodiya H, Kale V, Goswami S, Sundar R, Jain M. Evaluation of adverse effects of lisinopril and rosuvastatin on hematological and biochemical analytes in wistar rats. *Toxicol Int* 2013; **20**(2): 170-6.
- [14] Chalasani N, Fontana RJ, Bonkovsky HL, Watkins PB, Davern T, Serrano J, et al. Causes, clinical features, and outcomes from a prospective study of drug-induced liver injury in the United States. *Gastroenterology* 2008; **135**: 1924-34.
- [15] Lynch AI, Boerwinkle E, Davis BR, Ford CE, Eckfeldt JH, Leidecker-Foster C, et al. Antihypertensive pharmacogenetic effect of fibrinogen-beta variant -455G>A on cardiovascular disease, end-stage renal disease, and mortality: the GenHAT study. *Pharmacogenet Genomics* 2009; <http://dx.doi.org/10.1097/FPC.0b013e32832a8e81>.
- [16] Reuben A, Koch DG, Lee WM, Acute Liver Failure Study Group. Drug-induced acute liver failure: results of a U.S. multicenter, prospective study. *Hepatology* 2010; **52**: 2065-76.
- [17] Doydiya H, Jain M, Goswami SS. Renal toxicity of lisinopril and rosuvastatin, alone and in combination in wistar rat. *Int J Toxicol* 2011; **30**: 518-27.
- [18] Hartleb M, Biernat L, Kochel A. Drug-induced liver damage—a three-year study of patients from one gastroenterological department. *Med Sci Monit* 2002; **8**: CR292-6.
- [19] Zalawadiya SK, Sethi S, Loe S, Kumar S, Tchokonte R, Shi D, et al. Unique case of presumed lisinopril-induced hepatotoxicity. *Am J Health Syst Pharm* 2010; **67**: 1354-6.
- [20] Brandi L. 1-alpha (OH) D3 one-alpha-hydroxy-cholecalciferol—an active vitamin D analog. Clinical studies on prophylaxis and treatment of secondary hyperparathyroidism in uremic patients on chronic dialysis. *Dan Med Bull* 2008; **55**: 186-210.
- [21] Bruggisser M, Terraciano L, Rätz Bravo A, Haschke M. [Liver damage in a patient treated with a vitamin K antagonist, a statin and an ACE inhibitor]. *Praxis (Bern 1994)* 2010; **99**: 1259-65. German.
- [22] Gupta R, Guptha S, Sharma KK, Gupta A, Deedwania P. Regional variations in cardiovascular risk factors in India: India heart watch. *World J Cardiol* 2012; **4**: 112-20.
- [23] Koh KK, Han SH, Oh PC, Shin EK, Quon MJ. Combination therapy for treatment or prevention of atherosclerosis: focus on the lipid-RAAS interaction. *Atherosclerosis* 2010; **209**: 307-13.
- [24] Björnsson ES, Bergmann OM, Björnsson HK, Kvaran RB, Olafsson S. Incidence, presentation and outcomes in patients with drug-induced liver injury in the general population of Iceland. *Gastroenterology* 2013; **144**: 1419-25.
- [25] Okeahialam BN, Amadi K, Ameh AS. Effect of lisinopril, an angiotensin converting enzyme (ACE) inhibitor on spermatogenesis in rats. *Arch Androl* 2006; **52**: 209-13.
- [26] U.S. Department of Health and Human Services. Public health service policy on humane care and use of laboratory animals. Washington, DC: US Department of Health and Human Services; 1996. [Online] Available from: <http://grants.nih.gov/grants/olaw/references/phspolicylabanimals.pdf> [Accessed on 20th February, 2015]
- [27] Clairborne A. Catalase activity. In: Greewald AR, editor. *Handbook of methods for oxygen radical research*. Boca Raton: CRC Press; 1985, p. 237-42.
- [28] Misra HP, Fridovich I. The role of superoxide anion in the auto-oxidation of epinephrine and a simple assay of superoxide dismutase. *J Biol Chem* 1972; **247**(10): 3170-5.
- [29] Lowry OH, Rosenbrough NJ, Farr AL, Randall RJ. Protein measurement with folin phenol reagent. *J Biol Chem* 1951; **193**: 265-75.
- [30] Jollow DJ, Mitchell JR, Zampaglione N, Gillette JR. Bromobenzene induced liver necrosis: protective role of glutathione and evidence for 3,4 bromobenzene oxide as the hepatotoxic metabolite. *Pharmacology* 1974; **11**: 151-69.

- [31] Ohkawa H, Ohishi N, Yagi K. Assay for lipid peroxides in animal tissues by thiobarbituric acid reaction. *Anal Biochem* 1979; **95**: 351-8.
- [32] Weisshaar HD, Prasad MC, Parker RS. Estimation of lactate dehydrogenase in serum/plasma. *Med Welt* 1975; **26**: 387-91.
- [33] Zar JH. *Biostatistical analysis*. Englewood Cliffs: Prentice-Hall; 1984, p. 620.
- [34] Akintunde JK, Ajiboye JA, Siemuri EO, Oyelowo SB, Sunday OJ, Abam EO, et al. Effect of anti-erectile dysfunction drug on some key tissues in healthy male rats. *Am J Drug Disc Dev* 2013; **3**: 32-46.
- [35] Farombi EO, Akintunde JK, Nsute N, Adedara IA, Arojjoye O. Municipal landfill leachate induces hepatotoxicity and oxidative stress in rats. *Toxicol Ind Health* 2012; **28**: 532-41.
- [36] Akintunde J, Oboh G. Depletion of cellular adenosine triphosphate and hepatocellular damage in rat after subchronic exposure to leachate from anthropogenic recycling site. *Hum Exp Toxicol* 2015; <http://dx.doi.org/10.1177/0960327115569809>.
- [37] Ong MM, Latchoumycandane C, Boelsterli UA. Troglitazone-induced hepatic necrosis in an animal model of silent genetic mitochondrial abnormalities. *Toxicol Sci* 2007; **97**: 205-13.
- [38] Ignazio G, Leonilde B, Catia VD, Helen HW, David QW, Piero P. Biochemical mechanisms in drug-induced liver injury: certainties and doubts. *World J Gastroenterol* 2009; **15**: 4865-76.
- [39] Deore SV, Wagh SB. Heavy metal induced histopathological alterations in liver of *Channa gachua* (Ham). *J Exp Sci* 2012; **3**: 35-8.
- [40] Farombi EO, Ugwuezunmba MC, Ezenwadu TT, Oyeyemi MO, Ekor M. Tetracycline-induced reproductive toxicity in male rats: effects of vitamin C and N-acetyl cysteine. *Exp Toxicol Pathol* 2008; **60**: 77-85.
- [41] Ozardali I, Bitiren M, Karakilçik AZ, Zerim M, Aksoy N, Musa D. Effects of selenium on histopathological and enzymatic changes in experimental liver injury of rats. *Exp Toxicol Pathol* 2004; **56**(1-2): 59-64.
- [42] Vimal V, Devaki T. Hepatoprotective effect of allicin on tissue defense system in galactosamine/endotoxin challenged rats. *J Ethnopharmacol* 2004; **90**: 151-4.
- [43] Bat-Chen W, Golan T, Peri L, Ludmer Z, Schwartz B. Allicin purified from fresh garlic cloves induces apoptosis in colon cancer cells via Nrf2. *Nutr Cancer* 2010; **62**: 947-57.
- [44] Asadi-Samania M, Kafash-Farkhadb N, Azimic N, Fasihid A, Alinia-Ahandanib E, Rafeian-Kopaei M. Medicinal plants with hepatoprotective activity in Iranian folk medicine. *Asian Pac J Trop Biomed* 2015; **5**: 146-57.
- [45] Tattelman E. Health effects of garlic. *Am Fam Physician* 2005; **72**: 103-6.
- [46] Zeng T, Guo FF, Zhang CL, Song FY, Zhao XL, Xie KQ. A meta-analysis of randomized, double-blind, placebo-controlled trials for the effects of garlic on serum lipid profiles. *J Sci Food Agric* 2012; **92**: 1892-902.
- [47] Bhandari SR, Yoon MK, Kwart JH. Contents of phytochemical constituents and antioxidant activity of 19 garlic *Allium sativum* L. parental lines and cultivars. *Hortic Environ Biotechnol* 2014; **55**: 138-47.
- [48] Qidwai W, Ashfaq T. Role of garlic usage in cardiovascular disease prevention: an evidence-based approach. *Evid Based Complement Altern Med* 2013; <http://dx.doi.org/10.1155/2013/125649>.
- [49] Khoo YS, Aziz Z. Garlic supplementation and serum cholesterol: a meta-analysis. *J Clin Pharm Ther* 2009; **34**: 133-45.
- [50] Akintunde JK, Oboh G, Akindahunsi AA. Inhibition of key markers linked with spermatogenesis and cellular ATP by subchronic exposure to leachate in a rat model. *Arch Environ Contam Toxicol* 2015; **68**: 159-68.
- [51] Kim JA, Wei Y, Sowers JR. Role of mitochondrial dysfunction in insulin resistance. *Circ Res* 2008; **102**: 401-14.
- [52] Begriche K, Massart J, Robin MA, Bonnet F, Fromenty B. Mitochondrial adaptations and dysfunctions in nonalcoholic fatty liver disease. *Hepatology* 2013; **58**: 1497-507.
- [53] Schnell RC, Park KS, Davies MH, Merrick BA, Weir SW. Protective effects of selenium on acetaminophen-induced hepatotoxicity in the rat. *Toxicol Appl Pharmacol* 1988; **95**(1): 1-11.
- [54] Bélanger M, Allaman I, Magistretti PJ. Brain energy metabolism: focus on astrocyte-neuron metabolic cooperation. *Cell Metab* 2011; **14**: 724-38.
- [55] van Zwieten R, Verhoeven AJ, Roos D. Inborn defects in the antioxidant systems of human red blood cells. *Free Radic Biol Med* 2014; **67**: 377-86.
- [56] Kulshrestha A, Jarouliya U, Prasad GBKS, Flora SJS, Bisen PS. Arsenic-induced abnormalities in glucose metabolism: biochemical basis and potential therapeutic and nutritional interventions. *World J Transl Med* 2014; **3**: 96-111.